

M. Boyd Gillespie · Rohan R. Walvekar
Barry M. Schaitkin · David W. Eisele
Editors

Gland-Preserving Salivary Surgery

A Problem-Based
Approach

EXTRAS ONLINE

 Springer

Gland-Preserving Salivary Surgery

M. Boyd Gillespie • Rohan R. Walvekar
Barry M. Schaitkin • David W. Eisele
Editors

Gland-Preserving Salivary Surgery

A Problem-Based Approach

 Springer

Editors

M. Boyd Gillespie, M.D., M.Sc.
Otolaryngology-Head and Neck Surgery
University of Tennessee Health
Science Center
Memphis, TN
USA

Barry M. Schaitkin, M.D.
School of Medicine
University of Pittsburgh
Pittsburgh, PA
USA

Rohan R. Walvekar, M.D.
Otolaryngology Head and Neck Surgery
Louisiana State University
New Orleans, LA
USA

David W. Eisele, M.D., F.A.C.S.
Otolaryngology-Head and Neck Surgery
Johns Hopkins University School of
Medicine
Baltimore, MD
USA

Additional material to this book can be downloaded from
<https://link.springer.com/book/10.1007/978-3-319-58335-8>

ISBN 978-3-319-58333-4 ISBN 978-3-319-58335-8 (eBook)
<https://doi.org/10.1007/978-3-319-58335-8>

Library of Congress Control Number: 2017962015

© Springer International Publishing AG 2018

This work is subject to copyright. All rights are reserved by the Publisher, whether the whole or part of the material is concerned, specifically the rights of translation, reprinting, reuse of illustrations, recitation, broadcasting, reproduction on microfilms or in any other physical way, and transmission or information storage and retrieval, electronic adaptation, computer software, or by similar or dissimilar methodology now known or hereafter developed.

The use of general descriptive names, registered names, trademarks, service marks, etc. in this publication does not imply, even in the absence of a specific statement, that such names are exempt from the relevant protective laws and regulations and therefore free for general use.

The publisher, the authors and the editors are safe to assume that the advice and information in this book are believed to be true and accurate at the date of publication. Neither the publisher nor the authors or the editors give a warranty, express or implied, with respect to the material contained herein or for any errors or omissions that may have been made. The publisher remains neutral with regard to jurisdictional claims in published maps and institutional affiliations.

Printed on acid-free paper

This Springer imprint is published by the registered company Springer International Publishing AG part of Springer Nature
The registered company address is: Gewerbestrasse 11, 6330 Cham, Switzerland

Foreword I

The idea of gland-preserving minimally invasive treatment of salivary gland pathologies increasingly grew in importance at the end of the 1980s. A number of working parties concerned themselves with this topic. This work culminated in the establishment of diagnostic and interventional salivary gland endoscopy, and it is not possible today to imagine the spectrum of treatment options for diseases of the salivary glands without it. There has also been a stronger focus on gland-preserving procedures for benign parotid tumors.

Boyd Gillespie's working party in the United States has been following these ideas consistently for two decades and has made considerable international contributions to their further development.

This book gives a complete overview of all the modern methods for the diagnostic investigation and treatment of salivary gland disease as given by highly experienced clinicians and should be read by everybody with an interest in this subject.

I personally would like to express my gratitude for the fruitful scientific cooperation and the friendly relationship!

Erlangen, December 2017

Heinrich Iro
Professor and Clinic Director
Department of Otorhinolaryngology—Head and Neck Surgery
Universitätsklinikum Erlangen, Erlangen, Germany
Universität Erlangen-Nürnberg
Erlangen, Germany

Foreword II

It is a great honor to have been asked to write a foreword for this book, *Gland-Preserving Salivary Surgery*, published by my esteemed colleagues and friends.

When we started promoting sialendoscopy and developing sialendoscopes in 1995, we had two concerns for the patients: having a minimally invasive technique, reason for the development of specific dilators, scope sheaths, baskets, and balloons; and having this technique popularized to avoid salivary gland resections.

Teaching was our priority, and while organizing the first multidisciplinary meeting on salivary gland diseases in Geneva, we organized the first course on sialendoscopy, inviting all the salivary pioneers, as well as specialists of all fields related to salivary glands pathologies, benign and malignant.

Slowly, the interest grew, and the European Sialendoscopy Training Center (ESTC) group expanded. Many colleagues became successful leaders in their own countries.

I met David Eisele in 2002 during the sialendoscopy course in Geneva and followed his prestigious career. We stayed in contact and he came back several times to Geneva to teach in our center. I am grateful for his long-lasting friendship. I met Barry Schaitkin and Ricardo Carrau in 2004 in Pittsburgh during an alumni gathering, and they visited our center several times, also as teachers and friends. Rohan Walvekar was presented to me in Pittsburgh as well, and I was always admirative of his dedication to sialendoscopy. Boyd Gillespie honored us with his visit in 2012, and he has been also scientifically very active, and promoting sialendoscopy.

The editors, Dr. Boyd Gillespie, Dr. Barry Schaitkin, Dr. Rohan Walvekar, and Dr. David Eisele, were pioneers bringing this technique to North America. Thanks to their dedication, passion, scientific work, and visibility, a rapid expansion in the United States became possible, with nowadays more than 300 active centers all over the country.

The initial patients were treated for salivary stones, but sialendoscopy allowed us to treat other stenosing pathologies affecting salivary ducts, such as juvenile recurrent parotitis, radio-iodine strictures, Ig IGG4 disease, or Sjögren's syndrome. The International Multidisciplinary Salivary Gland Society (MSGs) founded in 2005 gained therefore interest also for medical specialties including pediatrics, immunology, endocrinology, and others. We

are convinced that the future of this field relies on multicentric and multidisciplinary collaboration, and we are extremely happy that this can occur in a very friendly atmosphere within the growing family of sialendoscopists.

I am very admiring towards the important scientific contribution of my sialendoscopy friends around the world, and I am grateful that the editors of this book contributed also to the book I was privileged to edit in 2015 with 154 colleagues, *Sialendoscopy: The hands-on book*, and that my mentor and friend Professor Eugene Myers kindly foreworded.

Gland-Preserving Salivary Surgery is an extremely complete and well-written book. I have no doubt that with its clear illustrations, tables, and beautiful pictures it will answer all questions one could have. It is certainly a “must-have” book for all physicians interested in salivary glands.

Congratulations!

F. Marchal
University of Geneva
Geneva, Switzerland

Preface

Gland-preservation surgery began with surgical innovators in Europe who not unlike van Leeuwenhoek desired to better understand a disorder through direct inspection. In this case, the disorder was obstructive salivary disease which causes repeated episodes of painful glandular swelling and reduced quality of life. Pioneers of diagnostic sialendoscopy such as Konigsberger, Gundlach, and Katz in the early 1990s engaged in the struggle to visualize the minute anatomy of the salivary duct in order to diagnose the cause of salivary obstruction. Their work was augmented by technical improvements in the late 1990s by Marchal, Zenk, and Iro who partnered with leading biomedical engineers to develop miniature yet hardy scopes capable of relieving obstruction with therapeutic sialendoscopy. Their work definitively demonstrated that therapeutic sialendoscopy relieved symptoms, preserved glandular function, and avoided the morbidity of gland extirpation. As a result, they gave birth to the science and philosophy of gland-preservation surgery as first-line therapy for obstructive salivary disorders.

The innovators spread the philosophy of gland preservation through worldwide lectures and courses, generously sharing their experience and knowledge with those who sought to learn. In the mid-2000s, surgeons from around the world flocked to Dr. Marchal's European Sialendoscopy Training Center in Geneva and Dr. Iro and Zenk's courses in Erlangen eager to learn this technically demanding yet rewarding surgical concept. As a result, the knowledge and practice of sialendoscopy spread to the continent of North America where early adopters began their own courses until most states and major municipalities have at least one sialendoscopist. As current leaders in sialendoscopy by volume, North American surgeons continue to push the field forward in interesting and unexpected ways.

The editors owe a debt of gratitude to their European teachers, colleagues, and friends. The editors also recognize Karl Storz and Cook Medical for promoting innovation, education, and research in the field of sialendoscopy despite the relatively limited prevalence of the disorder. Lastly, we thank our patients who entrust us with their care and continue to provide the motivation to try to do things a little better than before.

Memphis, TN, USA
New Orleans, LA, USA
Pittsburgh, PA, USA
Baltimore, MD, USA
June 2017

M. Boyd Gillespie
Rohan R. Walvekar
Barry M. Schaitkin
David W. Eisele

Contents

Part I Patient Evaluation and Diagnosis

- 1 Patient Evaluation and Physical Examination
for Patients with Suspected Salivary Gland Diseases** 3
William Walsh Thomas and Christopher H. Rassekh
- 2 Salivary Gland Imaging** 15
Jolie L. Chang
- 3 Salivary Fine Needle Aspiration Biopsy** 27
William R. Ryan, A. Sean Alemi, and Annemieke van Zante
- 4 Office-Based Sialendoscopy** 39
Andrew Fuson, Nahir Romero, Bernard Mendis,
and Arjun S. Joshi

Part II Management of Obstructive Salivary Disorders

- 5 Parotid Stones** 51
Barry M. Schaitkin and Rohan R. Walvekar
- 6 Submandibular Stones** 57
Rachel Barry, Barry M. Schaitkin, and Rohan R. Walvekar
- 7 Salivary Duct Scar** 69
M. Boyd Gillespie
- 8 Radioiodine Sialadenitis** 87
Andrew T. Day and David W. Eisele
- 9 Salivary Duct Trauma** 93
Trevor Hackman

Part III Management of Non-obstructive Salivary Disorders

- 10 Acute and Chronic Salivary Infection.** 109
Oscar Trujillo and Rahmatullah W. Rahmati
- 11 Inflammatory Conditions of the Salivary Glands:
Sjögren's Disease, IgG4-Related Disease, and Sarcoidosis** 119
M. Allison Ogden

12 Pediatric Salivary Disorders	127
Christopher G. Larsen, Carrie L. Francis, and Chelsea S. Hamill	
13 Sialadenosis	137
Andrew B. Davis and Henry T. Hoffman	
Part IV Management of Benign Salivary Masses	
14 Gland-Preserving Surgery for Benign Neoplasms	147
Robert L. Witt and Christopher Rassekh	
15 Non-neoplastic Salivary Masses	159
Mark F. Marzouk and Susannah Orzell	
Part V Management of Salivary Medical Conditions	
16 Xerostomia	175
Mihir K. Bhayani and Stephen Y. Lai	
17 Sialorrhea	185
Kirk Withrow and Thomas Chung	
18 Frey Syndrome	193
Benjamin C. Tweel and Ricardo Carrau	
19 Facial Pain Syndromes	203
Charley Coffey and Ryan Orosco	
Part VI Bringing it All Together: Expert Opinions	
20 Sialendoscopy Case	221
Arjun S. Joshi	
21 Pearls, Perils, and Learning Curve of Salivary Endoscopy ...	233
David M. Cognetti and Joseph M. Curry	
22 Endoscopic Equipment: Nuances and Technical Points	245
Jack Kolenda	
23 Future Directions for Gland-Preserving Surgery	251
M. Boyd Gillespie	
Index	259

Contributors

A. Sean Alemi, M.D. Division of Head and Neck Oncologic, Endocrine and Salivary Surgery, Department of Otolaryngology—Head and Neck Surgery, University of California-San Francisco, San Francisco, CA, USA

Rachel Barry, M.D. Department of Otolaryngology—Head and Neck Surgery, Louisiana State University Health Sciences Center, New Orleans, LA, USA

Mihir K. Bhayani, M.D. Division of Otolaryngology, NorthShore University HealthSystem/Pritzker School of Medicine University of Chicago, Evanston, IL, USA

Ricardo Carrau, M.D. Department of Otolaryngology—Head and Neck Surgery, Wexner Medical Center at The Ohio State University, Columbus, OH, USA

Jolie L. Chang, M.D. Department of Otolaryngology—Head and Neck Surgery, University of California, San Francisco, San Francisco, CA, USA

Thomas Chung, M.D. Department of Otolaryngology—Head and Neck Surgery, University of Alabama—Birmingham, Birmingham, AL, USA

Charley Coffey, M.D., F.A.C.S. Division of Head and Neck Surgery, Department of Surgery, University of California San Diego Moores Cancer Center, VA San Diego Healthcare, San Diego, CA, USA

David M. Coggnetti, M.D. Department of Otolaryngology—Head and Neck Surgery, Sydney Kimmel Cancer Center, Thomas Jefferson University, Philadelphia, PA, USA

Joseph M. Curry, M.D. Department of Otolaryngology—Head and Neck Surgery, Sydney Kimmel Cancer Center, Thomas Jefferson University, Philadelphia, PA, USA

Andrew B. Davis, M.D. Otolaryngology Department, University of Iowa Hospitals and Clinics, Iowa City, IA, USA

Andrew T. Day, M.D. Department of Otolaryngology—Head and Neck Surgery, Johns Hopkins University School of Medicine, Baltimore, MD, USA

David W. Eisele, M.D., F.A.C.S. Department of Otolaryngology—Head and Neck Surgery, Johns Hopkins University School of Medicine, Baltimore, MD, USA

Carrie L. Francis, M.D. Department of Otolaryngology—Head and Neck Surgery, University of Kansas Medical Center, Kansas City, KS, USA

Division of Pediatric Otolaryngology, Children’s Mercy Hospitals and Clinics, Kansas City, MO, USA

Andrew Fuson, M.D. Division of Otolaryngology—Head and Neck Surgery, Department of Surgery, George Washington University, Washington, DC, USA

M. Boyd Gillespie, M.D., M.Sc. Department of Otolaryngology—Head and Neck Surgery, University of Tennessee Health Science Center, Memphis, TN, USA

Trevor Hackman, M.D., F.A.C.S. Department of Otolaryngology—Head and Neck Surgery, University of North Carolina, Chapel Hill, NC, USA

Chelsea S. Hamill, M.D. Department of Otolaryngology—Head and Neck Surgery, University of Kansas Medical Center, Kansas City, KS, USA

Henry T. Hoffman, M.D. Otolaryngology Department, University of Iowa Hospitals and Clinics, Iowa City, IA, USA

Arjun S. Joshi, M.D. Division of Otolaryngology—Head and Neck Surgery, Department of Surgery, George Washington University, Washington, DC, USA

Jack Kolenda, M.D. Department of Otolaryngology, Oakville Trafalgar Hospital, Oakville, ON, Canada

Stephen Y. Lai, M.D., Ph.D. Department of Head and Neck Surgery, University of Texas MD Anderson Cancer Center, Houston, TX, USA

Department of Molecular and Cellular Oncology, University of Texas MD Anderson Cancer Center, Houston, TX, USA

Christopher G. Larsen, M.D. Department of Otolaryngology—Head and Neck Surgery, University of Kansas Medical Center, Kansas City, KS, USA

Mark F. Marzouk, M.D., F.A.C.S. Department of Otolaryngology and Communication Sciences, SUNY Upstate Medical University, Syracuse, NY, USA

Bernard Mendis, B.S. Division of Otolaryngology—Head and Neck Surgery, Department of Surgery, George Washington University, Washington, DC, USA

M. Allison Ogden, M.D. Department of Otolaryngology—Head and Neck Surgery, Washington University School of Medicine, St. Louis, MO, USA

Ryan Orosco, M.D. Division of Head and Neck Surgery, Department of Surgery, University of California San Diego, La Jolla, CA, USA

Susannah Orzell, M.D., M.P.H. Department of Otolaryngology and Communication Sciences, SUNY Upstate Medical University, Syracuse, NY, USA

Rahmatullah W. Rahmati, M.D., M.P.H. Department of Otolaryngology—Head and Neck Surgery, Columbia University Medical Center, New York, NY, USA

Christopher H. Rassekh, M.D. Otorhinolaryngology—Head and Neck Surgery, Penn Medicine Sialendoscopy Program, University of Pennsylvania, Philadelphia, PA, USA

Nahir Romero, M.D. Division of Otolaryngology—Head and Neck Surgery, Department of Surgery, George Washington University, Washington, DC, USA

William R. Ryan, M.D., F.A.C.S. Division of Head and Neck Oncologic, Endocrine and Salivary Surgery, Department of Otolaryngology—Head and Neck Surgery, University of California-San Francisco, San Francisco, CA, USA

Barry M. Schaitkin, M.D. Department of Otolaryngology—Head and Neck Surgery, University of Pittsburgh Medical Center, Pittsburgh, PA, USA

William Walsh Thomas, M.D. Otorhinolaryngology—Head and Neck Surgery, Penn Medicine Sialendoscopy Program, University of Pennsylvania, Philadelphia, PA, USA

Oscar Trujillo, M.D. Department of Otolaryngology—Head and Neck Surgery, Columbia University Medical Center, New York, NY, USA

Benjamin C. Tweel, M.D. Department of Otolaryngology—Head and Neck Surgery, Icahn School of Medicine at Mount Sinai, New York, NY, USA

Rohan R. Walvekar, M.D. Department of Otolaryngology—Head and Neck Surgery, Louisiana State University, New Orleans, LA, USA

Kirk Withrow, M.D. Department of Otolaryngology—Head and Neck Surgery, University of Alabama—Birmingham, Birmingham, AL, USA

Robert L. Witt, M.D., F.A.C.S. Thomas Jefferson University, Philadelphia, PA, USA

University of Delaware, Newark, DE, USA

Head and Neck Multidisciplinary Clinic, Helen F. Graham Cancer Center, Christiana Care, Newark, DE, USA

Annemieke van Zante, M.D., Ph.D. Division of Head and Neck Oncologic, Endocrine and Salivary Surgery, Department of Otolaryngology—Head and Neck Surgery, University of California-San Francisco, San Francisco, CA, USA

Part I

Patient Evaluation and Diagnosis

Patient Evaluation and Physical Examination for Patients with Suspected Salivary Gland Diseases

1

William Walsh Thomas
and Christopher H. Rassekh

Key Points

1. A careful history will often point to the likely etiology of a salivary disorder.
2. Systemic conditions and prescribed medications are frequent causes of salivary disorders.
3. Multigland swelling is usually secondary to systemic conditions.
4. Salivary tumor must be considered in all cases of single gland swelling.

Introduction

The evaluation and examination of a patient presenting with salivary pathology begin with a thorough clinical history and subsequent physical examination. The differential diagnosis generated through clinical examination can be further refined and narrowed to a specific diagnosis or set of diagnoses leading to appropriate use of radiologic imaging and laboratory testing guided by signs and symptoms. This framework of clinical care is not unique to salivary pathology, but there are aspects of salivary disease that require

focused and unique questioning and examination. Once the necessary clinic history, examination, and confirmatory testing have been performed, the patient can be definitively treated through a variety of medical, minimally invasive endoscopic, or traditional open excisional approaches to accomplish gland preservation for numerous conditions. Each patient's individual pathology, comorbidities, and wishes will determine the appropriate course of action, but the right path always begins with an accurate diagnosis established in the clinic.

Clinical History: General Salivary Issues

The clinical evaluation of a patient begins in the office where a relationship of trust is formed between the patient and physician. The clinical history is taken in a broad manner that subsequently narrows to a focused history on the salivary gland(s) or condition(s) in question. One mnemonic ("OLD CARTS") to collect pertinent information is found in Table 1.1. This mnemonic allows the patient to elaborate on each symptom, starting with the chief complaint and subsequently each associated symptom in the history of present illness. The clinical interview should begin with open-ended questions. As the clinical scenario is sharpened in the clinician's mind, various close-ended, yes or no, questions can be

W.W. Thomas, M.D. • C.H. Rassekh, M.D. (✉)
Otorhinolaryngology-Head and Neck Surgery,
Penn Medicine Sialendoscopy Program,
University of Pennsylvania, 5th Floor Silverstein,
3400 Spruce Street, Philadelphia, PA 19104, USA
e-mail: william.thomas@uphs.upenn.edu;
christopher.rassekh@uphs.upenn.edu

Table 1.1 OLD CARTS: Clinical evaluation mnemonic for patient assessment from medical and nursing school curricula—Example: “Doctor, my gland(s) is/are swelling”

O (Onset)	Acute onset of swelling, onset following any particular event (e.g., meals or exertion); for acute swelling, recent illness or surgery should be elucidated as a common cause of acute sialadenitis
L (Location)	Multiple gland swelling (bilateral parotid vs. multigland swelling vs. hemifacial gland swelling) vs. single gland or regional swelling—floor of mouth or buccal surface
D (Duration)	Persistent swelling or waxing and waning or progressive enlargement
C (Character)	Firm vs. fluctuant swelling, focal vs. diffuse within 1 gland or region, is the swelling fixed or mobile, small or large relative to mouth or face
A (Aggravating factors) or (Associations)	Worsened pain or purulence with palpation, worsened swelling with eating or speaking
	Associated with worsening taste in the mouth or pain with oral intake
	Associated with other masses in the neck
	Associated with any URI symptoms or recent illnesses
	Associated with voice change or difficulty speaking fluently
R (Relieving factors) or (Radiation)	Associated with fevers, myalgias, or other systemic signs
	Do sialagogues, steroids, antibiotics, or warm compresses improve the swelling or have no effect at all
T (Timing)	Pain radiating to the ears, pain radiating to the jaw, or worsening pain with clenching the jaw
	Temporal association with eating or brushing teeth or using a specific oral product or device, timing related to known risk factors such as radiation therapy (XRT), radioactive iodine(RAI), or periods of dehydration associated with illness or stress
S (Severity)	Severe to the point of airway concerns due to obstruction or swelling
	Severity of pain to the point of dehydration and malnutrition in sialadenitis
	Severity of deformity (cosmetic)

used to differentiate various salivary pathologies. A thorough understanding of the patient’s chief complaint is crucial to the interview of the history of present illness. Properly understanding what the patient would like to be treated will help the clinician to understand the patient’s expectations as well as the patient’s own understanding or realization of their disease process. Once the physician has begun the review of systems, the patient may be prompted to recall key information for the chief complaint; it is important for clinicians to have an established and routine system for evaluating new patients in order that all pertinent information may be documented and taken into full account. Clinicians can miss crucial diagnostic information if they rely on heuristics to label a patient on the basis of a chief complaint without subsequent review of systems. Less-experienced clinicians may lack the broad differential diagnosis known inherently by more experienced clinicians in treating salivary gland disease. This broad differential diagnosis and breadth of knowledge are the reason that attending physicians frequently have at least one further question that the clinicians-in-training failed to elucidate during their initial interview.

Additionally, patients’ past medical, surgical, prior treatment history and social history as well as current medical conditions should be thoroughly queried for comorbidities with salivary health implications. An algorithm for salivary gland disease can begin with the separation of patients into cohorts of multigland pathology or single gland pathology. Typically, systemic illnesses can present with multigland dysfunction and masses, or sialoliths present as single gland pathology. However, clinical scenarios are always more complicated than simple algorithms. For example, a typical multiglandular pathology such as HIV can predispose patients to an increased incidence of single gland pathology such as lymphoma of the parotid [1].

Systemic illnesses that can cause multigland dysfunction are listed in Table 1.2. Additionally, many medications taken chronically can cause dry mouth and a representative sample is listed in Table 1.3.

Clinical history for the “dry mouth” patient.

A clinical history focused on a patient who presents with xerostomia should focus on contributing factors such as found in Tables 1.2 and 1.3 as well previously attempted therapies and treatments.

Xerostomia has significant impact on quality of life. The elderly, most frequently due to their

multiple medications and age-related decrease in salivary production, are at particular risk for xerostomia. Xerostomia can have significant adverse effects on oral health, contributing to dental caries, worsening nutritional status, and oral pain [3, 4]. Additionally, screening for Sjögren’s syndrome should also be performed for at-risk patients presenting with the new complaint of dry mouth and/or dry eyes. Dry mouth followed by sore mouth and then dry eyes were the most common initial complaints in patients presenting with Sjögren’s syndrome [5]. It is important to determine if the patient has current or past history with other medical specialties such as rheumatology or ophthalmology. Questions about the use of ocular lubricants, artificial tears, and difficulty in dry climates can give insight into a patient with dry eyes. Additionally, quantitative testing such as Schirmer’s test and breakup test can be performed to assess for dry eyes [6]. Various questionnaires and scales have been developed and validated for the assessment of xerostomia, and these questionnaires are good

Table 1.2 Systemic illness with manifestations of salivary pathology

Sjögren’s syndrome (primary or secondary)
Graft-versus-host disease
Granulomatous diseases (tuberculosis, sarcoidosis), e.g., Heerfordt’s syndrome
Bone marrow transplantation
Chronic renal dialysis
Malnutrition: bulimia, anorexia, dehydration
Cystic fibrosis
Chemotherapy for systemic malignancy
Human immunodeficiency virus
Diabetes mellitus—particularly with poor control and polyuria

Table 1.3 Medications associated with xerostomia [2]

Anticholinergic antimuscarinic agents	Atropine, belladonna, benztropine, oxybutynin, scopolamine, trihexyphenidyl	Muscle-relaxing agents	Cyclobenzaprine, orphenadrine, tizanidine
Diuretic agents	Chlorothiazide, furosemide, hydrochlorothiazide, triamterene	Opioid analgesics	Codeine, meperidine, methadone, tramadol
Antihypertensive agents	Captopril, clonidine, clonidine/chlorthalidone, enalapril, guanfacine, lisinopril, methyldopa	Nonsteroidal anti-inflammatory agents	Diffunisal, ibuprofen, naproxen, piroxicam
Antidepressants	SSRIs: citalopram, fluoxetine, paroxetine, sertraline, venlafaxine	Others	Anorexiant: diethylpropion (amfepramone), sibutramine
	TCAs: imipramine, amitriptyline, desipramine, nortriptyline		Antiacne agents (retinoids): isotretinoin
	MAOIs: phenelzine		Anticonvulsants: carbamazepine
Antipsychotics	Others: bupropion, nefazodone, mirtazapine		Antidysrhythmics: disopyramide
	Astemizole, brompheniramine, chlorpheniramine, diphenhydramine, loratadine, meclizine		Anti-incontinence agent, anticholinergics: tolterodine
Antihistamines	Astemizole, brompheniramine, chlorpheniramine, diphenhydramine, loratadine, meclizine		Antiparkinsonian agents: carbidopa/levodopa
Anxiolytics	Alprazolam, diazepam, flurazepam, temazepam, triazolam		Ophthalmic formulations: brimonidine (alpha-2 adrenergic agonist)

tools to quantify patients' complaints in the office. Questionnaires on various aspects of history can often be given to patients in the office prior to being seen by the physician as a way to preliminarily gather data and make clinic management more efficient. One such questionnaire by Sreebny and Valdin utilized the question "does your mouth usually feel dry," which was found to have a negative predictive value of 98% and a positive predictive value of 54% as well as a sensitivity of 93% and specificity of 68% for hyposalivation [7].

Common to many patients with xerostomia is the presentation of bilateral parotid swelling. The "swelling" as presented by the patient may be focal or generalized, and Table 1.4 illustrates a differential diagnosis for bilateral parotid swelling. Bilateral salivary gland swelling is usually due to a systemic process, infection, inflammatory, or autoimmune. The diagnosis often depends on the presence or absence of xerostomia. The most common cause of viral infection of the salivary glands is that of the parotid by the mumps virus. The incidence of mumps dropped significantly from up to 300,000 cases annually prior to widespread vaccination in 1967 to 1223 cases reported in 2014. The mumps infection can be unilateral but is usually bilateral and has a viral prodrome before the parotitis ensues [8].

Table 1.4 Differential diagnosis of bilateral parotid swelling

Focal masses	Papillary cystadenoma lymphomatosum (Warthin's tumor)—most common benign
	Acinic cell carcinoma—most common malignant
	Benign lymphoepithelial cysts (BLEC)—pathognomonic for HIV
	Lymphoma
Diffuse swelling/ systemic illness	Sjögren's syndrome
	Sarcoidosis
	Mumps
	Suppurative parotitis
	IgG4 disease formally Mikulicz's disease [6]
	Anorexia or bulimia
	Chronic infectious state—HIV, HCV

Additionally, HIV, Sjögren's syndrome, and RAI therapy are additional causes of bilateral parotid pathology. Sarcoidosis can also mimic Sjögren's syndrome by inducing dry mouth, dry eye, and parotid gland enlargement. Concern should be raised should the patient have fever and possible facial nerve weakness as a rare form of sarcoidosis known as Heerfordt's syndrome may be present [6]. Sarcoidosis usually is painless and may present with focal masses (granulomas) as well as diffuse swelling. Further work evaluation of sarcoidosis should include other organ systems that may be affected, particularly the pulmonary system.

For all patients with swelling that seems associated with inflammatory disease, details of prior episodes of acute sialadenitis should be obtained. Patients who have had severe infections or abscesses are likely to have scarring in the area of the gland which will make management of their condition more difficult. The clinician should be aware of this increased risk and should accordingly counsel the patient that gland preservation may be more difficult in such situations. In addition, patients with systemic illnesses, particularly those that compromise their immune system (such as diabetics, post-organ transplantation, and patient receiving chemotherapy), may be less suited to conservative gland-preserving approaches because open gland removal may be simpler, faster, and more effective. Additionally, failed conservative gland-preserving approaches may put these patients with potential preexisting comorbidities at risk of other significant complications.

Furthermore for single gland "swelling," a general knowledge of the epidemiology of salivary tumors benign and malignant is important to know. The parotid gland is the most common salivary gland to have a mass lesion. Approximately 70% of salivary tumors arise from the parotid, but it is the least likely salivary gland for any given mass lesion to be malignant. Only, approximately, 15% of parotid masses are malignant. Submandibular gland tumors are approximately 10% of salivary tumors, and approximately 35% are malignant. Conversely, minor salivary gland masses make up the remaining

20% of salivary masses, but the percentage of malignancy is significantly higher, 50–70%. Additionally, pain as a presenting symptom for salivary masses is an ominous sign as it is more frequently associated with malignancy than benign tumors; however, only 10% of patients with salivary tumors report pain as a significant symptom [9]. Pain is much more frequently reported with infectious or obstructive salivary disease. Benign salivary masses are slow growing and usually painless; rapid increase in size of a long-standing salivary gland mass should raise concern for malignant change, cystic degeneration, or superinfection. Table 1.5 represents possible social determinants, prior medical treatments, and occupational hazards, which can increase the risk of salivary malignancy.

Table 1.5 Exposure, lifestyle, or prior treatment and salivary malignancy

Alcohol	No conclusive literature on alcohol consumption and salivary gland malignancy or tumors
Cigarette smoking	Not associated with malignant salivary neoplasm Strongly associated with Warthin’s tumor [10]
Occupational silica	2.5-fold elevated risk of salivary cancer [11]
Nitrosamine exposure	Elevated risk of salivary cancer [12]
Radiation exposure	4.5-fold elevated risk salivary malignancy with an 11-year latency period 39-fold higher incidence of salivary gland malignancy in survivors of childhood cancer with radiation to the head and neck [13] 2.6-fold elevated risk of benign salivary tumors with a 21.5-year latency
Radioactive iodine therapy	Dose-dependent complaint of dry mouth in 16% of a cohort and decreased salivary production following I-131 treatment at 5 years [14] Elevated risk of secondary primary salivary malignancy following radioactive iodine therapy for well-differentiated thyroid carcinoma—11-fold higher in study cohort than standard cohort [15]

Submandibular/Sublingual-Specific History

A clinical history for a patient presenting with pain or a mass in the submandibular region will include the general otolaryngologic examination, but special attention will focus on sialolithiasis. Eighty percent of salivary stones arise from the submandibular gland with the remaining 20% from the parotid gland. Rarely, sialolithiasis may occur in the sublingual gland or minor salivary glands. The asymmetric distribution of sialoliths is attributed to the submandibular gland’s more alkaline saliva, higher content of calcium and phosphorous, and higher mucous content. Sialolithiasis is more common in chronic sialadenitis, and sialoliths are only weakly associated with the systemic diseases gout and hyperparathyroidism, primary and secondary [16, 17]. Stone size, orientation of long axis, and shape have been found important in the feasibility of endoscopic removal alone [18]. Additionally, the risk factors, which are common to chronic sialadenitis, are also common to sialolithiasis, and so the two are often seen together: dehydration, xerostomia, and salivary duct stricture. These conditions cause salivary stasis, which subsequently leads to a nidus of inorganic calcium salts and then sialolith formation.

One condition, which occurs much more frequently in the sublingual gland, is the formation of a ranula. The pathophysiology of a ranula involves the rupture and scarring of the main duct of Rivinus or an accessory duct with subsequent formation of a mucocele in the anterior floor of the mouth. If the mucocele subsequently expands posterior and inferior to the mylohyoid muscle, the patient may present with a neck mass in the level IB; this is known as a plunging ranula [19]. The ranula has a characteristic cystic appearance and location in the anterior floor of the mouth; clinically the patient will present with pain and particularly with a plunging ranula; the pain can be exacerbated with neck rotation. Mucoceles may also arise from minor salivary glands, and in the floor of mouth, they may be difficult to distinguish clinically from sublingual gland ranula (Fig. 1.1). Additionally, cross-sectional imaging

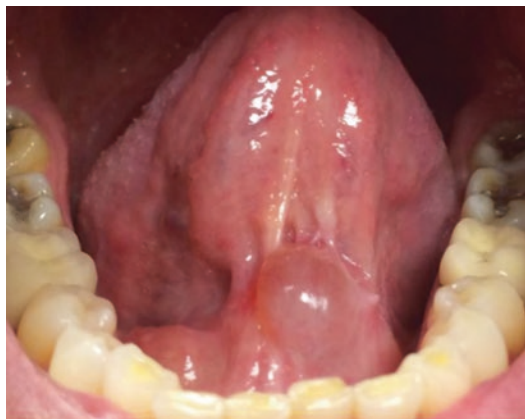

Fig. 1.1 Patient with a left submandibular duct mucocele due to duct obstruction after gland excision. Pale cystic appearance is common to ranula and mucocele lesions. Minor salivary gland mucocele and sublingual gland ranula would produce a similar appearance

of a patient presenting with a cystic neck mass, clinically suspicious for plunging ranula, but without the anterior floor of mouth lesion, may reveal a submandibular mucocele. In these cases, the submandibular gland should be addressed as opposed to the sublingual gland [20]. In addition to plunging ranula, the differential diagnosis for a cystic neck mass is very large; the clinician should ensure that malignancy in the form of regional metastatic neck metastasis is not present in all cases prior to assuming a benign etiology. Other benign cystic neck masses include but are not limited to lymphatic malformations, brachial cleft cysts, thyroglossal duct cysts, and many others. A unique clinical pearl for the diagnosis of lymphatic malformations is the enlargement or history of enlargement with bending over, straining, or Valsalva, as central venous pressure is raised, lymph is not able to drain from the malformation, and it may thus enlarge. Many patients with lymphatic malformations and lymphangiomas present without symptoms with incidental imaging findings, but others are quite bothered by the lesions either due to pain, deformity, or the concern about a more dangerous diagnosis. In such cases, removal of the lesion may be required such as in the case shown in Fig. 1.1. Because tumors of the sublingual gland and minor salivary gland origin are often malignant, it is imper-

ative to evaluate thoroughly, and imaging will come into play for further work-up of ranula and cystic salivary gland and neck masses. In some parts of the world, it has been postulated that ranula is associated with HIV infection, so this should be considered. In a series of 113 patients with oral mucocele from South Africa, 38 patients had plunging ranulas, and 36 of these patients were HIV positive. The conclusion from these series suggests that HIV-positive patients are more likely to present with ranula or plunging ranula than the general population, but no mechanism of causality has been elucidated [21].

Parotid-Specific History

The clinical history for a patient with a mass of the parotid gland should begin with the standard otolaryngologic interview as described above, but a few additional parotid-specific clinical pearls should be obtained. The superficial portion of the parotid gland contains on average 10–20 lymph nodes, and the clinical history should help to determine the risk of a primary parotid tumor as opposed to a metastatic lymph node within the parotid. Specifically, sun exposure, the use of sun protection, and prior occupation should be discussed in order to obtain a general risk for skin cancer and subsequent parotid metastasis. Patients should be asked about any history of prior cutaneous malignancy of the face, neck, or scalp. Additionally, a thorough evaluation of hearing and ear function should be obtained to assess for a primary otologic malignancy presenting with parotid metastasis. Simultaneously, assessment for otitis media or hearing loss should be performed as deep lobe parotid masses can obstruct the Eustachian tube in the prestyloid compartment of the parapharyngeal space. Any neurological symptom should be investigated thoroughly to rule out cranial neuropathy.

As discussed above about bilateral parotid masses, HIV is a common cause of bilateral lymphoepithelial cysts (BLEC). There are multiple additional effects of HIV upon the salivary glands. Patients can present with painless diffuse bilateral glandular swelling, most commonly of

the parotid. Cystic lesions within the parotid gland should undergo fine needle aspiration to confirm a diagnosis of BLEC as opposed to Kaposi’s sarcoma or lymphoma. BLEC typically presents early following contraction of HIV. Additionally, patients presenting with cystic mass lesions of the parotid should undergo serologic testing for HIV if the diagnosis of BLEC is confirmed, as its presence is pathognomonic. If a patient with BLEC develops constitutional symptoms such as fever, night sweats, or weight loss with concurrent rapid enlargement of one or both parotids, assessment for malignant lymphomatous degeneration should take place urgently. Additional clinical evidence of malignancy is characterized by induration, mass fixation, pain, and facial nerve palsy [22]. In general, parotidectomy is not required for BLEC; needle aspiration with sclerotherapy can help patient with symptoms of pressure and disfigurement and avoid gland removal [22].

In addition to the focused history of present illness as described, a thorough otolaryngologic review of systems is important due to the frequent association of other conditions and findings with salivary gland pathology.

A sample of an otolaryngologic review of systems by subsite is provided in Table 1.6 for reference.

Physical Examination

We recommend a complete head and neck examination and general examination for all new patients who come to our clinic, including salivary gland disorders. It is remarkable how often related and unrelated abnormalities are found by doing so. A physical exam template for items to be evaluated is shown in Table 1.7.

General Salivary Pathology

A comprehensive head and neck evaluation is typically performed on all patients with salivary function issues or masses of the salivary glands. Specific issues to be addressed are presented in

Table 1.6 Otolaryngologic review of systems by anatomic subsite

Ears	Yes or no: hearing loss, tinnitus, drainage, otalgia, trauma, prior surgery
Eyes	Yes or no: vision loss, double vision, pain with eye movement
Nose	Yes or no: congestion, epistaxis, rhinorrhea, sneezing, prior surgery
Oral cavity	Yes or no: nonhealing ulcers, dysarthria, bleeding, pain, loose teeth, untreated caries
Oropharynx	Yes or no: referred otalgia, trismus, throat pain, dysphagia, odynophagia
Nasopharynx	Yes or no: nasal obstruction, unilateral serous otitis media, neck mass, cranial nerve palsy
Larynx	Yes or no: muffled voice, hoarseness, sore throat, respiratory distress, noisy breathing
Neck	Yes or no: lumps, tenderness, scars, swelling, prior surgery
Salivary	Yes or no: swelling, foul tastes in the mouth, xerostomia, pain, prior surgery
Skin	Yes or no: history of skin cancer, prior Mohs surgery, other surgery
Constitutional	Yes or no: unintentional weight loss, fever, chills, night sweats, pauses during sleep

each of the following subcategories. In an evaluation of a patient presenting with xerostomia, several characteristic signs of the physical exam may be noted in Table 1.8. Additionally, see Fig. 1.2 as an example of a patient xerostomia and parotid dysfunction secondary to radiation treatment. The face and neck skin should also be specifically evaluated for the presence of scars as patients may forget to report prior surgery given neurologic comorbidities or fixation on current issue or having undergone the surgery by different specialist such as endocrine or oral surgery as opposed to otolaryngology or vice versa.

Submandibular Gland-Specific Examination

The submandibular gland is located in the submandibular space, which is inferior to the mylohyoid muscle (superficial lobe, deep lobe is posterior and superior to mylohyoid), lateral to

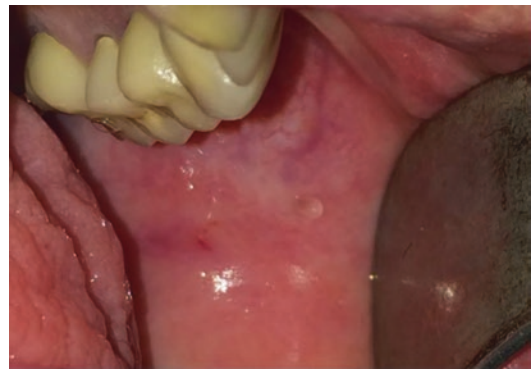Table 1.7 General head and neck exam for salivary gland disease

Vitals	HR, BP, RR, O ₂ saturation—check at each clinical encounter
Head	Signs of trauma, deformity
Face	Scars, deformity, or asymmetry
Eyes	Irritation, vision, asymmetry
Ears	Tympanic membranes, canals, pinna, hearing
Nose	Nose: septum, evidence of granulomatous disease
Oral cavity	Oral cavity: dentition, gingiva, lips, buccal mucosa, tongue, floor of the mouth, palate (look for normal architecture, edema, erythema, leukoplakia, ulceration, desquamation, exudates, scars, nodularity to palpation), TORI, fissured tongue, moisture (see also Table 1.9)
Oropharynx	Oropharynx: tonsils, asymmetry, other lesions
Nasopharynx	Nasopharynx: abnormal lesions, masses, or drainage
Hypopharynx	Hypopharynx: lesions, edema, pooling
Larynx	Larynx: vocal cord mobility, lesions, voice quality
Neck	Neck: suppleness, presence of any edema, masses or tenderness, or scars
Skin	Skin: warm, dry, and normal color
Salivary glands	Salivary glands: enlargement of one or more glands, focal masses, size, number and characteristics, tenderness, duct orifice (should have free flow of saliva $\times 4$; scant saliva or abnormal saliva should be noted)
Lymphatic	Lymphatic: any lymphadenopathy
Endocrine	Endocrine: thyroid nodules, tenderness, scars
Neuro	Neuro: CN II–XII, focal deficits
Ext/Vasc	Ext/Vasc: evidence of systemic illnesses
Respiratory	Any distress, increased work of breathing

the anterior belly of the digastric muscle, posterior and medial to the body and parasymphysis of the mandible, and deep to the superficial layer of deep cervical fascia. Examination of the gland is performed with bimanual palpation of the floor of the mouth and skin overlying the level IB region of the neck. Additionally, Wharton's duct is palpated, and the quality and quantity of saliva are assessed. The papilla is specifically assessed

Table 1.8 Physical exam characteristics of a dry mouth

Characteristics
Application of a mirror to the tongue or buccal mucosa without the ability to slide—sticking to mucosal surfaces
No pooling of saliva in the floor of the mouth
Frothy saliva if present
Loss of papilla on the dorsal tongue
Polished or glass-like appearance of the palate
Deep fissures of the dorsal tongue
More than two teeth with caries at the junction of the root cementum and enamel crown—cervical caries
Sticking of debris to the mucosa of the palate

**Fig. 1.2** Left parotid papilla in a patient who underwent prior radiation therapy; note the dry-appearing oral mucosa, telangiectasias of the buccal mucosa, and erythema and edema of the papilla itself. Note that there are also fissured tongue and dental caries

for patency and ability to accommodate dilation and possible instrumentation. The regional nerves are assessed for functionality: the lingual nerve, taste and touch sensation to the anterior two-thirds of the tongue; the marginal mandibular and cervical branches of the lower division of the facial nerve, symmetry of the smile; and hypoglossal nerve, motion of the tongue. Additionally, the facial artery may be palpated as it crosses the mandible immediately anterior to the masseter muscle. The functionality of these nerves in conjunction with the mobility and firmness of a submandibular mass can give evidence to a benign or malignant pathology.

Masses of the submandibular gland may be primary tumors of the gland or metastatic lymph nodes to level IB of the neck, which also contains the submandibular gland. Level IB is at significant

risk for metastases from the following aerodigestive subsites: oral cavity, oropharynx, anterior nasal cavity, major and minor salivary gland cancers, and cutaneous malignancy [23].

Physical examination of the submandibular gland for sialolithiasis includes assessment of the papilla and the duct. It is important to note whether a sialolith within Wharton's duct in the floor of mouth is palpable. If so, a more precise localization of the stone is possible. Generally, more distal stones are easier to manage; see Fig. 1.3a for an example of a distal extruding sialolith from the left submandibular duct and Fig. 1.3b for an example of a hematoma from a left submandibular sialolith. Additionally, this assessment in conjunction with the known course of the lingual nerve may indicate how challenging transoral combined approach for excision of

the sialolith if it is anterior or posterior to the crossing of the lingual nerve, respectively. This examination can be made significantly more difficult by the presence of mandibular tori; see Fig. 1.3a, b. These benign, typically bilateral, bony growths on the medial side of the parasymphysal mandible can obstruct access to the bilateral Wharton's ducts.

The presence of mandibular tori or other abnormalities of the mandible including dentition that is sloped toward the floor of mouth (Fig. 1.4b) should be considered before any transoral approach to Wharton's duct or the submandibular gland, as access and space will be limited. Additionally, the anterior floor of the mouth should be assessed for oro-ductal fistula or scarring or other forms of trauma to the duct from stone extrusion or prior manipulation which

Fig. 1.3 (a) Left bilateral mandibular tori that impede transoral access to the bilateral Wharton's ducts. (b) Left submandibular duct with a sialolith and obstructive edema and erythema; bilateral smaller tori also noted but access to the papilla is still feasible

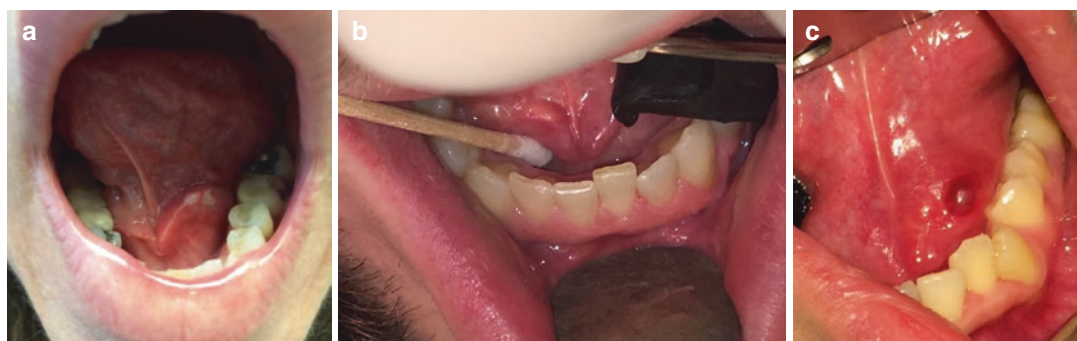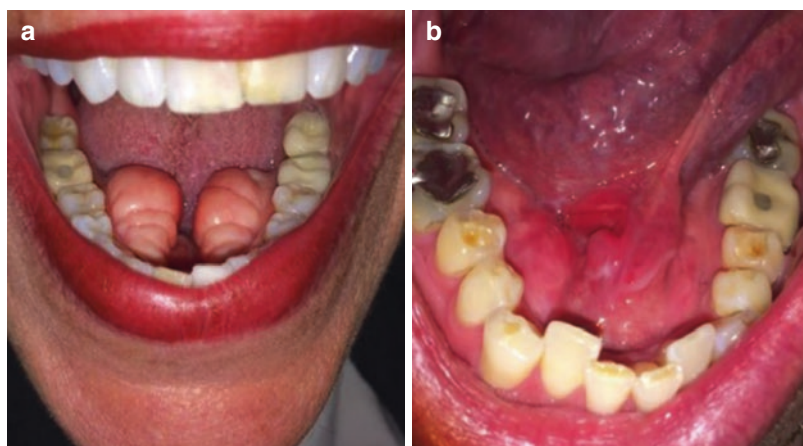


Fig. 1.4 (a–c) Three patients with submandibular papilla or duct findings: *Left*—stone extruding from left submandibular duct deep to the papilla with obstructive findings. *Middle*—sialolith in the right Wharton's duct at the

papilla with tall sloping dentition, which increases the difficulty of transoral removal. *Right*—hematoma and edema of left submandibular duct due to obstructive sialolith

Table 1.9 Potential laboratory evaluations for salivary pathology

Infectious	Rheumatologic [30]	Neoplasm
CBC with differential to assess for severity of infection and immunologic response	Concern for Sjögren’s syndrome—70% positive anti-SSA, 35% positive anti-SSB, 50–75% positive for rheumatoid factor	CBC—assess for white blood cell count for possible lymphoma or leukemia with or without cytopenias
CMP—to assess for electrolyte status prior to interventions or contrasted radiologic studies	Concern for SLE—60% positive for anti-dsDNA, 30–50% positive for anti-histone	LDH—patient with salivary mass and neck lymphadenopathy with a known melanoma or history of melanoma excision; positive parotid lymph nodes for cutaneous melanoma are at least stage 3
Coagulation studies—prior to any surgical intervention	Drug-induced SLE—95% positive for anti-histone	
	Scleroderma—ANA pattern: nucleolar (diffuse) and centromere (CREST), 30% positive for anti-Scl 70	
	ESR and CRP—assess for general level of inflammation of the body	

can be caused by sialolithiasis or its treatment and can sometimes be used for access to the duct but may also cause difficulties for subsequent sialendoscopy [24]. Palpable stones can often be managed simply by a direct approach both in the proximal and distal duct because they help localize the position of the duct incision. Finally, the clinician should be very wary of infectious cases involving the bilateral submandibular spaces. This presentation, known as Ludwig’s angina, can quickly lead to respiratory distress as the edema and inflammation of the bilateral submandibular spaces will push the tongue posteriorly and superiorly and obstruct the oropharyngeal airway [25]. Clinicians should be aware that nodules of the lip or buccal mucosa may be neoplasms and that sialoliths do occasionally present in minor salivary glands as well. Mucocoeles are also quite common (see discussion of ranula above).

Parotid-Specific Examination

Knowledge of the regional anatomy of the parotid gland is important for the clinician to be able to understand the consequences of various mass and inflammatory lesions. The parotid gland has its own fibrous capsule, which is continuous with the superficial layer of the deep cervical fascia. The gland is located in the parotid space which has the following boundaries: superiorly is the zygomatic arch, posteriorly is the external ear

canal, laterally is the parapharyngeal space, and inferiorly is the mandibular ramus. Schematically, the parotid gland is separated into the deep and superficial lobe by a plane containing the retro-mandibular vein and facial nerve. Parotid tissue can be found medially in the parapharyngeal space if the parotid moves through the stylomandibular tunnel. For benign neoplasms, location of the tumor may predict feasibility of gland-sparing surgery. For example, partial superficial parotidectomy may be feasible for tumors isolated to the tail of the parotid, but similar-sized lesions located in proximity to the duct may require total parotidectomy. Lesions in the deep lobe may be managed with preservation of the superficial lobe. Following the general examination of the head and neck, the specific examination of the parotid gland includes palpation of the gland itself, overlying skin, as well as the soft tissues of the neck and bimanual palpation of the buccal space. Additionally, Stensen’s duct should be palpated for masses and the quality and quantity of the saliva from the papilla. If even a small amount of saliva can be seen from the papilla, the duct is likely to be accessible with sialendoscopy. Evaluation of sialolithiasis within Stensen’s duct should focus on the size of sialolith, which is typically smaller than submandibular stones [26], and on the location of the sialolith. If the stone is deep to the masseteric turn, which is a sharp curve, Stensen’s duct forms as it turns into the buccal mucosa; the sialolith may be more difficult to

evaluate and remove [27]. Additionally, patients with obstructive complaints of the parotid should be assessed for masseter hypertrophy as this can cause kinking of Stensen's duct and acute obstruction of the gland [28]. Patients who have undergone radioactive iodine ablation or who have Sjögren's syndrome often have ductal stenosis and mucus plugging in addition to xerostomia. This may be bilateral, but often one gland is most symptomatic, and the parotid glands are more often affected than the submandibular. For Sjögren's syndrome, marked asymmetry should prompt concern about lymphoma of the parotid that may arise in these patients. A full assessment of the facial nerve is also important for consideration of parotid masses as gland preservation will likely be impossible when the nerve is clinically involved, and patients should be counseled that even with facial nerve sacrifice, the prognosis is adversely affected by nerve involvement [29]. A thorough examination of the entire scalp, face, and neck is crucial to identify any potential skin cancers, which may have regional metastasis to the parotid. Patients with pain and/or perceived swelling around the parotid gland may have pathology of surrounding structures such as the mandible or dentition so these should be evaluated if the history and physical examination are not otherwise suggestive of salivary gland pathology.

Laboratory Studies

The full work-up for individuals presenting with salivary complaints or masses will often include laboratory and radiologic testing: see further chapters in this text for a discussion of radiologic imaging. The laboratory testing required for each individual patient is ordered on the basis of many clinical considerations: patient characteristics such as comorbidities, frailty, and extent of disease, as well as category of disease gathered from clinical history and physical exam – infectious, rheumatologic, or malignancy. Table 1.9 provides general guidelines for possible laboratory evaluations in several clinical scenarios. Of note, if clinic history is suspicious for parotid swelling

due to bulimia nervosa, electrolyte abnormalities in the form of hypochloremia and hypokalemia may be found [31].

Conclusion

The examination of a patient with salivary pathology begins with a thorough clinical history, which in most cases should establish a diagnosis. This diagnosis can then be tested with the physical examination and subsequently proven with laboratory and radiologic testing. Given the importance of salivary functioning in daily life, patients with compromised functioning are quick to present for medical treatment, and they will often be able to provide in-depth details of their condition. Conversely, salivary pathology that does not impact function may take months or years to be noticed by the patient and brought to the attention of a medical provider. Most patients have very little understanding of salivary glands, and patient education is a part of the evaluation process for many conditions. The subsequent treatment of the salivary pathology established via clinical history and physical exam is highly varied and in some cases changing rapidly with new techniques. The rapidly evolving domain of gland-preserving salivary gland management, which will be reviewed in subsequent chapters in this text, impacts patients with neoplasms, duct obstruction, and functional impairment due to local or systemic diseases. As new treatments become available, the clinician must update his or her clinical interviewing methods to screen for applicability of the latest techniques in order to provide the best care possible for the patient.

References

1. Michelow P, Dezube BJ, Pantanowitz L. Fine needle aspiration of salivary gland masses in HIV-infected patients. *Diagn Cytopathol.* 2012;40:684–90. doi:[10.1002/dc.21597](https://doi.org/10.1002/dc.21597).
2. Miranda-Rius J, Brunet-Llobet L, Lahor-Soler E, Farre M. Salivary secretory disorders, inducing drugs, and clinical management. *Int J Med Sci.* 2015;12:811–24. doi:[10.7150/ijms.12912](https://doi.org/10.7150/ijms.12912).

3. Anil S, Vellappally S, Hashem M, Preethanath RS, Patil S, Samaranyake LP. Xerostomia in geriatric patients: a burgeoning global concern. *J Invest Clin Dent*. 2016;7:5–12. doi:[10.1111/jicd.12120](https://doi.org/10.1111/jicd.12120).
4. Gerdin EW, Einarson S, Jonsson M, Aronsson K, Johansson I. Impact of dry mouth conditions on oral health-related quality of life in older people. *Gerodontology*. 2005;22:219–26.
5. Al-Hashimi I, Khuder S, Haghighat N, Zipp M. Frequency and predictive value of the clinical manifestations in Sjogren's syndrome. *J Oral Pathol Med*. 2001;30:1–6.
6. Cornec D, Saraux A, Jousse-Joulin S, Pers JO, Boissrame-Gastrin S, Renaudineau Y, Gauvin Y, Roguedas-Contios AM, Genestet S, Chastaing M, Cochener B, Devauchelle-Pensec V. The differential diagnosis of dry eyes, dry mouth, and parotidomegaly: a comprehensive review. *Clin Rev Allergy Immunol*. 2015;49:278–87. doi:[10.1007/s12016-014-8431-1](https://doi.org/10.1007/s12016-014-8431-1).
7. Sreebny LM, Valdini A. Xerostomia. Part I: relationship to other oral symptoms and salivary gland hypofunction. *Oral Surg Oral Med Oral Pathol*. 1988;66:451–8.
8. Mumps Outbreaks 2014 Centers for Disease Control. CDC website. 2016. <http://www.cdc.gov/mumps/outbreaks.html>.
9. Spiro RH. Salivary neoplasms: overview of a 35-year experience with 2,807 patients. *Head Neck Surg*. 1986;8:177–84.
10. Pinkston JA, Cole P. Cigarette smoking and Warthin's tumor. *Am J Epidemiol*. 1996;144:183–7.
11. Zheng W, Shu XO, Ji BT, Gao YT. Diet and other risk factors for cancer of the salivary glands: a population-based case-control study. *Int J Cancer*. 1996;67:194–8. doi:[10.1002/\(SICI\)1097-0215\(19960717\)67:2<194::AID-IJC8>3.0.CO;2-O](https://doi.org/10.1002/(SICI)1097-0215(19960717)67:2<194::AID-IJC8>3.0.CO;2-O).
12. Straif K, Weiland SK, Bungers M, Holthenrich D, Keil U. Exposure to nitrosamines and mortality from salivary gland cancer among rubber workers. *Epidemiology*. 1999;10:786–7.
13. Boukheris H, Stovall M, Gilbert ES, Stratton KL, Smith SA, Weathers R, Hammond S, Mertens AC, Donaldson SS, Armstrong GT, Robison LL, Neglia JP, Inskip PD. Risk of salivary gland cancer after childhood cancer: a report from the childhood cancer survivor study. *Int J Radiat Oncol Biol Phys*. 2013;85:776–83. doi:[10.1016/j.ijrobp.2012.06.006](https://doi.org/10.1016/j.ijrobp.2012.06.006).
14. Jeong SY, Kim HW, Lee SW, Ahn BC, Lee J. Salivary gland function 5 years after radioactive iodine ablation in patients with differentiated thyroid cancer: direct comparison of pre- and postablation scintigraphies and their relation to xerostomia symptoms. *Thyroid*. 2013;23:609–16. doi:[10.1089/thy.2012.0106](https://doi.org/10.1089/thy.2012.0106).
15. Iyer NG, Morris LG, Tuttle RM, Shaha AR, Ganly I. Rising incidence of second cancers in patients with low-risk (T1N0) thyroid cancer who receive radioactive iodine therapy. *Cancer*. 2011;117:4439–46. doi:[10.1002/cncr.26070](https://doi.org/10.1002/cncr.26070).
16. Blatt IM, Mikkelsen WM, Denning RM. Studies in sialolithiasis. II. Uric acid calculus of the parotid gland; report of a case. *Ann Otol Rhinol Laryngol*. 1958;67:1022–32.
17. Stack BC Jr, Norman JG. Sialolithiasis and primary hyperparathyroidism. *ORL J Otorhinolaryngol Relat Spec*. 2008;70:331–4. doi:[10.1159/000149836](https://doi.org/10.1159/000149836).
18. Walvekar RR, Carrau RL, Schaitkin B. Endoscopic sialolith removal: orientation and shape as predictors of success. *Am J Otolaryngol*. 2009;30:153–6. doi:[10.1016/j.amjoto.2008.03.007](https://doi.org/10.1016/j.amjoto.2008.03.007).
19. Harrison JD. Modern management and pathophysiology of ranula: literature review. *Head Neck*. 2010;32:1310–20. doi:[10.1002/hed.21326](https://doi.org/10.1002/hed.21326).
20. Carlson ER. Diagnosis and management of salivary lesions of the neck. *Atlas Oral Maxillofac Surg Clin North Am*. 2015;23:49–61. doi:[10.1016/j.cxom.2014.10.005](https://doi.org/10.1016/j.cxom.2014.10.005).
21. Syebele K, Munzhelele TI. Oral mucocoele/ranula: another human immunodeficiency virus-related salivary gland disease? *Laryngoscope*. 2015;125:1130–6. doi:[10.1002/lary.25058](https://doi.org/10.1002/lary.25058).
22. Ebrahim S, Singh B, Ramklass SS. HIV-associated salivary gland enlargement: a clinical review. *SADJ*. 2014;69:400–3.
23. Werner JA, Dunne AA, Myers JN. Functional anatomy of the lymphatic drainage system of the upper aerodigestive tract and its role in metastasis of squamous cell carcinoma. *Head Neck*. 2003;25:322–32. doi:[10.1002/hed.10257](https://doi.org/10.1002/hed.10257).
24. Kieliszkak CR, Gill A, Faiz M, Joshi AS. Submandibular ductal fistula: an obstacle to sialendoscopy. *JAMA Otolaryngol Head Neck Surg*. 2015;141:373–6. doi:[10.1001/jamaoto.2014.3574](https://doi.org/10.1001/jamaoto.2014.3574).
25. Marra S, Hotaling AJ. Deep neck infections. *Am J Otolaryngol*. 1996;17:287–98.
26. Sigismund PE, Zenk J, Koch M, Schapher M, Rudes M, Iro H. Nearly 3,000 salivary stones: some clinical and epidemiologic aspects. *Laryngoscope*. 2015;125:1879–82. doi:[10.1002/lary.25377](https://doi.org/10.1002/lary.25377).
27. Kiringoda R, Eisele DW, Chang JL. A comparison of parotid imaging characteristics and sialendoscopic findings in obstructive salivary disorders. *Laryngoscope*. 2014;124:2696–701. doi:[10.1002/lary.24787](https://doi.org/10.1002/lary.24787).
28. Reddy R, White DR, Gillespie MB. Obstructive parotitis secondary to an acute masseteric bend. *ORL J Otorhinolaryngol Relat Spec*. 2012;74:12–5. doi:[10.1159/000334246](https://doi.org/10.1159/000334246).
29. Wierzbicka M, Kopec T, Szyfter W, Kereiakes T, Bem G. The presence of facial nerve weakness on diagnosis of a parotid gland malignant process. *Eur Arch Otorhinolaryngol*. 2012;269:1177–82. doi:[10.1007/s00405-011-1882-6](https://doi.org/10.1007/s00405-011-1882-6).
30. Gardner GC, Kadel NJ. Ordering and interpreting rheumatologic laboratory tests. *J Am Acad Orthop Surg*. 2003;11:60–7.
31. Mandel L. Salivary gland disorders. *Med Clin North Am*. 2014;98:1407–49. doi:[10.1016/j.mcna.2014.08.008](https://doi.org/10.1016/j.mcna.2014.08.008).

Jolie L. Chang

Key Points

1. Ultrasonography offers real-time, cost-effective images that can characterize salivary gland tumors, lymphadenopathy, sialolithiasis, and salivary duct obstruction and dilation. Ultrasound can further be used to target lesions for fine-needle aspiration biopsy.
2. Computed tomography is best used to evaluate salivary gland calcifications, bony erosion from tumors, and acute inflammation with concern for abscess formation.
3. Magnetic resonance imaging is the superior imaging modality for evaluating masses and tumors of the salivary glands due to excellent soft-tissue contrast and resolution. MRI can provide information about perineural invasion, tumor margins, extent of involvement in the parapharyngeal space, and lymph node metastasis.
4. Sialography provides detailed visualization of the main salivary duct and its branches within the gland parenchyma. Standard sialography involves cannulation of the major salivary duct papilla and infusion of contrast material. MR sialography is a newer technique that does not require contrast but has poorer spatial resolution.

5. Typical imaging findings for salivary gland lesions, tumors, autoimmune disease, sialolithiasis, and stenosis are discussed.

Imaging Modalities

Conventional Radiography

Stones or calculi in the major salivary ducts can at times be visualized with conventional X-ray imaging. Attention to obtaining oblique lateral or occlusal views is required in order to visualize the region of the salivary ducts away from the bony facial skeleton. Historically, 80% of salivary calculi are radiopaque [1] on X-ray, and visualization depends on calcified content and stone size. CT imaging is more sensitive for detection and localization of small calcifications and has largely replaced conventional X-ray imaging for this purpose [2]. Despite this, routine dental imaging can uncover incidental calculi in the submandibular and parotid spaces. Soft-tissue lesions and tumors in the salivary glands are not adequately visualized with conventional X-ray.

Ultrasonography (US)

US is a real-time and cost-effective approach for initial imaging of many salivary gland disorders. US offers no radiation and provides targeted,

J.L. Chang, M.D.
Department of Otolaryngology—Head and Neck
Surgery, University of California, San Francisco,
2380 Sutter Street, Box 0342, San Francisco,
CA 94115, USA
e-mail: jolie.chang@ucsf.edu

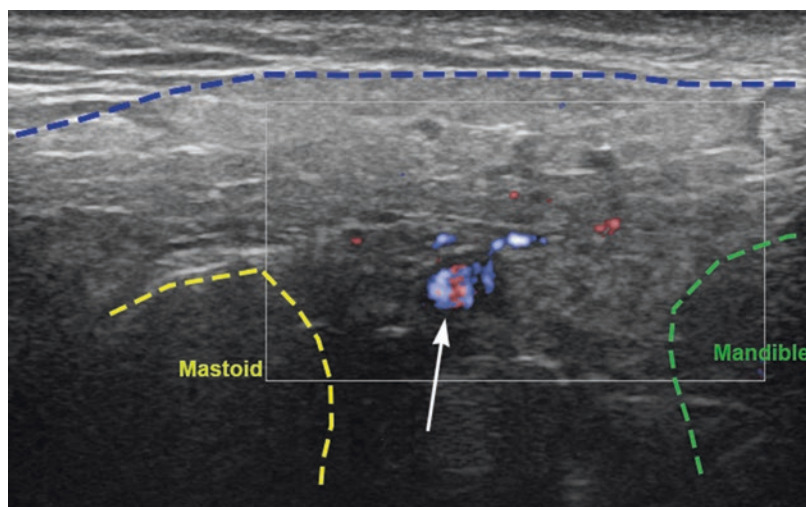


Fig. 2.1 Ultrasound image of the right parotid gland in the transverse plane outlines the superficial surface of the parotid (blue dashed line), the mastoid process (yellow dashed line), and the ramus of the mandible (green dashed line). The parotid gland is hyperechoic compared to sur-

rounding tissue. The demarcation between superficial and deep lobes of the parotid is defined by the depth of the retromandibular vein (white arrow) which is visualized using Doppler

two-dimensional images of the head and neck using high-frequency linear array 7–15 MHz transducers. On exam, normal salivary glands are homogeneous and typically hyperechoic compared to surrounding muscle tissue due to higher fat content within the glands (Fig. 2.1).

Superficial tumors of the major salivary glands are easily imaged with US. The superficial lobe of the parotid is delineated from the deep lobe by the location of the facial nerve and its branches, which cannot be directly visualized on US. However, the facial nerve runs with the retromandibular vein. The retromandibular vein can be imaged and represents a marker for the relative depth and location of the facial nerve [3] (Fig. 2.1). For submandibular glands, most of the parenchyma except for the most superior extent can be evaluated using US. Salivary tumors on US should be assessed for size, shape, borders, and internal vascularity and content. Adjacent lymph nodes within the parotid gland and in the lateral neck can be assessed for size, shape, and signs of necrosis or metastasis. US cannot diagnose or definitively differentiate benign from malignant tumors; however, US can be used to target needle placement for fine-needle aspiration biopsies of salivary gland lesions.

For evaluation of the salivary duct system, the course of Stensen's and Wharton's ducts can be examined on US. The main parotid duct exits the hilum of the gland and courses superficial to the masseter muscle approximately 1 cm inferior to the zygomatic arch before piercing the buccinator muscle and entering the oral cavity opposite the second maxillary molar. An accessory parotid gland can be found in 20% of patients adjacent to the duct and projecting over the masseter [4] and should be examined for lesions. The submandibular duct exits the submandibular gland hilum and travels around the posterior edge of the mylohyoid muscle into the floor of mouth where it courses adjacent to the sublingual glands anteriorly to the papilla which opens in the anterior floor of mouth just lateral to the lingual frenulum. The normal, non-obstructed, salivary duct is not visible on US.

Obstructive disease from sialolithiasis or duct stenosis is suspected in patients who report recurrent periprondial swelling and pain of the gland. Intraductal obstruction from salivary duct stones or stenoses can lead to ductal dilation and allows the duct to be visualized on US (Fig. 2.2a). Calcifications in the ducts appear as hyperechoic smooth lesions with posterior acoustic shadow (Fig. 2.2b). US has the ability to provide precise,

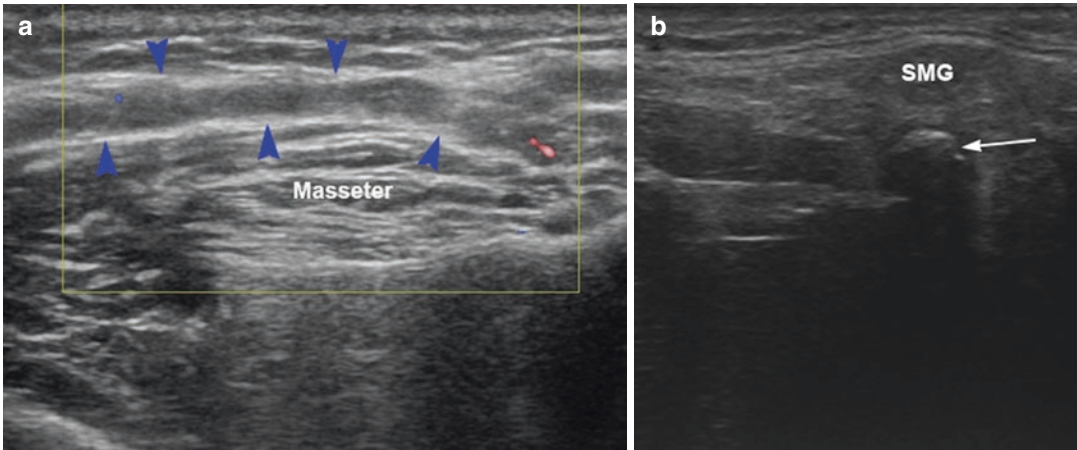


Fig. 2.2 Ultrasound of the left anterior cheek (a) demonstrates a dilated main parotid duct (blue arrowheads) over the masseter muscle due to distal stenosis at the papilla. The lack of Doppler flow within the hypoechoic tubular

structure confirms the structure corresponds to a salivary duct. Ultrasound of the left submandibular gland hilum (b, SMG) reveals a hyperechoic calculus (white arrow) with posterior acoustic shadow

real-time localization of calculi which can be utilized intraoperatively to target surgical interventions. US has high sensitivity (94%) and specificity (100%) for detecting salivary calculi larger than 2 mm; smaller calculi do not routinely exhibit the posterior acoustic shadows [5]. Bimanual sono-palpation with digital palpation of the buccal mucosa for parotid ducts or the floor of mouth mucosa for submandibular ducts can be performed while applying external pressure with the ultrasound transducer and allows for visualization of the distal salivary ducts (Fig. 2.3). When a sialolith is large enough to cause significant duct obstruction, proximal duct dilation can be visualized as a hypoechoic tubular structure along the course of the salivary duct. The absence of color flow with Doppler confirms the identification of a salivary duct instead of a blood vessel (Fig. 2.2a). During the exam, patients with stenosis or obstruction can be given a sialogogue to stimulate saliva generation and promote visualization of a dilated duct.

US disadvantages include dependency on operator experience and technique. Images can be limited by incomplete visualization of the deep parotid lobe due to acoustic shadowing by the mandible. Similarly, pathology in the most anterior section of the floor of mouth can also be challenging to image. Large tumors in the parapharyngeal space may require multi-planar imaging for full assessment.

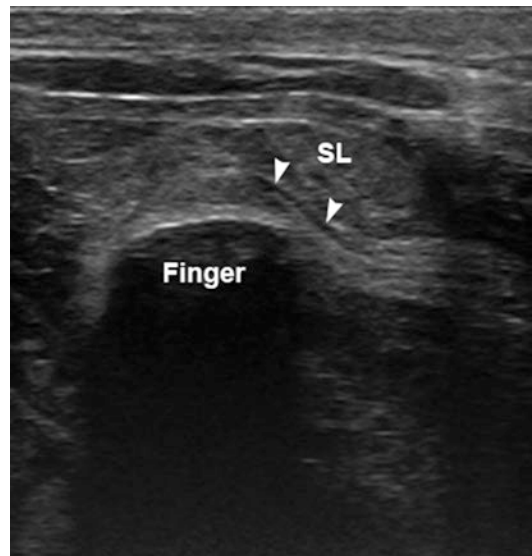


Fig. 2.3 Ultrasound of the left anterior submental space with bimanual sonopalpation with gloved finger in the anterior floor of mouth (finger) compressing the tissue against the US probe. A dilated submandibular duct (arrowheads) can be seen alongside sublingual tissue (SL)

Computed Tomography (CT)

CT is the imaging modality best suited to identify small calcifications in the salivary duct or gland and to evaluate for bony erosion from malignant neoplasms. Due to speed and accessibility, CT images are also best for evaluating acute inflammation

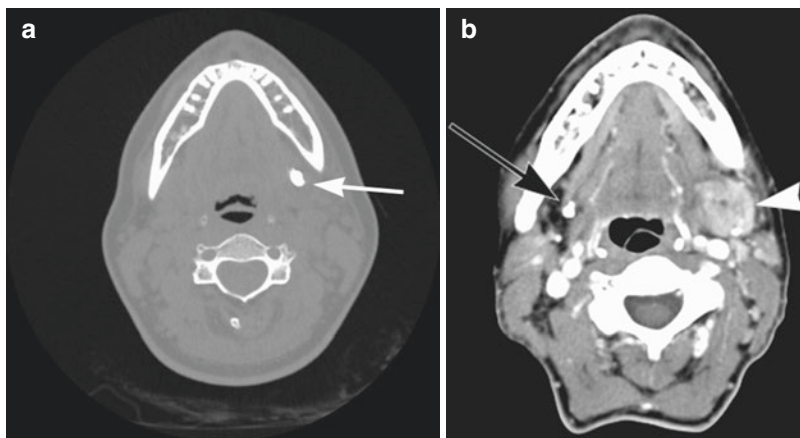


Fig. 2.4 CT scan without contrast (a) with left submandibular calculus at the hilum of the gland (white arrow). A patient with chronic salivary obstruction (b) from a right submandibular duct stone (black arrow) has atrophy of the right submandibular gland and replacement of the space

with dark fatty tissue. The left submandibular gland is visible (white arrowhead), whereas the right gland appears to be absent although the patient has never had surgical removal

and infection of the salivary glands for potential abscess formation. Small calculi are best seen with non-contrast CT (Fig. 2.4a) and when found along the course of the parotid or submandibular ducts can diagnose the source of recurrent gland inflammation. Calcifications can also be found within certain tumors such as pleomorphic adenoma, Warthin's tumor, acinic cell carcinoma, and adenoid cystic carcinoma. Chronic inflammation and obstruction can lead to atrophy and fatty replacement of the gland (Fig. 2.4b). For malignant lesions of the salivary glands, CT images can assess invasion of adjacent bone such as the temporal bone, mandible, hard palate, and skull base. Diffuse punctate microcalcifications within the salivary gland parenchyma typically represent chronic inflammation that can be from Sjogren's syndrome, autoimmune disorders, or tuberculosis. Multiple linear calcifications may represent phleboliths within vascular malformations associated with the masseter or parotid gland.

Disadvantages of CT imaging include poor visualization of the dilated salivary duct and contraindications for contrast in those with impaired renal function and history of allergic reaction to iodine-based contrast. Streak artifacts from dental fillings can obscure pathology. CT involves exposure to ionizing radiation; specifically, the median effective dose for a neck CT

with contrast is 4 mSv (millisieverts) which is the equivalent of 55 conventional chest radiographs. The importance and effects of lifetime radiation exposure are gaining attention and requires further study [6].

Magnetic Resonance Imaging (MRI)

MRI produces excellent soft-tissue contrast and resolution and is the superior imaging modality for evaluating masses and tumors of the salivary glands. Unlike CT, MRI does not involve ionizing radiation. Common MR sequences to evaluate the salivary glands include T1 weighted, T2 weighted, and T1 weighted with gadolinium contrast and fat-saturation images. MRI can also provide information about perineural invasion, tumor margins, extent of involvement in the parapharyngeal space, and lymph node metastasis. MRI offers the best visualization of the facial nerve which can sometimes be seen traversing the fat pad near the stylomastoid foramen. The plane of the nerve within the parotid gland is estimated using the stylomastoid foramen and the retromandibular vein. MR has limited abilities to detect calcifications but is superior for demonstrating tumor margins, perineural tumor spread, and intracranial invasion [7].

MRI disadvantages include high cost and longer scan time required. Patients with certain metallic implants and pacemakers cannot enter the scanner, and those with claustrophobia can have difficulty tolerating the scanner for long periods of time.

Sialography

Historically, sialography has been the main diagnostic method for sialolithiasis and salivary obstruction dating back to 1902 [7]. Sialography provides visualization of the main salivary duct and all its branches within the gland parenchyma. Sialography technique involves cannulation of Stensen's or Wharton's ducts and infusion of contrast material to outline duct anatomy. In digital subtraction sialography, an X-ray image is taken prior to contrast infusion and subtracted from post-contrast images. A sialogogue is then administered to promote the gland to empty and excrete the contrast, and afterward, a post-excretion scan demonstrates contrast clearance or retention. Examination of the ducts for filling

defects, strictures, or overall size can aid in diagnosis of chronic obstructive symptoms [8].

Sialography is contraindicated in acute inflammatory conditions due to the risk for duct injury and exacerbation of infection. A successful sialogram depends on skilled cannulation of the salivary duct papillae and careful infusion of contrast. The duct dilation required for contrast application has potential therapeutic effects. Sialography is currently reserved for evaluation of obstructive and inflammatory conditions as it has limited abilities to image tumors within the glands. Disadvantages of conventional sialography include its invasive nature compared to other imaging modalities and limitations due to the use of static X-ray images. In many institutions sialography has been replaced by ultrasound or multi-planar imaging followed by therapeutic sialendoscopy. However, in certain cases detailed anatomy of the duct system is desired. For example, sialography can provide evaluation of salivary ducts after sialodochoplasty and assessment of sialiectasis and salivary duct stenosis (Fig. 2.5).

MR sialography is a newer MRI protocol to image the salivary ducts using heavily T2-weighted

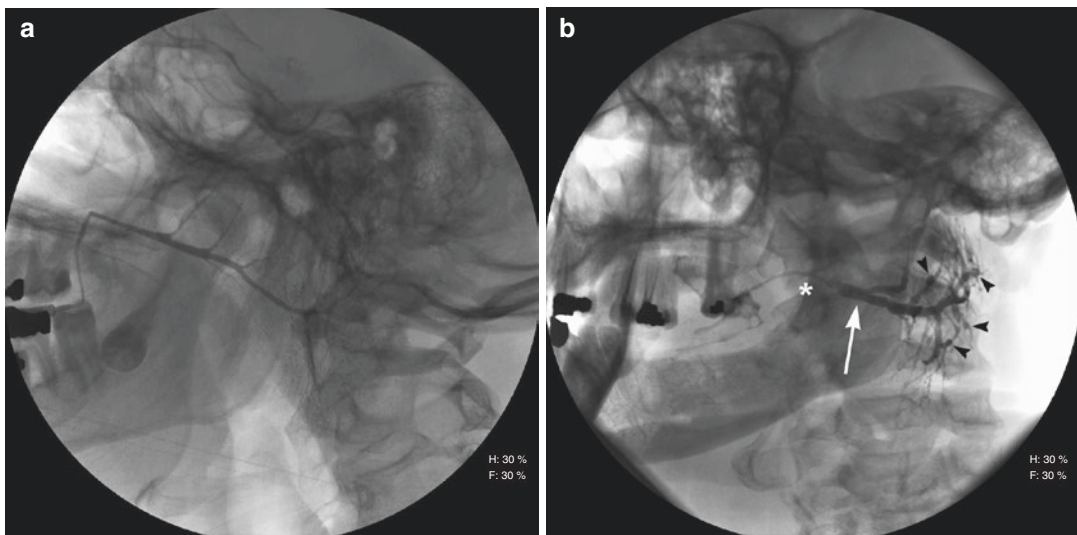


Fig. 2.5 A normal left parotid sialogram has smooth duct contour and visualization of multiple duct branches after contrast injection (a). In comparison, a left distal parotid duct stricture (b) is demonstrated with restricted duct size (*) and proximal duct dilation (white arrow). The intraglandular parotid ducts display sialiectasis as shown by the

irregular beaded appearance (black arrowheads). The findings of irregular main duct contour, dilated proximal ducts, and degeneration in the gland are seen in chronic sialadenitis from parotid duct stenosis. Sialogram figures courtesy of Hoffman HT, Iowa head and neck protocols

imaging protocol that does not require cannulation of the salivary duct and does not expose patients to radiation. MR sialography has been demonstrated to be effective in evaluating calculi and duct stenoses with limitations for calculi smaller than 3 mm without dilated ducts [9]. The abilities of MR sialography to detect duct dilation, calculi, and stenoses are comparable to US and conventional sialography [9]. However, the spatial resolution of secondary and tertiary branches on MR sialography is not as clearly visualized as with conventional sialography. A standard MR sialography protocol has not been established and multiple approaches have been described [10].

Salivary Scintigraphy

Salivary gland scintigraphy is a nuclear medicine study performed to examine salivary gland function in Sjogren's syndrome and after external beam or radioactive iodine radiation therapy. Techniques for salivary scintigraphy were developed to measure salivary gland hypofunction. Patients are given intravenous ^{99m}Tc -pertechnetate, and a gamma camera is used to image the gland and quantify radioactivity (counts/second). Afterward, patients are administered a sialogogue to stimulate salivary excretion, and rate of excretion is measured [11]. Patients with Sjogren's syndrome can demonstrate decreased uptake and decreased excretion of the pertechnetate from the salivary glands. Radiation treatment such as ^{131}I for thyroid ablation can also cause functional salivary gland impairment. Overall, guidelines and consensus on scintigraphy protocols are lacking, making interpretation and comparison between institutions and studies challenging.

Imaging of Specific Salivary Conditions

Salivary Gland Neoplasms

Imaging is used to demonstrate tumor location in the superficial or deep lobe of the parotid and determine extraglandular extension, invasion of surrounding tissues, and nodal metastasis. US

can be used initially to establish location of superficial lesions and obtain US-guided fine-needle aspiration biopsy for diagnosis. If the pathology is non-diagnostic or malignant or more detailed cross-sectional assessment is desired, MRI is typically the next step.

Pleomorphic Adenoma

Pleomorphic adenomas are the most common benign salivary gland tumor. They typically have smooth borders and rounded appearance with lobulations on imaging. On US the pleomorphic adenoma is typically hypoechoic with posterior acoustic enhancement. On MRI lesions display low signal intensity on T1 and intermediate to high signal intensity on T2-weighted images and can enhance with gadolinium (Fig. 2.6). Lesions can be homogeneous or heterogeneous when the larger tumors have internal cystic changes [4]. Signal intensity can vary with areas of internal hemorrhage in the tumor. On CT pleomorphic adenomas appear as smooth, ovoid, enhancing masses, occasionally with internal calcifications. Lesions that widen the stylomandibular space and displace the parapharyngeal fat suggest involvement of the deep parotid lobe.

Warthin Tumor (Papillary Cystadenoma Lymphomatosum)

Warthin tumors can occur bilaterally and are often multifocal in the parotid glands. These tumors are well-defined lesions that most commonly occur in the parotid tail. Lesions can have both cystic and solid components, occasionally with septations. On ultrasound the lesions appear as well-defined masses with multiple anechoic areas. On MRI, Warthin tumors have intermediate signal on T1 and intermediate signal intensity with focal hyperintense areas on T2 images [4]. These lesions can have minimal to no contrast enhancement and appear heterogeneous due to multiple internal components.

Malignant Tumors

Common malignant lesions of the salivary gland include mucoepidermoid carcinoma, adenoid cystic carcinoma, acinic cell carcinoma, carcinoma ex pleomorphic adenoma,

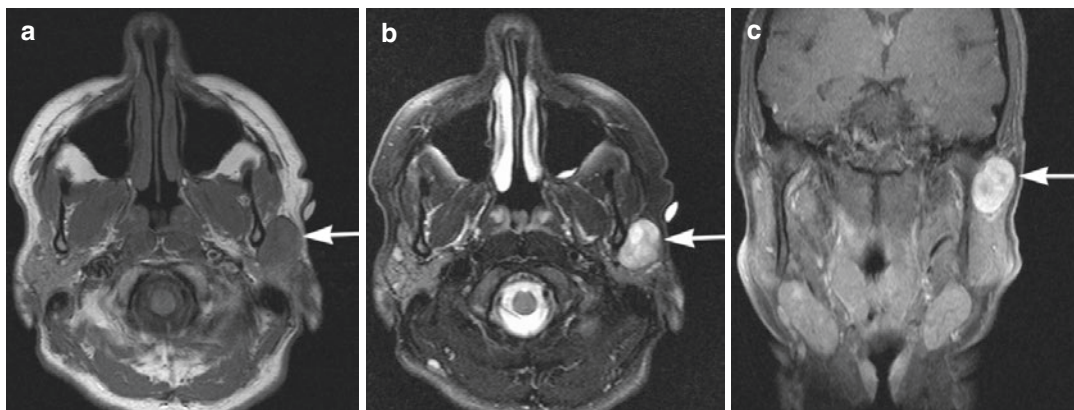


Fig. 2.6 MR images from the same patient with pleomorphic adenoma show a left parotid lesion (*arrows*) with low signal intensity on T1-weighted axial image (a), well-

circumscribed high signal intensity on T2-weighted axial image (b), and heterogeneous enhancement with contrast on T1 coronal image with contrast and fat saturation (c)

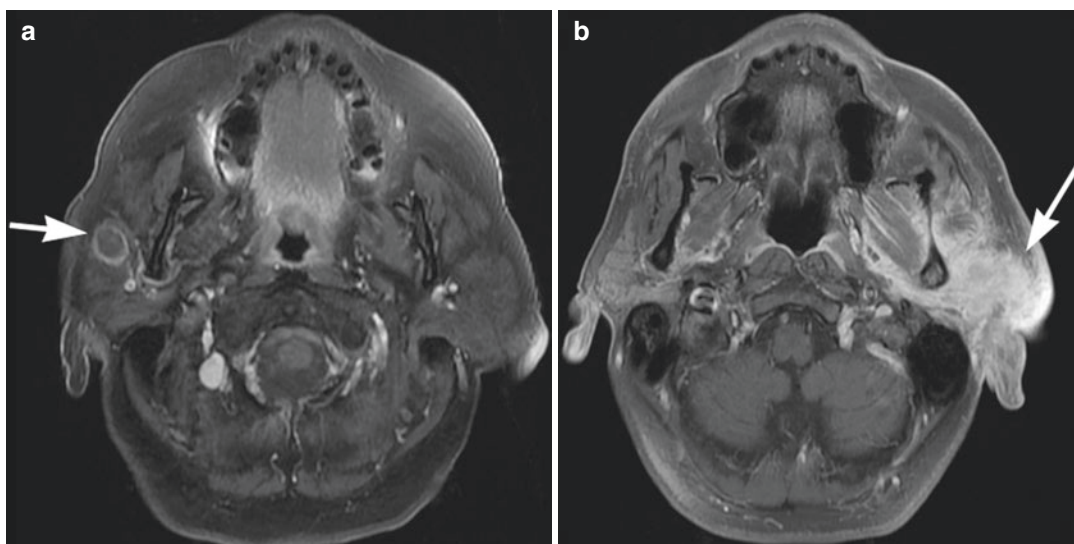


Fig. 2.7 T1-weighted MR images show right intraparotid lesion (a) of low intensity and surrounding contrast enhancement (*arrow*) in a patient with metastatic squamous cell carcinoma. A left parotid adenocarcinoma

(b, *arrow*) has irregular borders and bright contrast enhancement and demonstrates involvement of the superficial and deep parotid lobes

salivary duct carcinoma, metastatic squamous cell carcinoma or melanoma, and non-Hodgkin's lymphoma. Low-grade tumors can be hard to distinguish from benign tumors since both present as well-circumscribed lesions. Features that suggest high-grade or aggressive malignancies include ill-defined masses with invasive features and metastatic lymphadenopathy (Fig. 2.7). On MRI high-grade lesions with more cellularity can be represented with low signal intensity on both T1- and T2-weighted

sequences. Replacement of the fat in the stylomastoid foramen or enhancement of the mastoid segment of the facial nerve suggests perineural invasion. Large deep-lobe tumors can exhibit extension along the auriculotemporal nerve up to the foramen ovale (V3). CT imaging can aid in assessing the extent of skull base and mandible bony invasion. Multifocal disease is suggestive of parotid nodal metastases from the face, scalp, or ear skin, or lymphoma. Metastatic disease and lymphoma can

present in the parotid gland due to the presence of intraglandular parotid lymph nodes that are not found in submandibular or sublingual glands. Further evaluation with PET nuclear medicine studies can be considered in cases with suspected metastases.

Lymphoepithelial Cysts

Lymphoepithelial cysts appear as multiple mixed cystic and solid lesions usually in the parotid gland. Lesions are well-circumscribed, hypodense cysts on CT. On MRI lesions have low signal intensity on T1 and hyperintensity on T2-weighted images. Solid lesions can enhance with contrast or appear heterogeneous. On US lesions can appear as simple cysts or as mixed masses with solid components. Cysts can have thin septations and 40% have mural nodules [4]. Active HIV disease is associated with lymphoepithelial cyst formation and additionally can present with tissue hypertrophy of the palatine tonsils, lingual tonsils, and adenoids.

Salivary Gland Inflammation and Obstruction

Acute Inflammation

Acute sialadenitis is defined by acute swelling and pain over a major salivary gland. Bacterial sialadenitis is typically unilateral and presents with diffuse inflammation of the gland and overlying soft tissues. Viral sialadenitis can commonly involve bilateral parotid glands. Imaging with contrast-enhanced CT or US can be done to evaluate for infectious sequelae such as abscesses. CT imaging will demonstrate an enlarged gland with inflammatory stranding in the overlying soft tissues and strong enhancement with contrast (Fig. 2.8). Abscesses, if present, will appear as rim-enhancing lesions with internal decreased intensity. Abscess size, location, and extent on imaging can help define need for further intervention. On US the infected gland appears hypoechoic and heterogeneous. Focal hypoechoic collections suggest abscess

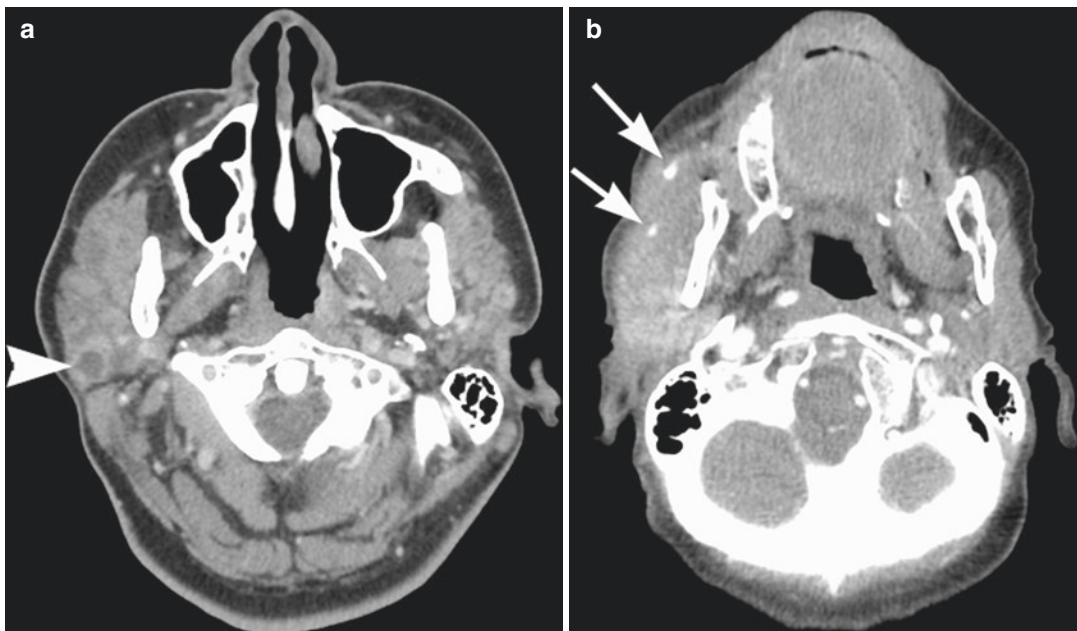


Fig. 2.8 CT scan with right acute parotid sialadenitis (**a**) with enlargement of the gland and a small rim-enhancing hypointense collection indicating an early abscess (*arrowhead*). The left parotid shows heterogeneous fatty replace-

ment consistent with chronic immune-mediated inflammation from Sjogren's syndrome. Right acute parotid inflammation with obstruction from two parotid duct stones (**b**, *arrows*)

formation, and US guidance may be used for aspiration. Evaluation for calculi that may have caused salivary flow obstruction can be done with CT or US; however, acute inflammation and pain may limit a full US exam requiring a repeat study once the acute infection has been managed.

Sialolithiasis

Salivary duct calculi present more commonly in the submandibular gland system (80%) compared to the parotid gland (20%). The submandibular gland produces relatively more viscous saliva with higher concentration of hydroxyapatites and phosphates [1]. Wharton's duct also has a narrower papilla, and the duct location and ascent from the inferiorly positioned gland to the papilla in the anterior floor of mouth are more conducive to saliva retention and stasis. The most common site for Wharton's duct stone formation and impaction, seen in 53% of cases, is in the proximal duct near the hilum of the gland where the duct bends around the posterior border of the mylohyoid, sometimes referred to as the "comma" region of the duct. Other submandibular calculi are located in the mid-portion of the duct and near the papilla in the anterior floor of mouth (37%). Parotid duct calculi are most commonly found in the distal main Stensen's duct compared to the hilum of the gland [12].

Salivary duct calcifications can almost always be visualized with a fine-cut CT scan without contrast. If contrast is used for other purposes, the image should be windowed appropriately to visualize calcified tissue. Images should be carefully reviewed to examine the entire course of the submandibular and parotid ducts. Calculi near the anterior floor of mouth can be missed upon initial review especially in the setting of acute sialadenitis and infection (Fig. 2.9). Alternatively, calcifications within other tissues such as the tonsils can also be confused for salivary stones. US can detect most calculi larger than 2 mm. Smaller calcifications fail to exhibit posterior acoustic shadows. Bimanual sono-palpation helps with visualization of the most distal portions of the parotid and submandibular ducts. MRI and MR

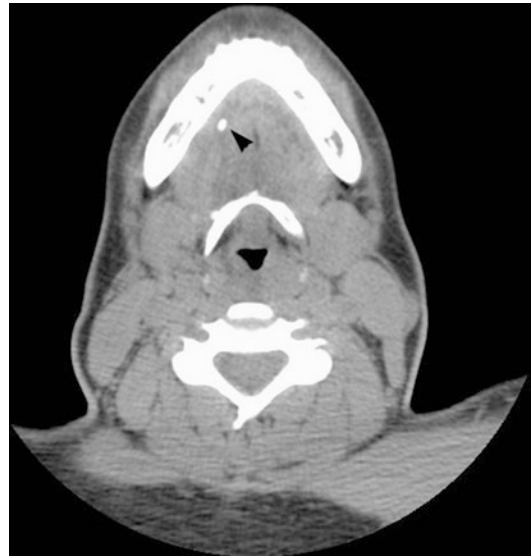

Fig. 2.9 CT scan without contrast demonstrates a small calcification (*black arrowhead*) in the right anterior floor of mouth that was missed on the formal radiographic report. Evaluation of the full course of the submandibular gland and duct is necessary to evaluate for sialolithiasis

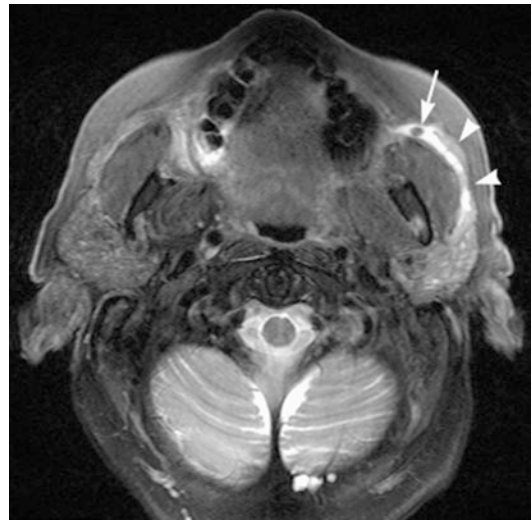


Fig. 2.10 T2-weighted MRI scan allows visualization of salivary stasis within a dilated left parotid duct (*arrowheads*). The distal portion of the duct is obstructed with a salivary stone (*arrow*) that can be seen when surrounded by the hyperintense saliva within the duct

sialography depend on visualization of the salivary ducts on T2-weighted or contrast-enhanced images. Sialoliths are then detected by the presence of a flow void inside the duct (Fig. 2.10).

The location of a calculus on imaging helps with surgical planning and preoperative counseling. Parotid duct calculi located in the proximal gland posterior to the masseter muscle are difficult to visualize on sialendoscopy, and many of these patients may require a combined approach with transfacial incision for management of calculi in this location. Calculi found near the parotid papilla distal to the anterior masseter border can be managed with endoscopic techniques or through transoral sialodochotomy for removal through a small incision in the buccal mucosa [2].

Chronic Sialadenitis from Autoimmune and Granulomatous Disease

The most common autoimmune disease to affect the salivary glands is Sjogren's syndrome. Sjogren's syndrome causes destruction of salivary gland parenchyma. Imaging can reveal bilateral and multiple cystic and solid lesions, making the parenchyma appear heterogeneous (Fig. 2.11a). Cystic degeneration reflects tissue destruction and solid masses represent lymphocyte aggregates. The glands can also display abnormally increased fat deposition and multiple punctate calcifications [13]. US will demonstrate bilateral parotids that appear heterogeneous with hypoechoic lesions and prominent intraparotid lymph nodes. CT imaging can reveal multiple punctate calcifications within the gland that should not be confused with larger salivary duct sialoliths (Fig. 2.11b). MR imaging dis-

plays diffuse high-intensity T2 foci within the gland. Sialography is sensitive to diagnosis of Sjogren's syndrome displaying punctate sialectasis (Fig. 2.11c) progressing to globular and cavitary parotid duct changes with more advanced disease [13]. Risk for malignant transformation to non-Hodgkin's lymphoma in the gland is 16- to 40-fold higher in patients with Sjogren's syndrome so annual monitoring is recommended and can be done with ultrasound. The 2002 American-European Consensus Group classification criteria for Sjogren's syndrome describes the use of three possible measures of salivary gland hypofunction: (1) unstimulated whole salivary flow (<1.5 ml in 15 min); (2) parotid sialography showing diffuse sialectasis; or (3) salivary scintigraphy showing delayed uptake, reduced concentration, and/or delayed excretion of tracer [14]. Since then the use of ultrasound to examine for signs of salivary gland degeneration is as effective as sialography in differentiating between patients with and without Sjogren's syndrome [15]. The current American College of Rheumatology classification for Sjogren's syndrome includes three objective measures for diagnosis using (1) lymphocytic infiltrates in lip biopsy specimens, (2) serum testing for anti-SSA and/or SSB antibodies or ANA and RF, and (3) ocular staining test. The use of US as an alternative third ACR classification item yielded similar sensitivity and specificity to the original classification suggesting that US may be useful in place of other more invasive tests [16].

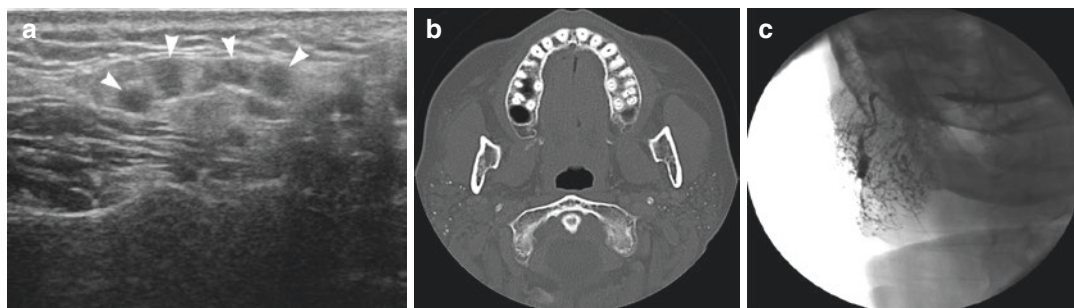
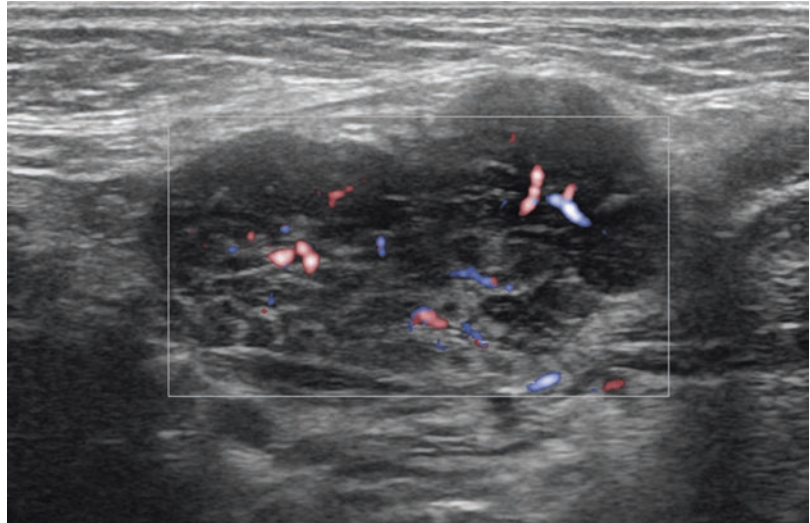


Fig. 2.11 Chronic sialadenitis from Sjogren's syndrome manifests with parotid degeneration: heterogeneous parenchyma with multiple hypoechoic areas on US (a), multiple punctate calcifications with the gland (b), and

dilated acini with ductal strictures that appear as multiple areas of contrast collection on sialography (c). Sialogram figure courtesy of Hoffman HT, Iowa Head and Neck Protocols

Fig. 2.12 Ultrasound image of the right submandibular gland in a patient with IgG4-related sialadenitis with enlarged and firm bilateral submandibular glands. The gland demonstrates heterogeneity, enlargement, and hypervascularity. No tumor or lesions were found within the gland, and the patient was treated with an oral steroid regimen



Other chronic immune-mediated and granulomatous diseases can mimic the gland heterogeneity seen in Sjogren's syndrome: sarcoidosis, HIV infection, lymphoma, juvenile recurrent parotitis, and IgG4-related sialadenitis (formerly Mikulicz's disease or Kuttner's tumor) (Fig. 2.12). Clinical differentiation with symptoms and laboratory testing is still necessary to distinguish between these disease entities.

Stenosis

Salivary duct stenosis can be demonstrated on US as dilated salivary ducts without intraductal obstructive calculi. A dilated main parotid duct can be visualized in the transverse plane running over the masseter muscle (Fig. 2.2a). Stenosis can be idiopathic or associated with immune-mediated salivary disease, prior radioactive iodine treatment, trauma, or mechanical obstruction from masseter hypertrophy with kinking of the parotid duct. Longstanding focal stenoses of the papilla can lead to significant salivary duct dilation (Fig. 2.2a). Sialography can also demonstrate the location and length of stenoses (Fig. 2.5). Distal duct stenosis can be dilated using progressive dilators or sialendoscopy. Intraoperative ultrasound guidance can confirm instrument placement within the salivary duct [17].

Chronic sialadenitis from long-term stenotic obstruction or autoimmune disease leads to changes in the gland parenchyma. The gland tissue

becomes heterogeneous with scattered hypoechoic areas that represent degenerative salivary tissue, lymphoid tissue infiltration, and dilated salivary ducts [3]. Multiple microcalcifications within the parenchyma of the gland also represent this inflammatory process and should not be confused for intraductal calculi (Fig. 2.11b). End-stage inflammatory or post-radiation disease produces an atrophic gland with minimal salivary output.

References

1. Rzymska-Grala I, Stopa Z, Grala B, Golebiowski M, Wanyura H, Zuchowska A, et al. Salivary gland calculi—contemporary methods of imaging. *Pol J Radiol*. 2010;75(3):25–37.
2. Kiringoda R, Eisele DW, Chang JL. A comparison of parotid imaging characteristics and sialendoscopic findings in obstructive salivary disorders. *Laryngoscope*. 2014;124(12):2696–701. doi:10.1002/lary.24787.
3. Jecker P, Orloff LA. Salivary gland ultrasonography. In: Orloff LA, editor. *Head and neck ultrasonography*. San Diego: Plural Publishing; 2008. p. 129–52.
4. Harnsberger HR, Glastonbury CM. Parotid space. In: Harnsberger HR, editor. *Diagnostic imaging: head and neck*. Salt Lake: Amirsys; 2004. Section 7. p. 2–36.
5. Gritzmann N, Rettenbacher T, Hollerweger A, Macheiner P, Hubner E. Sonography of the salivary glands. *Eur Radiol*. 2003;13(5):964–75.
6. Smith-Bindman R, Lipson J, Marcus R, Kim KP, Mahesh M, Gould R, et al. Radiation dose associated with common computed tomography examinations and the associated lifetime attributable risk of cancer. *Arch Intern Med*. 2009;169(22):2078–86. doi:10.1001/archinternmed.2009.427.

7. Afzelius P, Nielsen MY, Ewertsen C, Boch KP. Imaging of the major salivary glands. *Clin Physiol Funct Imaging*. 2016;36(1):1–10. doi:[10.1111/cpf.12199](https://doi.org/10.1111/cpf.12199).
8. Hoffman HT (editor). Sialograms and sialography. In: Iowa head and neck protocols. 2015. <https://iowa-headneckprotocols.oto.uiowa.edu/display/protocols/Sialograms+and+Sialography>. Accessed 18 Mar 2016.
9. Becker M, Marchal F, Becker CD, Dulguerov P, Georgakopoulos G, Lehmann W, et al. Sialolithiasis and salivary ductal stenosis: diagnostic accuracy of MR sialography with a three-dimensional extended-phase conjugate-symmetry rapid spin-echo sequence. *Radiology*. 2000;217(2):347–58.
10. Jager L, Menaer F, Holzknecht N, Scholz V, Grevers G, Reiser M. Sialolithiasis: MR sialography of the submandibular duct – an alternative to conventional sialography and US? *Radiology*. 2000;216(3):665–71.
11. Shizukuishi K, Nagaoka S, Kinno Y, Saito M, Takahashi N, Kawamoto M, et al. Scoring analysis of salivary gland scintigraphy in patients with Sjogren's syndrome. *Ann Nucl Med*. 2003;17(8):627–31.
12. Sigismund PE, Zenk J, Koch M, et al. Nearly 3,000 salivary stones: some clinical and epidemiologic aspects. *Laryngoscope*. 2015;125(8):1879–82. doi:[10.1002/lary.25377](https://doi.org/10.1002/lary.25377).
13. Sun Z, Zhang Z, Fu K, Zhao Y, Liu D, Ma Z. Diagnostic accuracy of parotid CT for identifying Sjogren's syndrome. *Eur J Radiol*. 2010;81(10):2702–9. doi:[10.1016/j.ejrad.2011.12.034](https://doi.org/10.1016/j.ejrad.2011.12.034).
14. Vitali C, Bombardieri S, Jonsson R, et al. Classification criteria for Sjögren's syndrome: a revised version of the European criteria proposed by the American-European Consensus Group. *Ann Rheum Dis*. 2002;61:664–558.
15. Yonetsu K, Takagi Y, Sumi M, Eguchi K, Nakamura T. Sonography as a replacement for sialography for the diagnosis of salivary glands affected by Sjogren's syndrome. *Ann Rheum Dis*. 2002;61:276–7.
16. Takagi Y, Sumi M, Nakamura H, Iwamoto N, Horai Y, Kawakami A, Nakamura T. Ultrasounography as an additional item in the American College of Rheumatology classification of Sjogren's syndrome. *Rheumatology*. 2014;53(11):1977–83. doi:[10.1093/rheumatology/keu238](https://doi.org/10.1093/rheumatology/keu238).
17. Ryan WR, Chang JL, Eisele DW. Surgeon-performed ultrasound and transfacial sialoendoscopy for complete parotid duct stenosis. *Laryngoscope*. 2014;124(2):418–20. doi:[10.1002/lary.23968](https://doi.org/10.1002/lary.23968).

Salivary Fine Needle Aspiration Biopsy

3

William R. Ryan, A. Sean Alemi,
and Annemieke van Zante

Key Points

1. Salivary surgeons must be aware of the benefits and limitations of fine needle aspiration (FNA) in the diagnosis of salivary pathology.
2. Immediate assessment of FNA adequacy and quality by an experienced cytopathologist may reduce the time to diagnosis.
3. FNA with ultrasound guidance may improve specimen adequacy and diagnostic yield.

Impact of Salivary FNA

Information obtained from FNA can directly influence management of salivary masses. One study calculated a degree of impact of cytologic diagnosis as changing management at least 35% of the time [1]. FNA can help guide clinicians to avoid surgery

for conditions, such as lymphoma or inflammatory lesions, and implement conservative observational approaches for certain benign tumors (particularly in the following situations: frail patients at a higher risk for complications with surgery under a general anesthetic, some asymptomatic patients, and patients hesitant to undergo surgery). FNA cytology can contribute a specific or differential diagnosis allowing appropriate preoperative counseling regarding the extent of resection, facial nerve management, the need for neck dissection, and the degree of urgency. Preoperative cytologic diagnosis can also mentally prepare a patient for the final diagnosis based on surgical pathology, particularly when malignant.

FNA Technique

A cytopathologist, surgeon, or radiologist may perform FNA depending on the clinical situation and institutional policy. Identification of the target is essential to successful aspiration. Nonpalpable, ill-defined, or deep lesions are best aspirated under ultrasound or CT (computerized tomography) guidance. Superficial nodules are best done by palpation or ultrasound guidance. Parapharyngeal or some deep lobe parotid lesions, when not easily visualized or palpable trans-orally, are best targeted with computed tomography (CT) scan guidance.

W.R. Ryan, M.D., F.A.C.S.
Division of Head and Neck Oncologic, Endocrine and Salivary Surgery, Department of Otolaryngology—Head and Neck Surgery, University of California-San Francisco, San Francisco, CA, USA
e-mail: William.Ryan@ucsf.edu

A. Sean Alemi, M.D.
Department of Otolaryngology—Head and Neck Surgery, University of California-San Francisco, San Francisco, CA, USA

A. van Zante, M.D., Ph.D.
Department of Pathology, University of California-San Francisco, San Francisco, CA, USA

Equipment

23- or 25-gauge needles
 10 cc syringes
 Aspirating gun or syringe holder
 1% lidocaine
 Alcohol swabs
 Glass slides
 95% methanol in Coplin jars
 Gauze
 Adhesive bandages
 Ultrasound transducer and machine
 If evaluation of the specimen is planned:
 0.5% toluidine blue or Diff-Quik stains
 Microscope

FNA Procedural Steps

1. Prepare local anesthetic and a 25- or 23-gauge needle on a 10 cc syringe attached to a syringe holder.
2. In cases of palpable and superficial lesions, immobilize the nodule between the fingers.
3. Clean the skin with an alcohol swab.
4. Apply local anesthetic along the intended needle path. *Do not inject the target lesion as this diminishes yield and results in cellular artifact.*
5. Insert the biopsy needle through the skin into the nodule and then apply gentle suction (1–2 cc). *Excessive suction can result in hemodilution and diminished cellularity.*
6. Maintain suction, while the needle transverses the long axis of the nodule approximately ten times or until a trace of blood is detected in the needle hub.
7. Release suction and then withdraw the needle from the nodule and overlying skin.
8. An assistant (or the patient) should apply direct, firm pressure to the site.
9. Remove the needle from the syringe, aspirate 5 cc of air into the syringe, then reattach the needle, and expel the material onto glass slide(s).
10. Immediately smear slides and drop into alcohol fixative (for Papanicolaou stain) or allow to air-dry (for Diff-Quik stain). *Only a small droplet should be applied to each slide, and care should be taken to apply consistent pressure to distribute the material evenly.*

FNA technique should be rehearsed so that a sample can be expediently obtained, smeared, and fixed. Clotted specimens and/or thick smears can limit visualization of otherwise cellular aspirates. Fresh beef or chicken liver can be utilized to practice biopsy and smear techniques. Targeting nodules under ultrasound guidance should be rehearsed with an ultrasound phantom containing targets of various size and contour.

Immediate Assessment

Immediate microscopic assessment of FNA samples at the bedside is invaluable to ascertain whether the sample is sufficiently cellular for a diagnosis to be rendered. Evaluation can be performed on alcohol-fixed slides using toluidine blue (a temporary dye) or on air-dried slides stained with Diff-Quik. If the specimen is inadequate, the procedure should be repeated. When sampled appropriately, less than 10% of FNA specimens are insufficient for diagnosis. A recent publication of ultrasound-guided FNA for head and neck masses, including thyroid nodules, salivary gland masses, and lymph nodes, provides excellent tips as a practice guide [2]. In this study, 617 cases were reviewed, and only 6.1% of samples were insufficient for diagnosis. Samples are more likely to be nondiagnostic if the lesion is entirely cystic or if rim calcification is present. Dense, fibrous lesions generally yield scant material, and highly vascular targets can result in significant hemodilution of the sample. Overall, specimen quality increases in association with the experience of the clinician performing the biopsy, with a threshold of approximately 100 procedures [2]. The feedback from immediate assessment can result in improved biopsy technique and appropriate triage of the specimen for adjunctive studies.

Specimen Triage

If necessary, a formalin-fixed sample can be prepared by gently rinsing the contents of the needle and hub into a small volume of formalin with a syringe. Centrifugation of formalin-fixed material results in a “cell block” which can be

paraffin embedded. This type of preparation should be processed identically to a small punch or incisional biopsy and allows for special studies such as immunohistochemistry or fluorescence in situ hybridization (FISH) to be performed [3]. Labs have different methods of cell block processing. Careful attention to cellular yield, specimen preservation, and sectioning helps in achieve optimal histologic specimens. If lymphoma is suspected based on the clinical presentation and/or immediate assessment, a sample should be submitted for flow cytometric immunophenotyping. This study primarily provides information regarding the cell surface markers on lymphoid cells and can establish monoclonality, a finding that supports the diagnosis of hematologic malignancy. Specimens intended for flow cytometry should be held at room temperature in fresh cell culture medium. Samples for parathyroid hormone, thyroglobulin testing, or molecular studies require special handling, and instructions should be obtained from the clinical lab prior to the biopsy procedure.

Surgeon-Performed FNA

Surgeon-performed fine needle aspiration biopsy with or without ultrasound (US) guidance is certainly possible and can be particularly convenient for the patient. Separately scheduled biopsy procedures require additional communication and transportation and have the potential for delay in diagnosis and treatment. Surgeon-performed biopsy eliminates the possibility of miscommunication regarding the target(s) for biopsy. Collaboration between a surgeon who performs FNA and the cytopathologist who assesses for specimen adequacy can result in a preliminary/working diagnosis and expedite evaluation and treatment planning. Importantly, pathologists have variable training and experience in providing support in the clinical setting. At some institutions, cytotechnologists (technologists trained in interpretation of cytologic samples) are deployed to provide support, including specimen preparation, rapid interpretation, and triage. At some medical centers (including the authors'

institution), cytopathologists are available to visit the surgeon's clinic and perform FNA biopsies. This practice has many advantages, including patient convenience, the opportunity for immediate communication of preliminary results, and frees up the surgeons to continue work in clinic with other patients, while the procedure is being performed.

Ultrasound-Guided FNA

Ultrasound-guided FNA (USGFNA) is important for non-palpable, ill-defined, or deep nodules. With appropriate training, many structures in the head and neck can be visualized in a safe and convenient manner utilizing clinical US. US guidance, particularly for the submandibular and parotid glands, may increase accuracy [4–6]. FNA of lesions of the sublingual gland and minor salivary glands are not likely to require ultrasound guidance, given that they are frequently accessible via a trans-oral approach.

Depending on the level of training and availability of experienced surgeons, cytopathologists, and radiologists at a particular institution, the optimal practitioner performing FNA and/or USGFNA may vary. Surgeon-performed ultrasound is popular in Europe and is gaining popularity in the United States. Similarly, surgeon-performed USGFNA procedures are becoming routine. One principle advantage of surgeon-performed USGFNA is the ability to correlate history and physical examination findings with US images and, in the optimal setting, preliminary cytology results within a single office visit. Other advantages of surgeon-performed biopsies include convenience to the patient, less potential for lapse in communication, and expedited workup. In many clinical settings, trained cytopathologists and/or radiologists are not immediately available to perform FNA; thus surgeons have the opportunity to gain expertise in US imaging and biopsy. Additionally, ultrasound-guided FNA can be useful in sampling some palpable lesions and can contribute to a higher diagnostic rate when compared to

standard palpation techniques alone [7]. However, these advantages need to be weighed against the need for additional training and continual practice to maintain expertise, as well as the potential impact on the surgeon's efficiency in the clinic.

CT-Guided FNA

CT-guided FNA is sometimes necessary for targeting salivary lesions arising from the deep lobe of the parotid gland and occupying the parapharyngeal space. Tumors arising from submucosal minor salivary glands along the upper aerodigestive tract may not be accessible transorally nor visible by ultrasound. Interventional radiologists typically perform CT-guided FNA after cross-sectional imaging is obtained. These procedures require significant time and resources and are, in general, performed under conscious sedation in addition to local anesthesia. The procedure for CT-guided FNA is similar to palpation-guided procedures; however a guiding needle may be placed and multiple specimens obtained through this "coaxial" system. Patients undergo repeated CT imaging in order to guide the radiologist and confirm the site for biopsy. Given the expense of CT-guided procedures, rapid microscopic interpretation for adequacy by a cytotechnologist or cytopathologist is highly recommended.

Patient Perspective of FNA

Because of the smaller gauge needle, many patients prefer FNA instead of core needle biopsy or an incisional biopsy. The likelihood of significant hematoma or infectious complications is dramatically less with a fine needle when compared with more invasive procedures. An additional benefit to the patient is the option for a biopsy during the same office visit as their surgical consultation. If a system is in place where a cytopathologist can expedite review of the sample, the clinician can counsel the patient on management options during the initial consultation.

Benefits of FNA Versus Surgical Biopsy

While FNA lacks the tissue architecture offered by larger core needle or open biopsies, the high diagnostic accuracy and increased patient tolerance make FNA the diagnostic procedure of choice for salivary gland neoplasms. Moreover, the risk for seeding the tumor into the needle tract or tissue distortion due to biopsy site changes is minimized with smaller bore needles > 20 gauge. In addition, FNA is unlikely to result in bleeding thereby making it unnecessary to stop anticoagulant medications. Though there are very few contraindications to FNA, in some cases incisional or excisional biopsies should be favored when considering the risks and the suspected pathologic process. Examples of neoplasms which can result in a falsely reassuring FNA results include lipomatous lesions that are concerning for liposarcoma, some T-cell lymphomas, and unusual histiocytic tumors such as Rosai-Dorfman. Sometimes an FNA will not be diagnostic or show benign cellular elements when other studies suggest a neoplastic process. In these cases, a more substantial sample is required prior to definitive therapy. However, in some cases, even a scant FNA sample is informative and can support conservative management. For example, a schwannoma is a benign nerve sheath tumor which typically yields very scant material on FNA. A sample containing a few, bland, spindle cells consistent with nerve sheath elements can, in the appropriate clinical setting, safely be followed when correlated with a benign clinical examination and appropriate imaging such as MRI.

Fine Needle Aspiration Versus Frozen Section

Although frozen section has limitations, it allows assessment of larger tissue samples and can demonstrate histologic features (i.e., invasion) that can support the diagnosis of malignancy in some cases where cytologic analysis cannot. One study reviewed 220 cases of parotid gland FNA and compared results of FNA biopsy with frozen section histology in 57 of those cases. Sensitivity, specificity, and

accuracy for FNA were found to be 86%, 92%, and 90%, respectively. In comparison, the sensitivity, specificity, and accuracy of the frozen sections were 77%, 100%, and 88%. In this study, frozen sections changed four FNA diagnoses from malignant to benign and clarified the diagnosis in 5 of 12 cases where FNA was nondiagnostic [8]. Thus, depending on the practice setting, FNA can be more sensitive, while frozen section can be more specific. Where both high-quality cytopathology and frozen section services are available, the two techniques are complementary.

Complications of FNA

FNA is generally considered to be safe; complications are extremely rare. Patients should be advised of these risks during the informed consent process prior to the procedure.

Inadequate Sampling

Inadequate sampling is biggest source of diagnostic error in cytopathology [9]. Rapid assessment can reduce the number of insufficient samples, but in the absence of immediate evaluation, nondiagnostic procedures or false-negative specimens should be expected. If the cytologic diagnosis is not in accord with the imaging findings or clinical impression, further evaluation should be pursued with consideration of repeat fine needle, core biopsy, or an excisional biopsy.

Anxiety and Discomfort

Most patients benefit from a clear explanation of the FNA procedure and the application of local anesthesia along the needle tract. Given that anesthetic should not be injected into the target lesion, many patients will have sharp, transient pain during and, in some cases, immediately after the biopsy procedure. Patients should be informed that some discomfort is expected but is of limited duration. Significant radiating pain can be associated with biopsy of a benign or malignant nerve sheath tumor or in cases of a malignancy with

perineural invasion; the patient's report of significant radiating or lasting discomfort in these cases can be diagnostically informative.

Local Hemorrhage/Hematoma

Although bleeding at the insertion site and tract of the needle is certainly possible given the vascularity of the regions surrounding the salivary glands, this is unlikely to be a clinically significant or a common problem. Applying firm pressure in the site immediately after the biopsy can prevent and reduce hemorrhage and hematoma formation. A higher risk of hemorrhage or hematoma exists for patients on anticoagulant medications. In such patients, superficial nodules may be aspirated with minimal risk. For deeper nodules, or lesions in close proximity to larger caliber blood vessels, stopping anticoagulants prior to the procedure should be considered.

Infection

Infection from FNA biopsy is extremely rare and is closely correlated with the patient's immune status. The risk is equivalent to that of phlebotomy. The skin should be cleaned with an alcohol swab prior to biopsy, and sterile technique should be maintained during the procedure.

Syncope

Some patients are susceptible to vasovagal reactions to needle insertion. Performing aspiration while the patient is lying down or, at a minimum, sitting may help prevent this complication. All patients should be observed for several minutes prior to discharge from the clinical setting.

Needle Tract Contamination by Malignant Cells

Numerous studies indicate that needle tract contamination by malignant cells is a very rare complication with thousands of fine needle aspirations

performed worldwide yearly. A study of salivary gland adenomas found tumor cells along the needle track immediately following aspiration with a 22-gauge needle, but this was not shown to increase tumor recurrence at 5-year follow-up [10]. Theoretically, a risk of dissemination of dislodged neoplastic cells into lymphatics and blood vessels exists: *this risk appears to be lower in FNA than with incisional biopsy*. There was no seeding risk found in a study of 94 resected masses based on histopathologic assessment of specimens [11].

Fibrosis and Biopsy Site Changes

Despite being a relatively small needle, minor trauma caused by FNA can result in fibrosis or scarring around important structures, particularly around the facial nerve. This can create manual and visual difficulties during subsequent surgical dissection in the area. Furthermore, tumor infarction, displacement of neoplastic cells, and fibrosis can complicate pathologic assessment after FNA biopsy is performed preoperatively. Pathologists must take the history of biopsy into account when assessing invasiveness. Biopsy site changes can be erroneously interpreted as capsular invasion of a neoplasm or extranodal extension of a metastatic tumor. Thus, the history of prior biopsy should be conveyed to the surgical pathologist when a specimen is submitted.

Diagnostic Accuracy

There are many different patterns of inflammatory disease and dozens of benign and malignant salivary gland neoplasms. Furthermore, many of these conditions are very rare. Studies have demonstrated that the sensitivity of FNA for salivary gland neoplasia ranges from 80 to 100% while the specificity ranges from 90% to 100% [8, 12, 13]. In high-volume academic centers, salivary FNA has a positive predictive value of 80–98% [14–18] and can correctly differentiate between malignant and benign tumors 81–98% of the time [8]. These accuracy values are higher for benign

neoplasms compared to malignancies [19, 20]. Higher accuracy is associated with more experienced cytopathologists, higher volume of specimens, and academic institutions compared to community practice settings [21, 22]. The level of expertise should be taken into account by the clinician when managing salivary pathology. Ultimately, inadequate sampling is biggest source of error [9]. Even with appropriate sampling, some patients may require excision for definitive diagnosis.

Possible Sources of Error in Salivary Gland FNA

Sampling Error

As previously mentioned, an insufficient sample is the most common error in salivary gland FNA. Direct communication between the surgeon (or clinician) and the cytopathologist to confirm the location of the proposed target can minimize such errors. Proper immobilization of the lesion additionally helps reduce under-sampling.

Interpretation Error

Errors in interpretation are inversely related to the experience of the cytopathologist; high-volume centers with more experienced pathologists will be less predisposed to such errors. Clinicians should consider requesting consultation with a cytopathologist with salivary expertise when the cytologic diagnosis is vague or at odds with the clinical presentation and the specimen is otherwise adequate.

Bias

The clinical setting can inform the cytologic diagnosis; thus it is advantageous for the same cytopathologist to perform the biopsy and interpret the specimen. However, pathologists can be biased based on past experience, the clinical picture, and/or the clinician's opinion. These factors can potentially lead to errors in diagnosis [23].

Technical Problems

Delay in fixation of smears can lead to air-drying artifact, one of the most common technical

Table 3.1 Common diagnostic considerations in FNA of salivary gland

Benign neoplasms	Malignant neoplasms	Lymphadenopathies	Inflammatory conditions	Cystic lesions
Pleomorphic adenoma	Mucoepidermoid carcinoma	Reactive lymph node	Acute sialadenitis	Branchial cleft cyst
Warthin tumor	Adenoid cystic carcinoma	Sarcoidosis	Chronic sialadenitis	Lymphoepithelial cyst
Basal cell adenoma	Basal cell adenocarcinoma	Lymphoma	Sjögren’s syndrome	Mucous retention cyst
Myoepithelioma	Salivary duct carcinoma	Metastasis (carcinoma or melanoma)	IgG4-related sialadenitis	Cystic metastasis

problems in cytopathology. In addition, smears can be obscured by peripheral blood, fibrin strands/clot, inflammation, or ultrasound gel. Poor stain quality can limit cellular detail. These factors can result in false-positive or false-negative diagnoses.

Diagnostic Categories

There are five broad categories in salivary gland disease identified in cytologic specimens: normal, inflammatory/cystic masses, intraparotid lymphadenopathy, benign neoplasms, and malignant neoplasms. See Table 3.1 for common diagnostic considerations in FNA of salivary gland.

Normal Salivary Tissue

Given that a biopsy needle often traverses normal gland, normal salivary tissue can often be found even in abnormal samples (abnormal and normal tissue are mixed). Missing the target with the needle will also result in the finding of normal salivary elements. In lesions such as sialosis, hamartoma, or even lipoadenoma, samples contain only normal/expected tissues. Aspiration of a benign gland results in acinar and ductal cells admixed with adipose tissue. Normal lymphoid tissue is obtained when lymph nodes in or adjacent to the gland are aspirated. Serous and/or mucinous type acinar cells are found in various proportions with the parotid gland showing predominantly serous type, the submandibular gland showing serous and mucinous types, and mostly mucinous type in the minor salivary

glands. Acinar cells are extremely delicate with pyramidal shape, granular or pale mucinous cytoplasm, and compact, round nuclei. Intact serous acinar cells are usually cohesive and found in grape-like clusters. Ductal cells have cuboidal or columnar shape with relatively dense cytoplasm and usually form tubules or honeycomb-like flat sheets. Adipose tissue generally consists of large lipid-filled cells with small, round, peripheral nuclei.

Inflammatory Conditions

Acute sialadenitis is typically a clinical diagnosis, and FNA is not generally indicated for patients with the expected clinical presentation. If frank pus is aspirated or immediate assessment of an FNA sample demonstrates abundant neutrophils and necrotic debris, material should be submitted for microbiologic cultures. Similarly, patients presenting with classic signs/symptoms of chronic sialadenitis do not require FNA. However some cases of focal duct obstruction or submandibular ptosis can mimic a neoplasm. Fine needle aspiration typically yields a heterogeneous population of lymphocytes admixed with scant atrophic ducts. Granular mineralized debris can be seen in cases of obstruction by sialolith(s). When abundant chronic inflammation and normal acini are lacking, FNA samples of chronic sialadenitis containing atrophic ductal epithelium can be misinterpreted as representing a “basal cell neoplasm.” This is a known pitfall, but distinguishing benign atrophic ductal epithelium and neoplastic epithelium can be challenging, especially in the setting of prior radiation.

Both autoimmune sialadenitis and IgG4-related sialadenitis demonstrate cytologic features that overlap with non-specific/obstructive sialadenitis. Autoimmune etiology and a diagnosis of Sjögren's syndrome can be supported by incisional biopsy of labial salivary glands and appropriate serologic studies. The diagnostic features of IgG4-related disease have been established for histologic specimens and include a lymphoplasmacytic infiltrate with numerous IgG4+ plasma cells, storiform fibrosis, and obliterative phlebitis. Fibrosis and phlebitis are not evaluable in FNA specimens. Thus, if this diagnosis is a consideration, most clinicians would consider incisional biopsy. FNA criteria for IgG4-related disease have not been established; however if FNA biopsy is undertaken, a cell block should be prepared and immunostaining for IgG4+ plasma cells performed. Serum IgG4 is also frequently elevated in this condition and can be supportive and should be considered especially if there is evidence of multi-gland (e.g., liver, gallbladder, pancreas) involvement.

Cystic Lesions

Significant overlap exists between the cytologic features of various cystic lesions of the lateral neck. Careful evaluation of the epithelial lining of a cystic mass is essential to arrive at the correct diagnosis. Unfortunately, cyst fluid samples are typically dominated by proteinaceous fluid and histiocytes with degenerated lining cells representing a minor component. Targeting of the cyst wall under ultrasound guidance can sometimes be helpful, even when the mass is otherwise palpable. The possibility of cystic metastatic squamous cell carcinoma should always be considered in adult patients. Other diagnostic entities are branchial cleft cyst, lymphoepithelial cyst, mucocele/mucous retention cyst, and a cystic Warthin tumor. Developmental remnants are more likely in pediatric and young adult patients, and the identification of ciliated columnar "respiratory-type" epithelium, when present, is characteristic of a branchial cleft cyst.

Lymphoepithelial cysts show scant attenuated epithelium in a background of abundant reactive lymphoid tissue. These cysts tend to be bilateral, have characteristic imaging features, and are most common in patients with human immunodeficiency virus (HIV) infection. Typically, these patients can be managed by serial examinations and occasional therapeutic aspiration. While mucous extravasation most commonly involves the minor glands of the lip, a larger pseudocyst or ranula can arise from the sublingual or, less frequently, from the submandibular gland. This entity is exceedingly rare in the parotid region, and a mucoid aspirate from the parotid gland is most suggestive of a cystic mucoepidermoid carcinoma. Nonneoplastic mucinous lesions are usually hypocellular, with minimal atypia. The presence of abundant or atypical mucinous epithelium favors the diagnosis of a neoplasm. If FNA is equivocal, excision of the gland may be necessary for both diagnostic and therapeutic purposes.

Intraparotid Lymphadenopathy

The parotid gland contains a rich network of lymphatics that drain the auricle and scalp. These nodes can become enlarged as a result of inflammatory, benign, or malignant disease. Reactive lymph nodes can occur as a result of transient viral or bacterial infections and are rarely cause for concern. Persistent lymph node enlargement and abnormal radiographic appearance should trigger further evaluation. Metastatic squamous cell carcinoma from the scalp, auricle, or external auditory canal skin can present as nodal disease within the parotid. Squamous cell carcinoma is the most common metastasis to the parotid and much more likely than squamous cell carcinoma primary to the salivary gland. Melanoma also commonly metastasizes to the intra- or periparotid lymph nodes. Accordingly, patients with enlarged nodes should be questioned regarding a history of cutaneous malignancy.

While parotid enlargement can frequently indicate nodal metastasis, several systemic inflammatory conditions exist which can mimic

neoplastic processes. Patients with sarcoidosis can develop parotitis, uveitis, and fever, a condition known as Heerfordt's syndrome. Similarly, autoimmune destruction of salivary glands as seen in Sjögren's disease can cause gland enlargement. Sjögren's is associated with low-grade marginal zone (MALT) lymphoma. Thus, even when the clinical setting suggests an autoimmune process, FNA sampling may be indicated to exclude a lymphoproliferative disorder.

The diagnosis of lymphoma by FNA typically rests on a combination of morphology and immunophenotyping by flow cytometry. High-grade lymphoma generally consists of large, markedly abnormal lymphocytes. In contrast, low-grade lymphoma typically consists of monotonous, small, mature-appearing lymphocytes. Flow cytometric analysis can demonstrate monoclonality along with co-expression of characteristic cell surface markers allowing appropriate subtyping. However flow cytometry requires additional sampling and expedient processing. At times, an incisional or excisional biopsy may be necessary to obtain tissue architecture or for immunohistochemical stains for definitive classification of a hematopoietic neoplasm. In cases where FNA is suspicious, but a surgical biopsy is necessary to characterize a lymphoma involving intra- or peri-parotid lymph nodes, an open lymph node biopsy should be considered. Parotidectomy can generally be avoided in these cases, sparing the patient extensive surgery and potential morbidity. While clinical history and examination are helpful in differentiation of inflammatory and neoplastic lymphadenopathy, FNA can contribute significantly. The false-negative rate of lymph node FNA performed by expert cytopathologists is approximately 2–3%. Thus, most patients with a benign FNA can safely be followed.

Benign Salivary Neoplasms

The majority of salivary gland tumors are benign. Pleomorphic adenoma and Warthin tumor (papillary cystadenoma lymphomatosum) make up most of these benign neoplasms. Cytologic diag-

nosis of pleomorphic adenoma is generally straightforward; however usually cellular specimens or the presence of atypia may result in a less specific diagnosis of “low-grade neoplasm” being rendered. Smears characteristically show ductal and myoepithelial elements along with extracellular fibrillary stroma. When all three elements are present, the sensitivity and specificity of FNA for pleomorphic adenoma are extremely high [24]. Generally, given the risk of continued growth and malignant transformation, pleomorphic adenomas should be excised. Similarly, the recommendation is that basal cell adenoma and myoepithelioma be completely excised as basal cell adenoma can be confused with adenoid cystic carcinoma and histologic evaluation is required to definitively distinguish an adenoma or myoepithelioma and adenocarcinoma or myoepithelial carcinoma.

Warthin tumor, similar to pleomorphic adenoma, has characteristic cytologic findings. Aspirate smears show sheets of oncocytic epithelium associated with lymphocytes in a background of proteinaceous fluid. Findings are typically definitive; however infrequently squamous or mucinous metaplasia can be present and raise the concern for carcinoma. Warthin tumors most often arise in patients with a history of smoking. Thus, concern for malignancy based on atypical cytologic findings may prompt excision for diagnostic purposes. Less common benign salivary tumors include oncocytoma, sebaceous adenoma, and lymphadenoma. Depending on the degree of certainty of the cytologic diagnosis, observation can be implemented for these other benign neoplasms, especially in elderly patients or patients at higher risk for general anesthesia.

Benign FNA in the Context of a Suspicious Nodule

Sometimes, despite a benign cytologic diagnosis, clinical findings are sufficiently concerning that surgical excision should be considered. Suspicious findings include pain, infiltrative borders, and ipsilateral facial nerve palsy. FNA specimens should be acquired in a manner that attempts to sample different areas of a lesion. However technical factors or patient tolerance

sometimes limits sampling. Thus, a benign cytologic diagnosis should always be considered in the context of the clinical history and physical exam. Surgery should be undertaken when suspicious clinical findings persist. Finally, surgical resection is also reasonable if patients have a cosmetic concern, especially if surgical risk is low.

Malignant Salivary Neoplasms

The diagnosis of malignancy for some low-grade salivary gland tumors rests on the histologic finding of invasion. For this reason, neoplasms lacking marked cytologic atypia may be assigned a general diagnostic category such as “low-grade salivary gland neoplasm” or “basaloid neoplasm” with a differential diagnosis. This practice allows for surgical planning despite the limitations inherent to a cytologic sample. The most common salivary gland malignancy is mucoepidermoid carcinoma comprising approximately 10–15% of all salivary gland neoplasms and being found in all major and minor salivary glands [25]. The majority of mucoepidermoid carcinomas are low grade, and it is these predominantly cystic, low-grade tumors that complicate the assessment of mucinous cysts.

Similar to a pleomorphic adenoma, an FNA sample of an adenoid cystic carcinoma consists of compact “basaloid” epithelial and myoepithelial cells along with metachromatic stromal material. For this reason, aspirates that lack unequivocal features of adenoid cystic carcinoma, including cribriform architecture and sharply demarcated metachromatic hyaline stromal spheres and cylinders, are assigned a diagnosis of “basaloid” or “basal cell” neoplasm. The differential typically includes benign entities such as pleomorphic adenoma and basal cell adenoma along with malignancies such as basal cell adenocarcinoma and adenoid cystic carcinoma. Standard immunohistochemical stains cannot distinguish between these entities; however the majority of adenoid cystic carcinomas have a translocation that results in a fusion of the MYB and NFIB transcription factors [26, 27]. If available, positive immunohistochemical stain-

ing for MYB can support the diagnosis of adenoid cystic carcinoma.

Mammary analogue secretory carcinoma of the salivary gland similarly has a characteristic translocation. Immunohistochemical reagents may contribute to definitive preoperative diagnosis of these tumors in the future. However, this type of specialized reagents is not available at all institutions. Collecting FNA specimens into formalin for processing as a cell block can allow the specimen to be submitted to a reference laboratory for appropriate adjunctive testing based on the cytologic findings.

As previously mentioned, the most common high-grade neoplasm found within the salivary gland is metastatic squamous cell carcinoma. Metastatic tumors from the skin and upper aerodigestive tract are common and can usually be recognized based on clinical findings and without extensive immunohistochemical evaluation. Careful history taking is warranted for other patients when the preliminary diagnosis is high-grade adenocarcinoma. High-grade tumors of salivary gland origin such as salivary duct carcinoma can have overlapping features with malignancies such as breast, prostatic, and pancreatic adenocarcinoma. In these cases, the cytopathologist should be informed of any history of systemic malignancy, and imaging may be warranted prior to extensive surgery.

Conclusions

Fine needle aspiration (FNA) is a safe and an effective technique in the primary diagnosis and surveillance of patients with salivary gland pathology. FNA can be performed in the outpatient office setting, and FNA specimens are suitable for adjunctive testing such as culture, immunostaining, and flow cytometry. The quality of the diagnosis obtained by FNA depends on the skill of the clinician obtaining the sample and the experience of the pathologist in interpreting it. Thus, the role of FNA in a practice setting depends on the expertise on hand. In a high-volume center with experienced cytopathologists, FNA is very frequently adequate to make decisions regarding patient management including

supporting conservative/non-operative management in some cases and limiting or extending the extent of surgery.

References

- Heller KS, Dubner S, Chess Q, Attie JN. Value of fine needle aspiration biopsy of salivary gland masses in clinical decision-making. *Am J Surg*. 1992;164(6):667–70.
- Ahn D, Kim H, Sohn JH, Choi JH, Na KJ. Surgeon-performed ultrasound-guided fine-needle aspiration cytology of head and neck mass lesions: sampling adequacy and diagnostic accuracy. *Ann Surg Oncol*. 2015;22(4):1360–5.
- Suen KC. Atlas and text of aspiration biopsy cytology. Baltimore, MD: Williams & Wilkins; 1990.
- Feld R, Nazarian LN, Needleman L, Lev-Toaff AS, Segal SR, Rao VM, Bibbo M, Lowry LD. Clinical impact of sonographically guided biopsy of salivary gland masses and surrounding lymph nodes. *Ear Nose Throat J*. 1999;78(12):905,908–12.
- Gritzmann N, Hollerweger A, Macheiner P, Rettenbacher T. Sonography of soft tissue masses of the neck. *J Clin Ultrasound*. 2002;30(6):356–73. Review
- Ivanová S, Slobodníková J, Janská E, Jozefáková J. Fine needle aspiration biopsy in a diagnostic workup algorithm of salivary gland tumors. *Neoplasma*. 2003;50(2):144–7.
- Robitschek J, Straub M, Wirtz E, Klem C, Sniezek J. Diagnostic efficacy of surgeon-performed ultrasound-guided fine needle aspiration: a randomized controlled trial. *Otolaryngol Head Neck Surg*. 2010;142(3):306–9.
- Seethala RR, LiVolsi VA, Baloch ZW. Relative accuracy of fine-needle aspiration and frozen section in the diagnosis of lesions of the parotid gland. *Head Neck*. 2005;27(3):217–23.
- MacLeod CB, Frable WJ. Fine-needle aspiration biopsy of the salivary gland: problem cases. *Diagn Cytopathol*. 1993;9(2):216–24. discussion 224–5.
- Engzell P, Jakobsson Å, Sigurdson Å, Zajicek J. Aspiration biopsy of metastatic carcinoma in lymph nodes of the neck: a review of 1 101 consecutive cases. *Acta Otolaryngol*. 1971;72(1–6):138–47.
- Mukunyadzi P, et al. Tissue effects of salivary gland fine-needle aspiration. Does this procedure preclude accurate histologic diagnosis? *Am J Clin Pathol*. 2000;114(5):741–5.
- Stewart CJR, MacKenzie K, McGarry GW, Mowat A. Fine-needle aspiration cytology of salivary gland: a review of 341 cases. *Diagn Cytopathol*. 2000;22:139–46.
- Mohammed Nur M, Murphy M. Adequacy and accuracy of salivary gland fine needle aspiration cytology. *Ir J Med Sci*. 2016;185(3):711–6.
- Gajanin R, Djurdjević D, Usaj SK, Eri Z, Ljubojević V, Karalić M, Risić T. Reliability of fine needle aspiration and ex tempore biopsy in the diagnosis of salivary glands lesions. *Vojnosanit Pregl*. 2014;71(11):1018–25.
- Tryggvason G, Gailey MP, Hulstein SL, et al. Accuracy of fine-needle aspiration and imaging in the preoperative workup of salivary gland mass lesions treated surgically. *Laryngoscope*. 2013;123(1):158–63.
- Nguansangiam S, Jesdapatarakul S, Dhanarak N, Sosrisakorn K. Accuracy of fine needle aspiration cytology of salivary gland lesions: routine diagnostic experience in Bangkok, Thailand. *Asian Pac J Cancer Prev*. 2012;13(4):1583–8.
- Kechagias N, Ntomouchtsis A, Valeri R, et al. Fine-needle aspiration cytology of salivary gland tumours: a 10-year retrospective analysis. *Oral Maxillofac Surg*. 2012;16(1):35–40.
- Siewert B, Kruskal JB, Kelly D, Sosna J, Kane RA. Utility and safety of ultrasound-guided fine-needle aspiration of salivary gland masses including a cytologist's review. *J Ultrasound Med*. 2004;23(6):777–83.
- Oka K, Chikamatsu K, Eura M, Katsura F, Yumoto E, Tokunaga H. Clinical significance of fine-needle aspiration biopsy in major salivary gland tumors. *Nihon Jibiinkoka Gakkai Kaiho*. 2002;105(11):1109–15. Japanese
- Verma K, Kapila K. Role of fine needle aspiration cytology in diagnosis of pleomorphic adenomas. *Cytopathology*. 2002;13(2):121–7.
- Jandu M, Webster K. The role of operator experience in fine needle aspiration cytology of head and neck masses. *Int J Oral Maxillofac Surg*. 1999;28(6):441–4.
- Pitts DB, Hilsinger RL Jr, Karandy E, Ross JC, Caro JE. Fine-needle aspiration in the diagnosis of salivary gland disorders in the community hospital setting. *Arch Otolaryngol Head Neck Surg*. 1992;118(5):479–82.
- Schmidt RL, Jedrzkiewicz JD, Allred RJ, Matsuoka S, Witt BL. Verification bias in diagnostic accuracy studies for fine and core needle biopsy of salivary gland lesions in otolaryngology journals: a systematic review. *Head Neck*. 2014;36(11):1654–61.
- Heaton CM, Chazen JL, van Zante A, Glastonbury CM, Kezirian EJ, Eisele DW. Pleomorphic adenoma of the major salivary glands: diagnostic utility of FNAB and MRI. *Laryngoscope*. 2013;123(12):3056–60.
- Majewski J, Schwartzentruber J, Lalonde E, Montpetit A, Jabado N. What can exome sequencing do for you? *J Med Genet*. 2011;48(9):580–9.
- The UK10K project. <http://www.uk10k.org/>. Accessed 25 Aug 2014.
- Ding LE, Burnett L, Cheshier D. The impact of reporting incidental findings from exome and whole-genome sequencing: predicted frequencies based on modeling. *Genet Med*. 2014;17(3):197–204.

Andrew Fuson, Nahir Romero, Bernard Mendis,
and Arjun S. Joshi

Key Points

1. Diagnostic office-based sialendoscopy is an option for cooperative adult patients with obstructive salivary symptoms of unknown etiology.
2. General anesthesia may be necessary for uncooperative patients, difficult anatomy, extensive disease, and/or need for invasive therapeutic intervention.

Introduction

Sialadenitis is the most common nonneoplastic disorder of the salivary glands [1]. Obstructive sialadenitis is the most common etiology with sialolithiasis being the most common underlying pathology (66%) in adults. Sialolithiasis affects the submandibular gland most commonly (80%) followed by the parotid gland (19%). Sialolithiasis of the sublingual gland and minor salivary glands is very unusual (1%). In children, the most common etiology of sialadenitis in the United States is juvenile recurrent parotitis, while the most common cause worldwide is paramyxovirus infection (mumps).

Conservative management of sialadenitis includes nonsteroidal anti-inflammatory medications (NSAIDs) to decrease local inflammation, sialogogues to encourage salivary flow, and antibiotics to treat bacterial infection. In chronic or recurrent sialadenitis, the gland was thought to be minimally or nonfunctional as a result of fibrosis and chronic inflammation. In these cases, the gland was excised. It has however been shown that there is no correlation between the number of episodes or duration of symptoms and pathologic changes in the gland. In fact, half of glands excised for appropriate indications were normal on pathologic analysis [2].

Gland-preserving salivary gland surgery in the form of transoral sialolithotomy has been the standard of care for sialolithiasis of the distal ductal system for decades, but gland-preserving treatment of obstructive sialadenitis not due to sialolithiasis or distal stones has proven difficult. In the early 1990s, the first attempts at sialendoscopy by flexible endoscope was published by Katz [3] and Gundlach [4], and the first endoscopic retrieval of salivary stones was reported by Nahlieli et al. [5] using a TMJ arthroscope for both parotid and submandibular sialolithiasis. In the ensuing years, the indications for sialendoscopy have broadened significantly.

Applications of office-based sialendoscopy were realized early on in the history of the procedure. Both Gundlach and Katz reported performing the exam under local anesthesia [3, 4].

A. Fuson, M.D. • N. Romero, M.D. • B. Mendis, B.S.
A.S. Joshi, M.D. (✉)
Division of Otolaryngology—Head and Neck
Surgery, George Washington University,
Washington, DC, USA
e-mail: iamaya@mfa.gwu.edu

As the options for intervention in sialendoscopy became more complex, more procedures were performed under general anesthesia. However, with proper experience and indications, we purport that the majority of cases of inflammatory salivary gland disease can be treated with office-based sialendoscopy.

The purpose of this chapter is to highlight the indications, contraindications, and limitations of office-based sialendoscopy. Specific consideration will be made to the importance of ultrasound for risk stratification, formulating a diagnostic plan, and aiding during office sialendoscopy.

Office-Based Sialendoscopy: Technique

Patient Tolerance

Perhaps the single most important prerequisite to successful office sialendoscopy is patient tolerance. This is influenced by a number of factors including physician rapport, patient comfort, local anesthesia, adequate anxiolysis when appropriate, and physician skill.

Before sialendoscopy the patient should be instructed to eat the morning of the procedure and should be well hydrated to avoid a vasovagal response during office sialendoscopy. In this preprocedural visit, it is also vital to build rapport with the patient to decrease preprocedural anxiety and increase patient tolerance to discomfort. During this visit the patient may also be prescribed anxiolysis as necessary. Given adequate preparation and explanation, the need for oral anxiolytic medications is rarely necessary.

The expertise of the proceduralist is also an important factor when considering office sialendoscopy. Data has shown that expertise scores increase and operative times decrease significantly after 10 and 30 cases of operative sialendoscopy. These performance measures continue to improve after 50 sialendoscopies [6]. Sialendoscopies are also more frequently successful in experienced hands. Aborted cases also

decrease with experience, and more glands are preserved [7, 8].

Tools and Setup

The materials below are used by the senior author during most office sialendoscopy cases and may be modified as needed (Fig. 4.1):

Lidocaine 1% with epinephrine injectable on a 27 gauge needle.

Lidocaine 4% viscous gel.

Salivary guide wire (0.015 in.).

Salivary ductal dilators (4Fr, 5Fr, 6Fr).

Cheek retractor.

Lacrimal probes.

Conical dilator.

Smooth pickups.

Tenotomy scissors.

Sialendoscope set (0.8, 1.1, 1.3 mm).

Wire basket.

Endoscopic balloons.

Methylene blue (optional).

Vitamin C (optional).

The patient should be seated in a semi reclining position with the head supported. The cheek retractor is then gently inserted to enable adequate visualization of the oral cavity. The proceduralist may wear a headlight or use an external light source. All necessary supplies should be arranged in the order of use on a Mayo stand in easy reach of the proceduralist or the assistant.

The assistant should stand on the opposite side of the patient to the proceduralist. The monitor is placed on either side of the patient, and the light source is placed on the patient's left (Fig. 4.2).

Ultrasound

Ultrasonography is the radiologic exam of choice in salivary gland pathology. This is particularly true when evaluating a patient for sialendoscopy, as it enables the proceduralist to precisely locate the area and type of pathology.

Office ultrasonography has up to a 96% accuracy when detecting sialolithiasis [9]. This enables the surgeon to numerate, characterize,

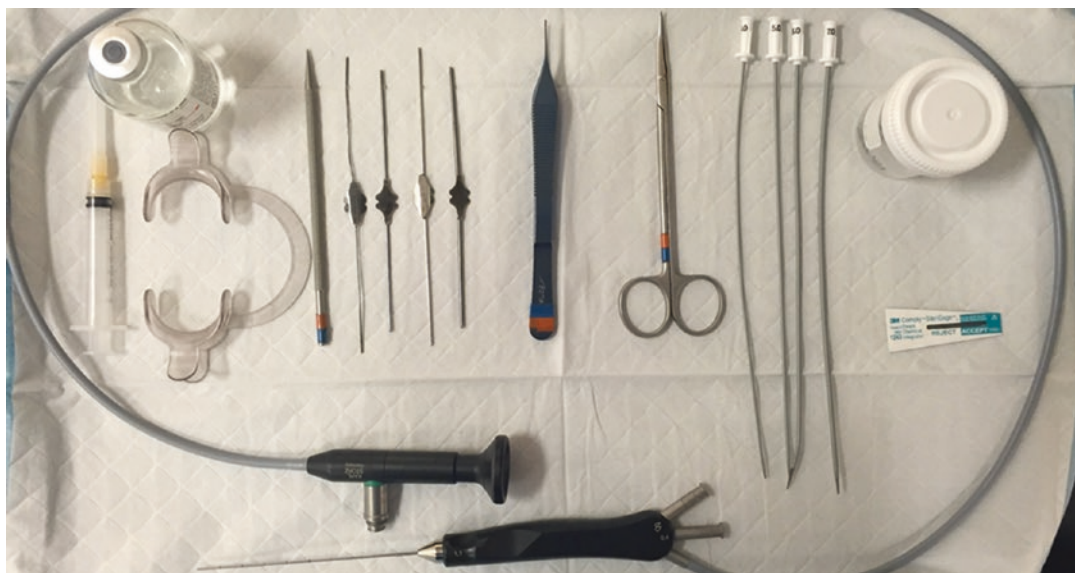

Fig. 4.1 An image of the table setup for office-based sialendoscopy

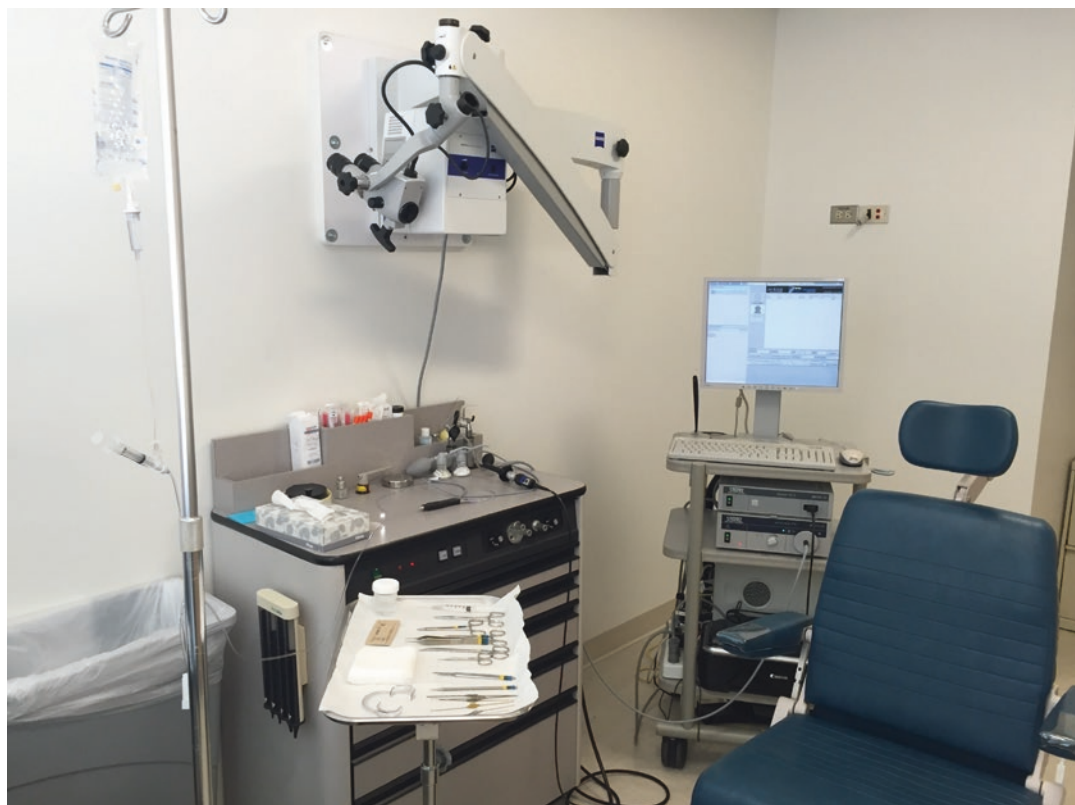

Fig. 4.2 The procedure room arrangement for office-based sialendoscopy

and localize sialolithiasis. Mobile stones can be identified as such, and large, adherent stones can be triaged for fragmentation or sialendoscopy under general anesthesia. Ductal dilations associated with stenoses are easily seen on ultrasound, and dilation under direct visualization can be planned.

Visualizing the pathology associated with patient's symptoms also enables the surgeon to counsel the patients on the precise intervention planned, whether that be retrieval of a stone or ductal dilation.

Following sialendoscopy, treatment success can also be imaged with ultrasonography. Specifically, ultrasound can be immediately used to successfully identify retained stones in the case of transoral sialolithotomy, as during a combined approach, permitting re-exploration as necessary. Stenoses can be followed after ductal dilation, sialolithiasis can be surveilled, and gland parenchyma is easily imaged without invasive procedures.

Papilla

The most frequent difficulty encountered in sialendoscopy, especially in the early stages of its utilization, is cannulation of the parotid or submandibular papilla. Even with experienced operators, difficulty is experienced in up to 15% of sialendoscopies [10]. This is particularly important in bedside sialendoscopy, as rapid intraductal access and expeditious intervention is vital to patient comfort and cooperation.

When identifying the Wharton's or the Stensen's duct, a submucosal 1% lidocaine injection can be invaluable. Submucosal lidocaine injection in the region of the papilla can also change the angulation of Wharton's duct, making the duct more vertically oriented and enabling more rapid cannulation (Fig. 4.3). Additionally, submucosal injection can make the region of the papilla firmer allowing for easier instrumentation of the region.

The papilla is then dilated with a conical dilator and can be cannulated with a 22G angio-

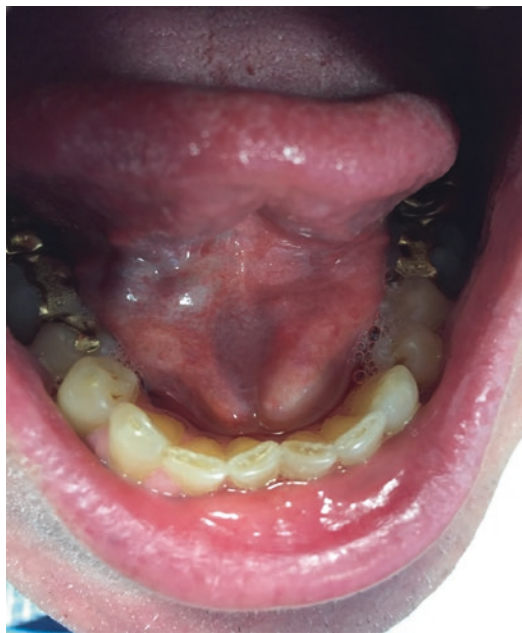

Fig. 4.3 Left submandibular papilla after injection with lidocaine in preparation for dilation of the papilla

cath. Currently available guide wire and dilator systems, utilizing the Seldinger technique, may also be used to cannulate both the parotid and submandibular ductal systems. This enables an atraumatic identification of the duct. Once the ductal opening is identified, serial dilation can be performed. This minimizes trauma and maximizes efficiency of movement. The senior author rarely dilates to above a 6 Fr, as adequate access for most procedures can be obtained using a 5 Fr dilator.

Loupe or microscopic visualization of the duct is a simple, quick adjunct to papilla visualization. Without any added time and with the minimal addition of equipment, the papilla can be localized. This equipment is easily found in most otolaryngology offices. When needed, the author uses 2.5×–3.5× loupe magnification or the in-office microscope.

The first step in localizing the papilla, after direct visualization with or without magnification, is massaging the gland to express saliva. This is frequently successful, but the caruncle is sometimes hard to visualize given the translucent

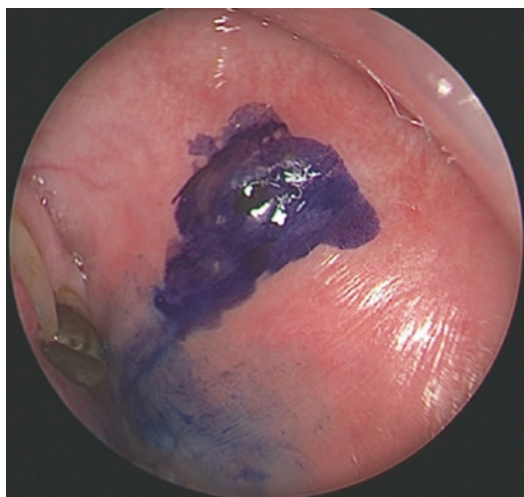

Fig. 4.4 Painting the papilla with methylene blue can often assist in the identification of the ostium

appearance of the saliva and the reflective nature of well-hydrated mucosa. This is especially difficult in edematous ducts, angulated ducts, or in patients with xerostomia. In these difficult cases, methylene blue can be used to paint the region of the caruncle (Fig. 4.4). As the gland secretes even modest amounts of saliva, the dye will smear around the opening. A washout effect can eventually be seen, with a clearing of dye surrounding the papilla.

In individuals who produce little saliva with gland massage or those suffering from xerostomia, administration of vitamin C/citric acid orally can significantly augment salivary flow in the ductal system. Encouraging salivation is valuable in identifying the papilla and can aid in visualization of the ductal system of the parotid and submandibular glands during ultrasound examination [11].

Local Anesthesia

Local anesthesia is of particular importance in office sialendoscopy and aids in patient cooperation and comfort. The first step in local anesthesia is application of topical cetacaine spray to the mucosa surrounding the papilla. After allowing a few moments for the cetacaine to take effect,

dilation of the duct is performed either using a tapered conical dilator or the salivary ductal dilator system. Once dilated to an adequate level, the dilator or the 22G angiocath is left in place and 4% viscous lidocaine is instilled through the lumen, and the glandular system left filled for several minutes to provide a sufficient “depth” of anesthesia.

If dilation of a stenotic segment or extraction of a large stone is planned, local injection can also be given percutaneously under ultrasound guidance. In these cases facility with ultrasound can be tremendously helpful to not only help localize the pathology transcutaneously, but also help with local anesthesia.

Sialolithiasis

Sialolithiasis is the most common etiology of sialadenitis and has a prevalence of 1/15,000–1/30,000 individuals per year [2]. Sialoliths are made of calcium carbonate and phosphate, with variable organic components. The exact sequence of events leading to sialolithiasis is unknown; however the suspected sequence of events is thought to involve intracellular calculi excreted into the ductal lumen which act as a nidus for stone formation [12]. Multiple sialoliths are common and occur in approximately 60% of the cases of parotid sialolithiasis and 30% of the cases of submandibular sialolithiasis.

Sialendoscopy is effective in both the diagnosis and treatment of sialolithiasis, and the indications for in-office sialendoscopic diagnosis and intervention in salivary stones are identical to those of operative sialendoscopy. Diagnostic sialendoscopy is a vital adjunct in the imaging of suspected sialolithiasis and when used in conjunction with ultrasonography can identify and endoscopically extract stones as large as 5–7 mm in both the parotid and submandibular ducts [2, 13, 14]). Contraindications to in-office sialendoscopic extraction of sialoliths include stones too large to extract only endoscopically (generally greater than 5 mm), patient intolerance to exam, and anatomic difficulties.

Ductal Stenosis

Ductal stenosis of the parotid duct, and less frequently the submandibular ducts, is an underrecognized cause of recurrent sialadenitis. Ductal stenoses have been found to cause 15–25% of sialadenitis without identified stones [15, 16]. Ductal stenoses are more frequent in the parotid duct (75%) than in the submandibular ductal system (25%) [15, 17].

Again, the indications of office-based sialendoscopy for ductal stenoses are identical to those of operative sialendoscopy. Office sialendoscopy is particularly useful in this patient population, as repeated dilations and surveillance of stenosis are frequently necessary. Contraindications to sialendoscopy under local anesthesia include Koch grade 4 narrowing (complete stenosis), as these frequently require percutaneous access of the proximal, dilated ductal system.

Diagnostic Staging

Several ductal stenosis classification systems have been described [15, 17, 18].

The Marchal classification system of stones classifies the sialoliths based on its size, mobility, and visibility within the duct (Table 4.1). This system seeks to stratify the stones based on ability to intervene endoscopically, as large, fixed, partially visualized stones are predicted to be the most difficult to extract endoscopically.

The Marchal classification of ductal stenoses groups stenoses based on both anatomic characteristics and amenability to particular interventions (Fig. 4.5). Diaphragmatic stenoses (S1) are easily dilated by any method and

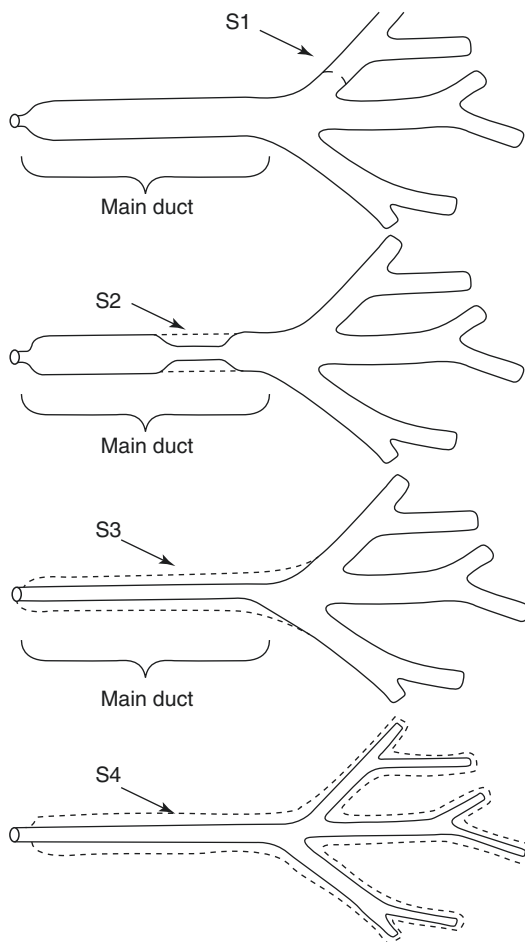


Fig. 4.5 Classification of extent of ductal stenosis (S) using the Marchal classification

ses (S1) are easily dilated by any method and may be multiple. As their title suggests, these stenoses are thin and membranous. Stenoses of the main duct (S2) require more force to dilate and may require repeated dilations. Multiple, thick stenoses and diffuse ductal stenosis (S3, 4) are progressively more problematic to treat and very frequently require repeated interventions [17].

The Koch classification of stenoses is associated with increased recurrence, increased frequency of sialoceles, and increased severity of symptoms in type II stenoses and fewest recurrences in type I or “inflammatory” stenosis (Table 4.2). Koch type III stenoses are associated with the greatest amount of luminal narrowing

Table 4.1 Description of salivary duct stones with the Marchal classification

Score	Findings
L0	Duct free of stones
L1	Floating stone
L2	a Fixed, visible stone smaller than 8 mm
	b Fixed, visible stone larger than 8 mm
L3	a Fixed, partially visualized stone, palpable
	b Fixed, partially visualized stone, nonpalpable

Table 4.2 Description of ductal stenosis using the Koch classification scheme

Grade	Description
1	Passable with 1.1 mm endoscope
2	Passable with .8 mm endoscope
3	Not passable with .8 mm endoscope
4	No visible lumen

Type	Description
1	Inflammatory
2	Fibrous webbed
3	Fibrous circumferential

Koch et al. [18]

and highest rates of recurrence. Regardless of stenosis type, over 30% of stenotic ducts may require repeat sialendoscopy [18].

RAI Sialadenitis

Radioiodine-induced sialadenitis is the most common sequela of radioiodine administration for malignant thyroid disease and can lead to chronic xerostomia, mucoid saliva, and ductal strictures. RAI-induced sialadenitis occurs in approximately 20% of patients, more frequently in the parotid ductal system (90%). RAI-induced sialadenitis is caused by the concentration of I131 in the striated ducts of the salivary glands by the ATP-dependent Na/I cotransporter, causing damage to the surrounding duct and acinar cells [19]. The damage caused by I131 is dose dependent, with more severe symptoms and increased frequency of RAI-induced sialadenitis with higher doses of I131. There are two peaks in the incidence of RAI-induced sialadenitis [20]. The early form of RAI-induced sialadenitis develops in the first 48 h after treatment, is bilateral, and resolves with conservative treatment in 10–14 days. The second “late” peak in RAI-induced sialadenitis occurs 3–6 months following treatment and is obstructive in nature [21]. This “late” RAI-induced sialadenitis is characterized by plaque formation, strictures, mucoid saliva, mucus plugging, and recurrence. The traditional treatment of RAI-induced sialadenitis has been conservative with NSAIDS, steroids, pilocarpine, sialogogues, and gland massage.

Recently, however, sialendoscopy has been increasingly used to dilate stenoses and irrigate affected glands.

Sialendoscopy is a valuable treatment modality in RAI-induced sialadenitis, and indications for office-based sialendoscopic intervention remain identical to operative sialendoscopy. Literature has shown that RAI-induced sialadenitis improves significantly in both subjective and objective measures following sialendoscopy [19, 22]. The clinician has the ability to both diagnose and treat each pathology associated with RAI-induced sialadenitis. Affected glands are irrigated with intraductal steroids, mucus plugs are dislodged and flushed, and stenoses can be dilated. Patients with recurrent symptoms, although rare, can be treated with repeated dilations of strictures, steroid, and/or antibiotic irrigation.

Sjogren’s Syndrome

Sjogren’s syndrome is a progressive autoimmune disease characterized by chronic inflammation and damage to the exocrine glands. Sjogren’s syndrome affects all mucosal surfaces, most commonly resulting in xerostomia and xerophthalmia. Four of six positive diagnostic signs are required for diagnosis of Sjogren’s syndrome, including biopsy of the minor salivary glands, xerostomia, xerophthalmia, decreased lacrimal gland function, decreased salivary function, and the presence of anti-SSA and anti-SSB antibodies. The parotid gland is the most commonly enlarged gland, while the submandibular gland is sometimes involved. Discomfort and xerostomia in Sjogren’s syndrome are caused by chronically decreased salivary gland output due to ductal debris, thickened saliva, and ductal stenosis with subsequent retrograde bacterial infection [19, 23].

Conservative treatment of xerostomia, swelling, and pain associated with Sjogren’s syndrome is first done with “palliative” agents such as artificial saliva, secretagogues, and disease-modifying drugs like steroids and sex hormones. With acute bacterial infection, antibiotics and glandular massage attempt to remove ductal debris. The role of

sialendoscopy in Sjogren's syndrome is to delay or prevent parenchymal loss by removing ductal debris, dilate stenosis, and irrigate with steroids. Subjective symptoms are improved after sialendoscopy; however no objective improvement in salivary flow has been shown. The most frequent findings on sialendoscopy in Sjogren's syndrome are thick, mucoid saliva, obstructing ductal debris, and ductal stenoses [23]. Repeat sialendoscopies are frequently necessary, as Sjogren's syndrome is a progressive disease. Office sialendoscopy is an important intervention in Sjogren's, as it allows preservation of salivary flow without the additional burden of general anesthesia.

Juvenile Recurrent Parotitis

Juvenile recurrent parotitis is the most common inflammatory disorder of the salivary glands in children in the United States and the second most common inflammatory disorder of the salivary glands worldwide to mumps [24, 25]. Juvenile recurrent parotitis features non-obstructive, nonsuppurative, recurrent parotitis. The peak age of onset is typically between 3 and 6 years, and recurrent episodes can continue until puberty. The traditional treatment regimen of JRP has included NSAIDS, antibiotics, sialogogues, and warm compresses. This regimen, while effective on acute episodes, does nothing to decrease recurrence of symptoms [24]. The characteristic sialendoscopic findings in juvenile recurrent parotitis include whitish ductal walls without vasculature, less frequent fibrinous debris. Sialendoscopy with steroid and/or antibiotic irrigation has recently been shown to be effective in decreasing recurrence [24, 25].

The pediatric population poses unique challenges for office-based sialendoscopy, as patient tolerance and cannulation of the pediatric papilla are of paramount importance. Literature has shown there is no clinically significant difference in the size of the pediatric papilla or duct [25]. To further aid in rapid cannulation of the duct, the characteristic appearance of the papilla in juvenile recurrent parotitis is widely

patent [26]. In appropriately selected children over 8 years old, office sialendoscopy with irrigation and dilation is an excellent option to decrease recurrence in JRP and avoid the risks of general anesthesia.

Contraindications

While office sialendoscopy is an excellent diagnostic and treatment modality in salivary gland diseases, there are certain specific contraindications to its use. The primary impediment to office sialendoscopy is inability to access the duct. Multiple factors may contribute to difficulty in access.

Severe trismus is a significant obstacle in office sialendoscopy, particularly when attempting to cannulate Wharton's duct. When range of motion is limited by pain, the patient may be premedicated with oral analgesics to increase mouth opening. When conservative measures are insufficient, however, general anesthesia may be necessary to aid in visualization and cannulation of the duct. In most cases under general anesthesia, sufficient exposure can be obtained with paralytic medication and self-retaining retractors to permit access to the submandibular ductal system.

Difficult oral anatomy is an important but less common contraindication to office sialendoscopy. Acute angulation of Wharton's duct, as can be seen in the case of mandibular tori, can prohibit rapid and comfortable cannulation of the submandibular duct, necessitating the more controlled environment of the operating room (Fig. 4.6).

Mandibular tori may also crowd the floor of the mouth, making access to Wharton's duct difficult or angulating the ducts so that passage of a semi-rigid endoscope is impossible. In some cases, these tori may need to be excised under general anesthesia in order to permit access. In the senior author's experience, office sialendoscopy can be attempted and, if not possible, can be rescheduled for the operating room.

Acute infection is the only strict contraindication common to both operative and office sialen-

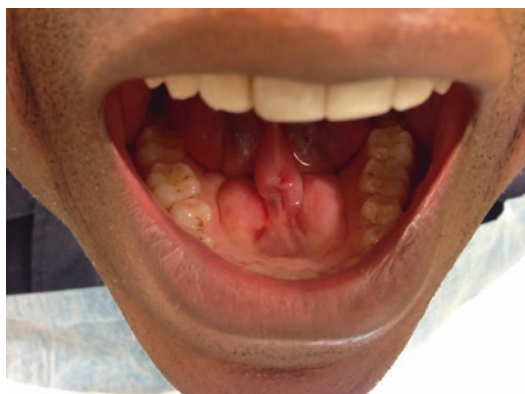

Fig. 4.6 The presence of mandibular tori may result in unsuccessful cannulation of Wharton's duct

doscopy. Edema surrounding the ductal papilla significantly increases difficulty in cannulation, inflammation of the papilla and duct decreases the efficacy of local anesthesia, and regional inflammation narrows the ductal lumen to increase the risk of ductal injury and decrease the utility of sialendoscopy. Additionally, acute inflammation can make the wall of the ductal system more friable, which could lead to perforation of the duct.

References

1. Maresh A, Kutler DI, Kacker A. Sialoendoscopy in the diagnosis and management of obstructive sialadenitis. *Laryngoscope*. 2011;121(3):495–500.
2. Marchal F, Dulguerov P. Sialolithiasis management: the state of the art. *Arch Otolaryngol Head Neck Surg*. 2003;129(9):951–56.
3. Katz P. New method of examination of the salivary glands: the fiberscope. *Inf Dent*. 1990;72(10):785–6.
4. Gundlach P, Hopf J, Linnarz M. Introduction of a new diagnostic procedure: salivary duct endoscopy (sialendoscopy) clinical evaluation of sialendoscopy, sialography, and X-ray imaging. *Endosc Surg Allied Technol*. 1994;2(6):294–6.
5. Nahlieli O, Neder A, Baruchin AM. Salivary gland endoscopy: a new technique for diagnosis and treatment of sialolithiasis. *J Oral Maxillofac Surg*. 1994;52(12):1240–2.
6. Luers JC, Damm M, Klusmann JP, Beutner D. The learning curve of sialendoscopy with modular sialendoscopes: a single surgeon's experience. *Arch Otolaryngol Head Neck Surg*. 2010;136(8):762–5.
7. Modest MC, Galinat L, Rabinowitz MR, Curry JM, Rosen D, Cognetti DM. Learning progression in the use of sialendoscopy for sialolithiasis: effect on gland preservation. *Otolaryngol Head Neck Surg*. 2014;151(2):240–5.
8. Kroll T, Finkensieper M, Hauk H, Guntinas-Lichius O, Wittekindt C. Sialendoscopy—learning curve and nation-wide survey in German ENT-departments. *Laryngorhinootologie*. 2012;91(9):561–5.
9. Zengel P, Schrötzlmair F, Reichel C, Paprottka P, Clevert DA. Sonography: The leading diagnostic tool for diseases of the salivary glands. *Semin Ultrasound CT MR*. 2013;34(3):196–203.
10. Luers J-C, Vent J, Beutner D. Methylene blue for easy and safe detection of salivary duct papilla in sialendoscopy. *Otolaryngol Head Neck Surg*. 2008;139(3):466–7.
11. Bozzato A, Hertel V, Bumm K, Iro H, Zenk J. Salivary simulation with ascorbic acid enhances sonographic diagnosis of obstructive sialadenitis. *J Clin Ultrasound*. 2009;37(6):329–32.
12. Lustmann J, Regev E, Melamed Y. Sialolithiasis: a survey on 245 patients and a review of the literature. *Int J Oral Maxillofac Surg*. 1990;19(3):135–8.
13. Iro H, Zenk J, Escudier MP, Nahlieli O, Capaccio P, Katz P, Brown J, McGurk M. Outcome of minimally invasive management of salivary calculi in 4,691 patients. *Laryngoscope*. 2009;119(2):263–8.
14. Zenk J, M. Koch, N. Klintworth, and B. König. 2012. Sialendoscopy in the diagnosis and treatment of sialolithiasis a study on more than 1000 patients. *Otolaryngol Head Neck Surg*. <http://oto.sagepub.com/content/147/5/858.short>.
15. Koch M, Zenk J, Bozzato A, Bumm K, Iro H. Sialoscopy in cases of unclear swelling of the major salivary glands. *Otolaryngol Head Neck Surg*. 2005;133(6):863–8.
16. Ngu, R.K., J. E. Brown, E. J. Whaites, N. A. Drage, S. Y. Ng, and J. Makdissi. 2014. Salivary duct strictures: nature and incidence in benign salivary obstruction. *Dentomaxillofac Radiol*. 2007;36(2):63–7. British Institute of Radiology. <http://www.birpublications.org/doi/full/10.1259/dmfr/24118767>.
17. Marchal F, Chossegros C, Faure F, Delas B, Bizeau A, Mortensen B, Schaitkin B, et al. Salivary stones and stenosis. A comprehensive classification. *Rev Stomatol Chir Maxillofac*. 2008;109(4):233–6.
18. Koch M, Künzel J, Iro H, Psychogios G, Zenk J. Long-term results and subjective outcome after gland-preserving treatment in parotid duct stenosis. *Laryngoscope*. 2014;124(8):1813–8.
19. Luca D, Roberto MT, Vicidomini A, Colella G, Tartaro G. Endoscopic management of salivary gland obstructive diseases in patients with Sjögren's syndrome. *J Craniomaxillofac Surg*. 2015;43(8):1643–9.
20. Wu C-B, Xue L, Zhang B, Sun N-N, Zhou Q. Sialendoscopy-assisted treatment for chronic obstructive parotitis—our treatment strategy with 31 patients. *J Oral Maxillofac Surg*. 2015;73(8):1524–31.
21. Prendes BL, Orloff LA, Eisele DW. Therapeutic sialendoscopy for the management of radioiodine sialadenitis. *Arch Otolaryngol Head Neck Surg*. 2012;138(1):15–9.

22. Wu C-B, Xi H, Zhou Q, Zhang L-M. Sialendoscopy-assisted treatment for radioiodine-induced sialadenitis. *J Oral Maxillofac Surg*. 2015;73(3):475–81.
23. Jager DJ, Karagozoglu KH, Maarse F, Brand HS, Forouzanfar T. Sialendoscopy of salivary glands affected by Sjögren syndrome: a randomized controlled pilot study. *J Oral Maxillofac Surg*. 2016;74(6):1167–74. doi:[10.1016/j.joms.2015.12.019](https://doi.org/10.1016/j.joms.2015.12.019).
24. Canzi P, Occhini A, Pagella F, Marchal F, Benazzo M. Sialendoscopy in juvenile recurrent parotitis: a review of the literature. *Acta Otorhinolaryngol Ital*. 2013;33(6):367–73.
25. Ramakrishna J, Strychowsky J, Gupta M, Sommer DD. Sialendoscopy for the management of juvenile recurrent parotitis: a systematic review and meta-analysis. *Laryngoscope*. 2015;125(6):1472–9.
26. Konstantinidis I, Chatziavramidis A, Tsakirpoulou E, Malliari H, Constantinidis J. Pediatric sialendoscopy under local anesthesia: limitations and potentials. *Int J Pediatr Otorhinolaryngol*. 2011;75(2):245–9.

Part II

Management of Obstructive Salivary Disorders

Barry M. Schaitkin and Rohan R. Walvekar

Key Points

1. Stones are more common in the submandibular gland than the parotid and represent 50% of all obstructive pathology.
2. Stones may start as microliths or be secondary to trauma, bacteria, or foreign bodies.
3. Ultrasound and CT are most commonly used to evaluate for stones.
4. Salivary endoscopy can address most small stones in a minimally invasive way. Larger stones may require other modalities combined with endoscopy.

Epidemiology

The incidence of parotid stones is reported to be approximately 1 in 20,000, with some reports of stones in autopsy material of up to 1% [1]. In the parotid gland, it is the second most common reason for salivary swelling after mumps. The etiology of salivary stones has not been com-

pletely determined. Research by Dr. John Harrison and others has concentrated on the formation of microliths. These can be found in normal glands and then serve as the nidus for the formation of sialoliths. In animal models, the incidence of microliths increases when salivary flow is obstructed [2]. Another theory is that trauma, bacteria, or foreign bodies act as the initial nidus.

Clinical Presentation

Patients with parotid stones primarily present with intermittent mealtime symptoms. When salivary demand increases, the stones which are usually in the duct over or anterior to the masseter at presentation cause obstruction of flow, swelling, and discomfort [3]. Stones are therefore symptomatic when they reach a point that they block a significant portion of the ductal lumen where they reside. The parotid duct has been estimated to be about 1.5 mm in diameter at its widest part [4]. Patient's stones may reach significant size with few symptoms and then present with an acute more dramatic infection. Intermittent obstruction leads to infection and stricture formation as well. One theory of stone formation suggests that recurrent bouts of salivary gland inflammation lead to the formation of inflammatory microliths that coalesce into symptomatic stones (Fig. 5.1).

B.M. Schaitkin, M.D. (✉)
Department of Otolaryngology—Head and Neck
Surgery, University of Pittsburgh Medical Center,
Pittsburgh, PA 15232, USA
e-mail: schaitkinb@upmc.edu

R.R. Walvekar, M.D.
Department of Otolaryngology—Head and Neck
Surgery, Louisiana State University,
New Orleans, LA, USA

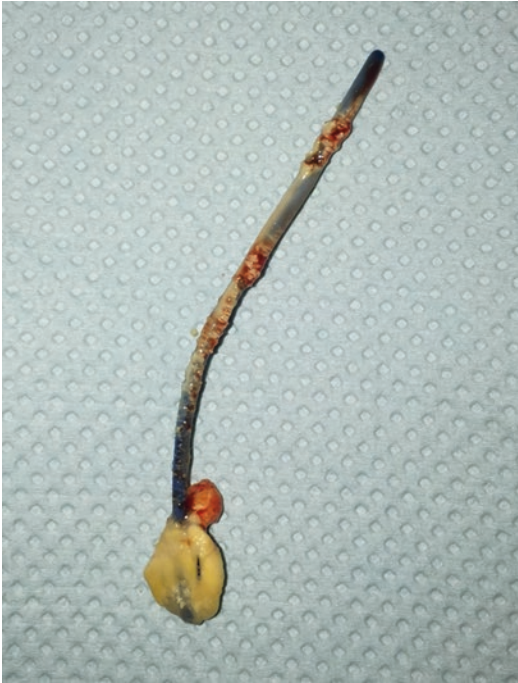

Fig. 5.1 This is a stent from a patient who was lost to follow-up and had it retained for many months. It is covered with new mini stones, demonstrating the principle of microlith formation from a foreign body nidus

Testing

History is the most important feature of salivary inflammatory disease. For stone patients, 80% of them are in the submandibular gland (see Chap. 7). The choice as to what radiographic investigation is best varies among practitioners.

Ultrasound (US)

The noninvasive, readily available, and inexpensive nature of this technique has led to US becoming a major investigative tool in patients with salivary complaints. Increasingly, surgeons have these devices in their offices and can use them as a natural extension of their physical examination. In Europe, residency training in US is becoming a requirement for certification, and it is reasonable to assume that US will shortly become an integral part of residency training in the United States as well.

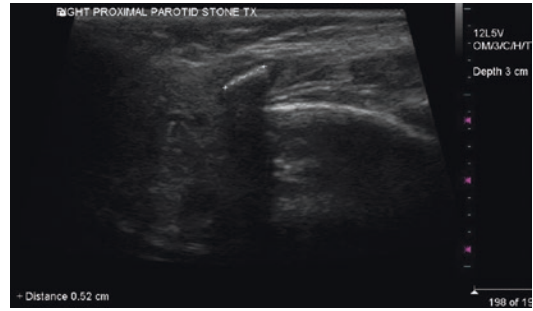

Fig. 5.2 Ultrasound image of right proximal parotid stone (5.2 mm); stone casts a typical distal acoustic shadowing

Terraz found the overall sensitivity, specificity, accuracy, and positive and negative predictive values of sonography in the detection of calculi were 77, 95, 85, 94, and 78%, respectively. Most importantly, false-negative sonographic findings were associated with calculi with a diameter less than 3 mm in non-dilated salivary ducts; most calculi with a diameter of 3 mm or greater were correctly identified. False-positive findings were caused by ductal stenosis with wall fibrosis, which was erroneously interpreted as lithiasis [5]. If US shows a stone, it is likely to be there with a high positive predictive value (94%) (Fig. 5.2). The absence of a stone might be because it is small. In that case the authors of the paper suggest proceeding with an MR sialogram if the likely suspicion for a stone is low and a conventional sialography if the likelihood of a stone is felt to be high. Our institutional preference is to obtain a non-contrast CT scan in these situations instead.

Computerized Tomography (CT)

CT scan is superior at detecting salivary stones but relatively poor at looking at ductal dilatation. It is able to detect stones as small as 1 mm, and below this size, they are rarely symptomatic (Fig. 5.3). It has as a disadvantage the exposure to radiation. Cone beam CT has also been used, and it is less expensive with less radiation exposure.

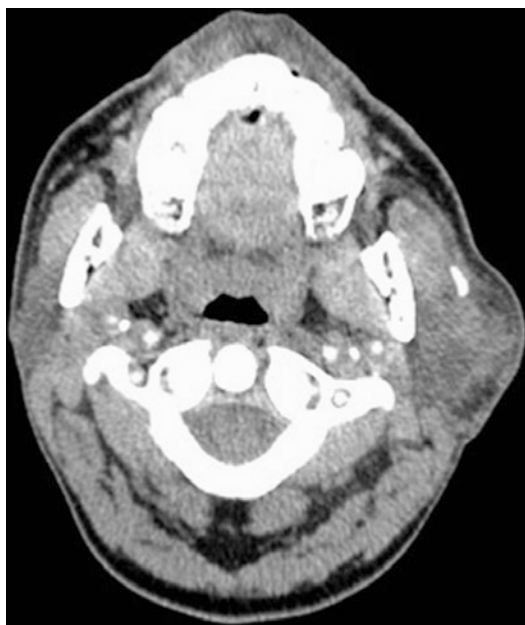

Fig. 5.3 Computerized tomography demonstrating dense stone with significant parotid inflammatory changes in the left parotid gland

MRI Sialography

This technique is not universally available, but it has been well described in the literature.

The sensitivity, specificity, and positive and negative predictive values of MR sialography to detect calculi were 91, 94–97, 93–97, and 91% [6].

Conventional Sialography

Although the technique is not as popular as it once was, it does have a role in the management of small parotid stones and other salivary pathologies. An excellent resource to understand the role and technique of sialography for the diagnosis and management of nonneoplastic salivary gland disorders is the Iowa Head and Neck Protocol, an effort spearheaded by Dr. Henry T. Hoffman. <https://iowaheadneck-protocols.oto.uiowa.edu/display/protocols/Sialograms+and+Sialography>

Nonsurgical Therapy

Lithotripsy has a long history in the treatment of salivary stones. Its main advantages is that it is noninvasive and outpatient, requires no anesthesia, and has relatively few complications. The technique is NOT currently FDA approved in the United States. Iro et al. reported on minimally invasive treatment of salivary stones in five centers in 4691 patients. Only 78 patients had parotid stones treated in this manner. Since multiple centers were involved, they used more than one manufacturer's technology. The duration of each session was usually 1 h. The number of shock waves delivered during each session varied between 3000 and 5000. The outcome was assessed clinically and by ultrasound or sialographic evaluation, or both, 3–6 months after completion of treatment. Parotid stones were successfully treated in 70% and partially successful in 25% with <5% requiring gland removal. Submandibular cases had a lower rate of complete success. Long-term reports of lithotripsy have placed permanent complete response to treatment at 40% [7].

Surgical Therapy/Results/Complications

Sialolithotomy

Direct sialolithotomy has traditionally been done for stones presenting at the papilla. Large palpable stones that are too large for simple endoscopy can be addressed by a transoral approach as well. The stone must be palpable. It is possible that long-standing stones with proximal dilation can fall back toward the hilum of the parotid gland during this manipulation making transoral removal difficult. A papilla sparing approach can also be used to facilitate removal of stones either proximal to the papilla or distal to the anterior border of the masseter muscle. This procedure involves making a curvilinear incision or circular incision around the papilla and accessing the duct in the buccal space (Fig. 5.4). The stone is identified within the duct in the buccal space and

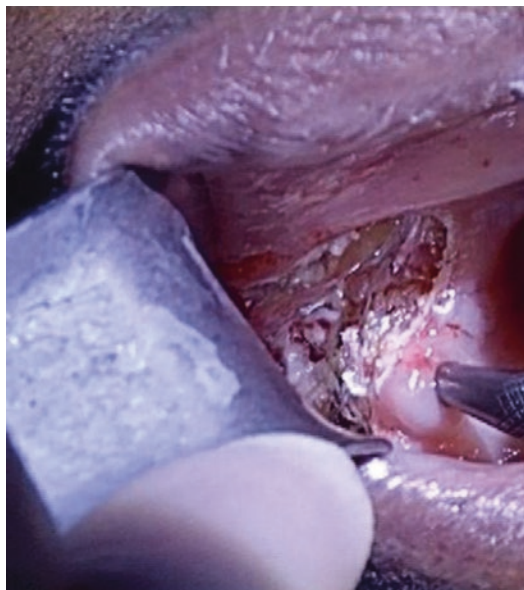


Fig. 5.4 Transoral approach to salivary stone in right parotid not amenable to simple endoscopic removal. Curved incision allows exposure of the duct in the buccal space

delivered via a longitudinal sialolithotomy. After stone removal, a salivary endoscopy to check for complete stone removal and facilitate stent placement and repair of the duct is performed (Fig. 5.5). The major potential complication is stenosis related to the surgical incision which may be reduced by stenting the repaired duct (Fig. 5.6).

Salivary Endoscopy

Salivary endoscopy has emerged as a minimally invasive approach for stones of the parotid and submandibular gland. It can be performed purely under local anesthesia where local anesthetic is administered intraluminally via the salivary endoscope after initial dilation of the papilla that often requires no anesthesia or just a topical anesthetic; alternatively, it can also be performed under monitored anesthesia care. More complex cases lend themselves to general anesthetics in an operating room setting. A decision to perform local, monitored anesthesia or general anesthesia rests upon several factors

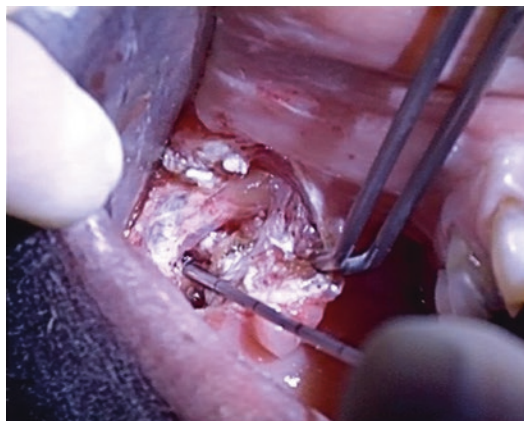


Fig. 5.5 Passage of salivary endoscope through an opening in distal Stensen's duct

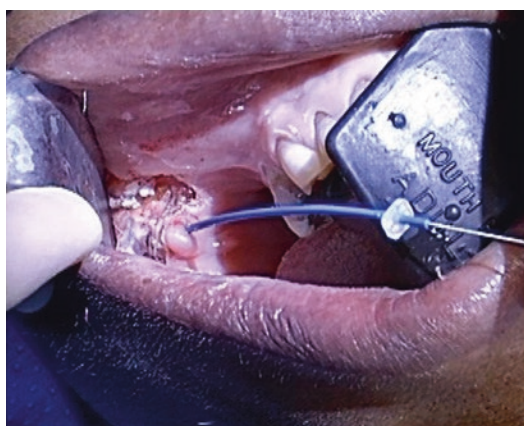


Fig. 5.6 Placement of a stent over a guidewire into Stensen's duct. Many surgeons have found that stent placement for 1–2 weeks reduces the probability of a ductal stenosis

such as patient comfort, surgeon experience and comfort, office-based infrastructure, patient factors (such as age, comorbidities, previous salivary surgery), and indication for the procedure. The ideal case is a mobile, small stone that can be captured in a stone basket and delivered with no incision or a small papillotomy (Fig. 5.7). The size of the stone is not an absolute when building an algorithm for stone removal [8]. Walvekar et al. found that small, round stones could be more difficult to remove with stone baskets than larger more oblong stones. Each scope has only certain baskets that will fit in the working channel. In order to deploy the best

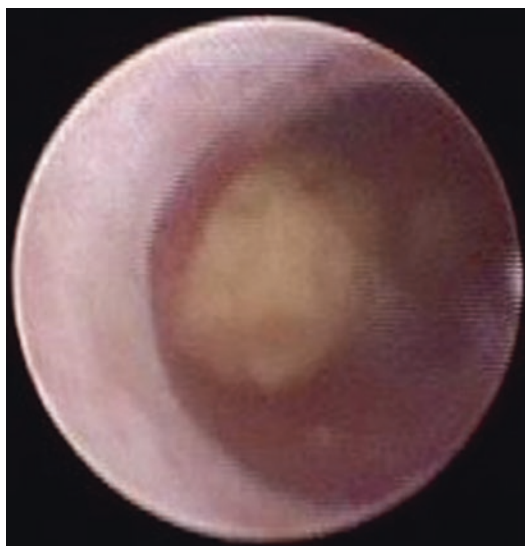


Fig. 5.7 A mobile stone as visualized on salivary endoscopy is usually amenable to endoscopic basket removal

basket, it is necessary to know the basket to scope options and to have an array of scopes available to perform the case. Potential complications include duct rupture, duct avulsion, traumatic stenosis, failure to remove a stone, and stone recurrence (about 5%).

Medium-sized round stones (4–7 mm) will most commonly require fragmentation to allow extraction. The only option in the United States is the holmium laser which is similar to what is in use in urologic stone surgery [9]. Small fibers fit easily through the working channels. It is imperative to be trained in the use of the laser and to exercise caution. The holmium laser is used primarily since it is a contact laser; however, it is still possible to injure or perforate the duct wall with the laser energy. The cases sometimes need to be staged as irrigation and laser energy will lead to duct swelling and make the procedure less safe. Stones are of a variety of densities requiring different power setting, but in general, one can start at 5 Hz and 0.5 J per pulse and increase it as necessary. A greater power setting allows more rapid fragmentation but is associated with faster onset of ductal edema due to thermal damage. Lower setting allows a more controlled stone fragmentation but increases operative time.

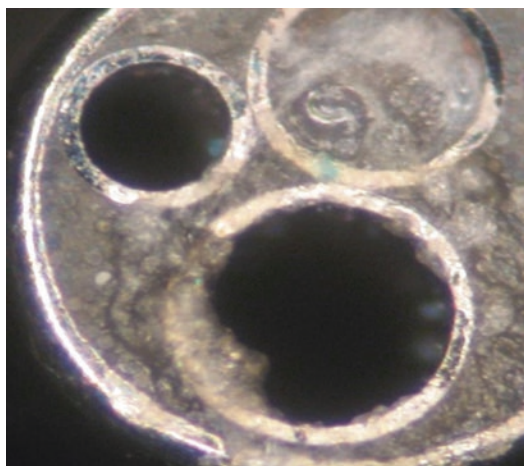


Fig. 5.8 View of salivary scope tip that was damaged by laser use. This changed the scope optics and deformed the working channel

Tremendous care and constant irrigation are required to prevent the duct wall from being injured. In addition, the fragile and expensive scopes can be injured by the stony material that is generated by the laser energy. In order to avoid scope damage, the scope should be kept back as far as possible but with a continued good view. This damage can be either to the optics of the scope or can accumulate in the working channel and prohibit instruments from passing through the tip of the scope (Fig. 5.8).

Salivary Endoscopy with Combined Approach

Stones with size and shape not amenable to laser excision are removed with a hybrid or combined approach. These larger parotid stones can still be managed without parotidectomy. The stone is first localized with a traditional salivary endoscopy. The stone is trapped in a basket if possible to allow for the stone to be fixed in its location. Trapping the stone may also allow the surgeon to “place” the stone in a part of the duct with the easiest external accessibility, generally distal to the gland over the masseter muscle. If it is not possible to deploy a basket because the stone fills the ductal lumen and the basket cannot be deployed, the scope is left in the duct, and the

palpability of the scope and the light facilitate the external ductal incision.

Once the stone is identified, a face-lift parotid incision is generally used. Some cases have been done with a SMALL TRANSFACIAL Incision. The flap is raised as for parotid surgery. A U-shaped flap of SMAS is created lateral to the duct as determined by palpation and/or scope light transillumination. A small incision over the stone with an 11 blade is accomplished and enlarged as necessary with very fine scissors. Care is taken after creation of the SMAS flap to avoid the buccal branch of the facial nerve that travels with the duct. Although this author does not use a nerve monitor, several of the book's editors do this case with a nerve monitor. Success in the parotid gland is over 75% [10, 11]. Complications include stone recurrence, sialocele, facial nerve weakness, numbness, scar, and failure to remove the stone.

Gland Excision

Some patients still require gland excision for salivary stones. These make up <10% of all inflammatory parotid patients. For stone patients they are made up of the following groups:

1. Stones down side channels not accessible to salivary endoscopy
2. Proximal intraglandular stones not amenable to removal with scope
3. Recurrent stones that are multiple and inaccessible
4. Stones with dense stenosis distal to them
5. Surgical failures because of technical issues

Conclusions

Salivary stones are a relatively common cause of obstructive salivary symptoms. Stones larger than 3 mm can be accurately diagnosed with US. Smaller stone patients with a strong history and negative US should be investigated with CT or sialography.

Stone size and shape determine the best method of stone removal. Small stones will come out directly with endoscopy. Medium-sized stone requires external or

laser lithotripsy and fragmentation to allow extraction.

Larger stones can be treated successfully with combined or hybrid approaches. Failure of all techniques will result in a small number of cases that need to have a conventional parotidectomy as definitive therapy. The goal, however, is always to try to take care of the problem with gland preservation in the most minimally invasive way possible.

References

1. Nahlieli O. Classic approaches to sialoendoscopy for treatment of sialolithiasis. In: Witt RL, editor. *Salivary gland diseases: surgical and medical management*. New York: Thieme; 2005. p. 79–84.
2. Triantafyllou A, Harrison JD, Garrett JR. Production of salivary microlithiasis in cats by parasympathectomy: light and electron microscopy. *Int J Exp Pathol*. 1993;74:103–12.
3. Kiringoda R, Eisele DW, Chang JL. A comparison of parotid imaging characteristics and sialendoscopic findings in obstructive salivary disorders. *Laryngoscope*. 2014;124(12):2696.
4. Zenk J, Zikarsky B, Hosemann WG, et al. The diameter of the Stensen and Wharton ducts. Significance for diagnosis and therapy. *HNO*. 1998;46:980–5.
5. Terraz S, Poletti PA, Dulguerov P, et al. How reliable is Sonography in the assessment of Sialolithiasis? *Am J Roentgenol*. 2013;201(1):W104–9.
6. Becker F, Marchal CD, Becker P, et al. Sialolithiasis and salivary ductal stenosis: diagnostic accuracy of MR sialography with a three-dimensional extended-phase conjugate-symmetry rapid spin-echo sequence. *Radiology*. 2000;217(2):347–58.
7. Iro H, Zenk J, Escudier MP, Nahlieli O, Capaccio P, Katz P, Brown J, McGurk M. Outcome of minimally invasive management of salivary calculi in 4,691 patients. *Laryngoscope*. 2008;119:263–8.
8. Walvekar RR, Carrau RL, Schaitkin BM. Endoscopic sialolith removal: orientation and shape as predictors of success. *Am J Otolaryngol*. 2009;30:153–6.
9. Sionis S, Caria RA, Trucas M, et al. Sialoendoscopy with and without holmium: YAG laser-assisted lithotripsy in the management of obstructive sialadenitis of major salivary glands. *Br J Oral Maxillofac Surg*. 2014;52(1):58–62.
10. Walvekar RR, Bomeli SR, Carrau RL, Schaitkin BM. Combined approach technique for the management of large salivary stones. *Laryngoscope*. 2009;119:1125–9.
11. Marchal F. A combined endoscopic and external approach for extraction of large stones with preservation of parotid and submandibular glands. *Laryngoscope*. 2007;117(2):373–7.

Rachel Barry, Barry M. Schaitkin,
and Rohan R. Walvekar

Key Points

1. Gland preservation techniques are associated with lower morbidity, reduced blood loss, better cosmesis, and reduced hospital stays.
2. Gland-preserving surgery incorporates sialendoscopy that can be combined with transoral procedures that allow access or stone removal.
3. An understanding of the anatomy of the floor of the mouth especially the sublingual gland, Wharton's duct, and lingual nerve is vital to being prepared to manage salivary gland stones.
4. Palpable stones in the anterior floor of the mouth can be managed with simple transoral removal.
5. Anteriorly located stones can be treated with sialendoscopy alone.
6. Small and intermediate stones can be treated endoscopically or with lithotripsy. Larger stones or impacted stones will require hybrid techniques.
7. An understanding of how to manage the duct, options and indications for stenting, as well as ability to recognize complications are all important for good outcomes.
8. Large stones with difficult transoral access may benefit from the technological advances provided by robotics.
9. Most importantly, understanding the patient's symptoms and expectations and tailoring the approach to meet these expectations will result in most optimal outcomes.
10. An astute sialendoscopist must always have a high index of suspicion for neoplastic processes which can occur occasionally in sync with nonneoplastic disorders like salivary stones and occasionally present with similar complaints.

Electronic Supplementary Material The online version of this chapter (https://doi.org/10.1007/978-3-319-58335-8_6) contains supplementary material, which is available to authorized users.

R. Barry, M.D. • R.R. Walvekar, M.D. (✉)
Department of Otolaryngology Head and Neck
Surgery, Louisiana State University Health Sciences
Center, New Orleans, LA, USA
e-mail: rwalve@lsuhsc.edu

B.M. Schaitkin, M.D.
Department of Otolaryngology Head and Neck
Surgery, University of Pittsburgh,
Pittsburgh, PA, USA

Introduction

Sialolithiasis is a disease of the salivary gland characterized by the mechanical obstruction of the salivary duct by a calculus. The incidence of sialolithiasis in the general population has been reported to be 1.2% [1]. Salivary stones are most often seen in the submandibular gland (80–90%) as compared to the parotid gland (5–20%). Stone formation in the sublingual and minor salivary glands is very rare.

The predominant prevalence of salivary stones in the submandibular gland can be explained by anatomic factors such as the longer, ascending tract of the submandibular duct, as well as the more alkaline and mucous composition of the saliva, which contains higher concentrations of calcium and phosphate.

Sialoliths can vary in size from less than 1 mm to a few centimeters in diameter. Eighty-eight percent of salivary stones will be less than 10 mm in diameter, with a majority being within 3–7 mm in diameter. In a small percentage of cases, salivary stones will grow to sizes greater than 15 mm. The majority of stones are located in the hilum or proximal duct system (53%), followed by the distal two-thirds ductal system (37%) with only 10% in the intraparenchymal duct system [2]. While small stones sometimes pass out of the duct on their own, larger stones typically remain in the gland or duct until removed.

Historically, surgical treatment for patients with symptomatic sialolithiasis involved papillectomy for distal stones and submandibular gland excision for proximal or intraglandular stones. Although sialoadenectomy is the definitive treatment for obstructive sialadenitis, it is associated with higher rates of complications including permanent nerve damage (marginal mandibular, lingual, or hypoglossal nerves), salivary fistula, sialocele, and aesthetic consequences. It was previously believed that a gland with sialolithiasis becomes nonfunctional. This has been disproved with studies showing a return to normal secretory function following stone removal, as well as normal histologic findings in glands removed for sialolithiasis, further justifying gland-preserving approaches [3].

Sialendoscopy is a technique that allows endoscopic visualization of the submandibular ductal system and facilitates minimally invasive management of stones, thus allowing for gland preservation. The management of salivary stones in the submandibular gland often involves endoscopic and endoscopic-assisted transoral procedures to allow gland preservation.

Clinical Presentation

Salivary stones are the commonest cause of unilateral submandibular gland swelling. The patients can be completely asymptomatic who are diagnosed incidentally during imaging for other diagnoses or can present with the classical symptoms of swelling of the gland during meals. Glandular swelling can be painless or painful. Mechanical obstruction of the submandibular gland can be complicated by bacterial infections resulting in acute sialadenitis with purulent salivary secretions and an enlarged painful gland that can also progress to abscess formation (Fig. 6.1). In most cases, however, patients present with chronic symptoms of intermittent swelling that resolves spontaneously. Consequently, a past medical history of chronic sialadenitis may suggest sialolithiasis. Other histories relevant during initial evaluation include a history of dry eyes and dry mouth that could be associated with Sjogren's syndrome, diabetes mellitus, or dehydration, all of which may predispose the patient to calculus formation. Gout has also been found to be associated with sialolithiasis, in which case crystals will be made up primarily of uric acid.

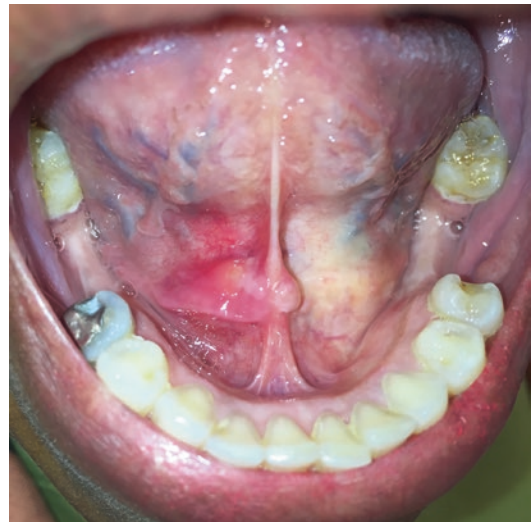

Fig. 6.1 Right submandibular papilla is obstructed with corresponding inflammation of the anterior floor of the mouth with a large distal sialolith and purulent secretion at the papilla

Other relevant history that impacts the management of stones is a history of bleeding disorders, autoimmune diseases, or medications that lower salivary production (see Chap. 1). Tobacco use is shown to be positively correlated with sialolithiasis [3].

Physical Examination

All new patients must have a thorough and complete head and neck examination to rule out a coincidental neoplastic process. Oral cavity examination should include an inspection of all the four salivary duct openings. The submandibular duct can open on the papilla as a singular opening or at times multiple openings. Consequently, the opening of the duct, site, and patency must be documented for easier identification during surgery. Also, if the submandibular papilla is difficult to identify or expression of saliva on ipsilateral gland massage does not produce saliva, this may indicate obstruction of Wharton's duct or papillary stenosis. Accordingly, access to the papilla can be planned accordingly, i.e., the surgeon can have a lower threshold for performing a sialodochotomy during sialendoscopy, if all techniques to identify the papilla have failed. It may also influence the choice of anesthesia for the operation. Bimanual palpation of the floor of the mouth should be performed to identify the location of the stones if palpable, and also posterior floor of the mouth palpation must be performed to assess access to the hilum for management of larger hilar stones via combined approach technique. For stones that are not palpable, an in-office ultrasonography can be helpful to identify stones, gauge mobility of the stones under ultrasound, and localize them with sonopalpation, which is US combined with transoral stone palpation. Tenderness to palpation of the floor of the mouth, erythema, and purulence from the salivary duct all denote an acute suppurative sialadenitis. In the latter situation, active surgical intervention or endoscopic intervention is usually contraindicated as the risk of duct penetration is high during acute infection. Surgery,

open and endoscopic, is usually deferred until the patient's active infection has resolved. Neck examination should also be performed to assess the submandibular gland tenderness, firmness or induration, and size. Obstructed salivary glands may be enlarged, but chronic sialadenitis can also result in atrophic glands. Firm fibrotic glands can be indicative of chronic infection or inflammation. Bilateral gland pathology often points to a systemic etiology, i.e., Sjogren's syndrome, sarcoidosis, or IgG4 sialadenitis.

Imaging

The common imaging techniques used for submandibular stones include ultrasound (US) and computerized tomography (CT) imaging. Plain X-rays or orthopantomograms are fast and noninvasive; however, these often miss intraglandular or small stones; in addition, only 80% of submandibular stones are radiopaque on plain films. The sensitivity for other imaging modalities is higher. Ultrasound imaging can locate stone greater than 2 mm in size. Stones smaller than 2 mm can be missed. There are also certain areas such as the anterior floor of the mouth which are not easily assessable on US, consequently resulting in the possibility of missing pathology. US is helpful not only in clinical diagnosis but also has implications in surgical management, i.e., intraoperative localization of stones via sonopalpation; it is, however, highly operator dependent. Other advantages of US are that it allows avoidance of exposure to radiation, and it is repeatable, inexpensive, and efficient. A study comparing US, sialography, and endoscopy demonstrated sensitivity of 81%, specificity of 94%, and accuracy of 86% for US.

In the United States, US is gaining popularity to diagnose and manage salivary gland disease; however, computerized tomography (CT) scans are probably more commonly ordered to determine salivary gland pathology. The authors recommend CT scan with 1 mm cuts both with and without contrast to evaluate submandibular sialolithiasis. CT imaging is ideal to get a broader

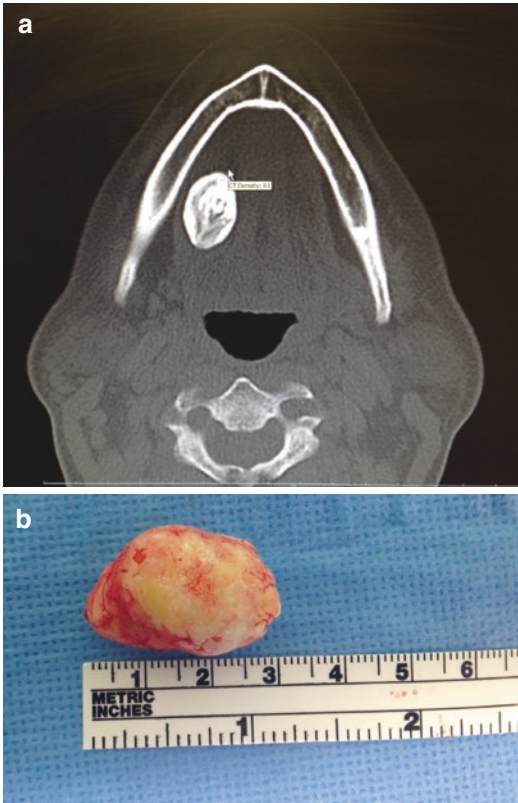


Fig. 6.2 (a) CT scan showing a large right submandibular duct stone with hilar involvement. (b) Right submandibular duct “megolith”

perspective of submandibular stone presentation. CT scans help identify the location, shape, size, and number of stones which may not be readily visible on US (Fig. 6.2). The disadvantage is that the ductal pathology can only be interpreted indirectly, i.e., ductal stenosis or obstruction by proximal ductal dilation. Also, CT images are not dynamic, i.e., stones can move in location from the time when a scan is done to when the patients undergo therapy consequently not providing real-time information on stone location.

Sialography is an excellent imaging tool to determine ductal pathology. Identification of ductal stenosis and extent of stenosis can be determined with sialography. Disadvantages include irradiation, pain associated with the procedure, possibility of ductal perforation, and pushing the stone further proximally in the gland. Also MRI and MRI sialography can provide

valuable information; they are uncommonly necessary for management of submandibular stones. When there is concern regarding the presence of a coexisting pathology, i.e., tumor or autoimmune disease, MRI imaging can be a valuable. MRI sialography consists of 3-mm T2-weighted fast spin echo slices, performed in sagittal and axial planes. Volumetric reconstitution is performed, allowing visualization of the ducts. It is a rapid, noninvasive technique without dye injection and possibility to visualize all major salivary glands; however, cost of the procedure, longer time required for image reconstruction, and difficulty for claustrophobic patients limit the use for routine imaging of submandibular stones.

Indications for Sialendoscopy

Sialendoscopy should be considered in all cases of submandibular sialolithiasis in patients who have obstructive symptoms and for diagnostic evaluation of recurrent unexplained swelling of the submandibular gland associated with meals. Patients with history of recurrent acute sialadenitis with or without abscess formation also qualify for stone removal. Patients diagnosed with sialolithiasis incidentally or who are not particularly symptomatic should be given the option of observation as well. However, pros of this observation protocol, i.e., avoidance of surgical complications and cons, i.e., possibility of recurrent obstructive symptoms, acute sialadenitis, neck abscess, and also loss of ability to offer endoscopic interventions as smaller stones may increase in size (rate of growth 1 mm/year), must be discussed with the patient.

Contraindications to Sialendoscopy

There are few contraindications for sialendoscopy. In patients with medical issues precluding administration of general anesthesia, the procedure can be performed under local anesthesia with sedation. However, some patients may be medically unfit for any invasive procedure and can be observed. Active sialadenitis is a relative contraindication; sialendoscopy is more difficult

in setting of inflammation, and intervention can result in higher changes of ductal injury including perforation and stenosis.

Surgical Techniques for Management of Submandibular Stones

External lithotripsy is an option for the management of sialolithiasis and is discussed in Chap. 5 (Parotid Stones). Our discussion on management of submandibular stones will focus on current philosophies and technical considerations of various gland-preserving techniques for management of the submandibular stones.

The algorithm for stone management as defined by Marchal et al. takes into consideration stone size. Small stones (≤ 4 mm) can be accessed endoscopically, and large stones (≥ 6 mm) can be managed using combined approach techniques or removal after stone fragmentation. Intermediate-sized stones are challenging and often need a combination of endoscopic and open techniques to locate and treat them. Studies have shown that other than stone size, location, shape, and orientation are helpful in determining the likelihood of endoscopic success.

Preoperative Preparation and Considerations

As described earlier a thorough head and neck examination is mandatory prior to intervention in the operating room. Equally important is the importance of the informed consent. Chapter 1 discusses the nuances of examination and evaluation of patient with salivary gland disorders. Discussing the procedure in detail including expectations, complications, need for insertion of stents vs. not, postoperative recovery, and days of work lost are important aspects of preoperative preparation. A discussion with the anesthesiologist to plan endotracheal tube placement is important. If the procedure is being performed under general anesthesia, nasal intubation offers a wider exposure of the oral cavity, but there is a risk of epistaxis. In most cases, especially with experience,

oral intubation will provide adequate exposure and access to the anterior and posterior floor of the mouth. In patients undergoing bilateral procedures, nasal intubation is preferable. Also it's important to avoid anti-sialagogues such as Robinul (glycopyrrolate). Availability of preoperative imaging or access to US for intraoperative intervention should be considered. In patients who are undergoing combined approach or hybrid procedures, external pressure on the submandibular gland is vital in propping up the floor of the mouth contents. In some cases, especially in patients with challenging access to the oral cavity (e.g., obese patients, small mouth opening, tori, or large teeth or tongue), the need for two assistants may be necessary. Consequently, pre-op planning for adequate intraoperative assistance is vital to success.

Operative Planning Issues

Anesthesia:

- General anesthesia or local anesthesia with sedation.
- If performed under general anesthesia, recommend oral or nasal intubation with muscle relaxation for better intraoral access.

Positioning:

- Supine.
- Intraoral and extraoral Betadine prep may be considered.

Perioperative antibiotic prophylaxis:

- Perioperative administration of antibiotics to cover the oral flora is recommended.

Monitoring:

- Routine anesthesia monitoring

Instruments and equipment to have available:

- Head and neck set
- Monopolar and bipolar electrocautery
- Intraoral retractors:
 - Disposable plastic cheek retractors.
 - Jennings retractors, Minnesota retractors, and dental props are all useful in providing intraoral exposure.

- Salivary duct dilators and stent for cannulation of Wharton's duct:
 - Marchal or Schaitkin dilator systems (Karl Storz, Germany)
 - Disposable dilator systems (Cook Medical, USA)
 - Salivary duct stents (Hood Laboratories, Pembroke, MA)
- Sialendoscopy tray
- Sialendoscope(s) and video tower:
 - Most commonly the “all-in-one” interventional endoscopes are favored due to their versatility in diagnostic and interventional procedures.
- Disposable instrumentation:
 - Stone baskets
 - Indwelling access sheaths
 - Laser (holmium) for lithotripsy and laser fibers
 - Pneumatic lithotripter (Cook Medical, USA)

Prerequisite skills:

- Experience with salivary gland and salivary duct surgery

Operative risks:

- Risks of general anesthesia.
- Bleeding.
- Infection.
- Ductal injury, i.e., perforation, avulsion, or scarring (stenosis).
- Stenosis of the papilla.
- Salivary fistula is not a major complication as the salivary fistula into the floor of the mouth is desired. However, in some cases, salivary leak and fistula due to injury of the sublingual duct and gland can lead to post-op sialoceles or ranula formation.
- Lingual nerve injury.
- Inability to remove stone.
- Need for further procedure to remove submandibular gland.

retracting the buccal mucosa; this is especially relevant for submandibular stone management. The retractor tends to block access to the parotid duct and consequently is not as often used for exposure in parotid cases. General anesthesia with oral or nasal intubation is performed. Sedation with local anesthesia can be substituted if preferred or if general anesthesia is contraindicated. Bite block and oral retractors (e.g., Jennings retractor) are placed for adequate intraoral exposure.

Access to the Submandibular Papilla

This is the rate-limiting step for submandibular sialendoscopy. The submandibular papilla is first identified under magnification and then sequentially dilated. Identification is facilitated by preoperative identification and localization of the papilla. Intraoperatively, pressure on the gland externally will allow the papilla to be identified by egress of saliva from the opening. In difficult cases, application of methylene blue to the floor of the mouth can help make the papilla more prominent. Once identified, the papilla can be dilated using a variety of dilating systems and techniques. Most experts advocate a “no-touch” technique, i.e., to avoid using toothed forceps to grab the floor of the mouth mucosa which may create illusions of a papilla by the punctures created and also increase risk of maceration of the papilla. Retraction of the floor of the mouth can be performed bluntly using Q-tips or retractors (finger retraction or metal). Once the duct is cannulated, dilation must be performed of the first 1.0–1.5 cm of the duct opening; more distal introduction of dilators can cause stones to be pushed back toward the hilum or traumatize the duct. In general, dilation should be smooth and atraumatic. If excessive resistance is felt, a stenosis or false passage should be suspected. Dilation techniques essentially include either serial dilation using metal dilators of increasing caliber or dilation over a guide wire, i.e., Seldinger technique using either non-disposable metal or disposable cannulas. After appropriate dilation, the sialendoscope is inserted, and endoscopic localization of the stone is performed.

Surgical Approach and Techniques

Exposure to the oral cavity is obtained using a variety of retractors. Disposable cheek retractors are vital in providing lateral exposure by

In cases where access cannot be obtained using standard dilation techniques, a sialodochotomy and repair of the duct are indicated. This can be performed either by incising the papilla and proximal duct and suturing this to the floor of the mouth or by leaving the natural papilla intact and instead making a sialodochotomy about a centimeter proximal to the natural opening. In the latter alternative, the duct is then marsupialized to the floor of the mouth creating a new opening for the duct; the advantage is that the natural papilla is maintained, and consequently the duct remains tethered anteriorly to the floor of the mouth giving stability to the duct. The disadvantage is the possibility of injuring the sublingual duct opening and increasing the chances of ranula formation.

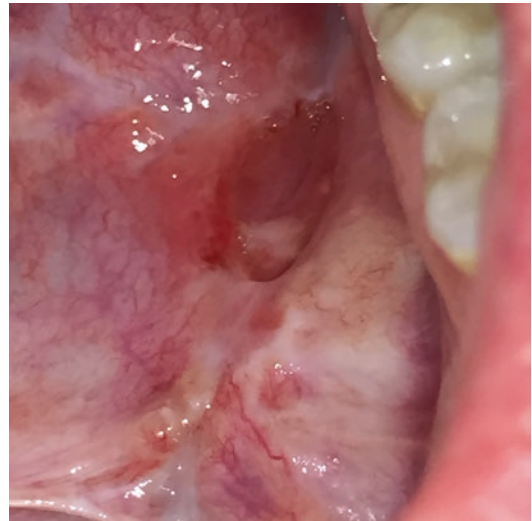

Fig. 6.3 Floor of the mouth duct marsupialization

Anterior Floor of the Mouth Stones or Stones at the Papilla

For stones at the papilla, usually a simple transoral stone removal is adequate. This can be performed in the office or in the operating room under local or general anesthesia, depending on size of stone, palpability of the stone, patient preference, and surgeon comfort. The stone is usually fixed in place using a hemostat or forceps. A papillotomy can be made to release the stone; usually this is followed by egress of obstructed saliva. A small papillotomy usually will heal well without need for stent placement. Flow of saliva serves as a stent in this case; consequently, salivary gland massage, hydration, and sialagogues are important to help prevent papillary stenosis. If additional stones are suspected, a sialendoscopy can then be performed at that time both for diagnosis and treatment.

Anterior floor of the mouth stones impacted in the submandibular duct are also managed in a similar fashion. The position of the stone away from the papilla brings on a few challenges. How do you manage the duct? Is the sublingual gland at risk? Is stent placement necessary? Is an endoscopy necessary? For palpable anterior floor of the mouth stones, if the duct can be accessed, an endoscopy is performed to visualize the stone; in many situations, if the stone is favorable in

orientation, it can either be captured in a basket or with a forceps and retrieved to the level of the papilla, after which a papillotomy is needed to help deliver the stone. If the duct cannot be accessed, then the stone is removed by making a floor of the mouth incision and sialodochotomy (Fig. 6.3).

When endoscopy is possible, it should be performed; even when the stone is impacted in the duct, having an endoscopic view of the stone is helpful both for stone localization and subsequent endoscopy to check for additional stones, fragments, and for stent placement. If the natural papilla and distal duct are normal, stenting after removal of large mid-duct stones can be considered to allow for a more natural flow of saliva. The sialodochotomy is either closed or left to heal around the stent. The floor of the mouth incision is usually closed with interrupted absorbable sutures. However, this is not mandatory, given that the saliva must drain into the oral cavity, the sialodochotomy can be matured to form a second opening for the duct into the floor of the mouth. As mentioned earlier, a side effect of ductal manipulation is ranula formation; patients must be counseled about the possibility for ranula formation and need for additional surgery. In situations where Wharton's duct is widely marsupialized, injury to the sublingual duct is a high probability. Some authors recommend an

elective sublingual gland excision to prevent the complication of future ranula and also to facilitate suturing the duct to the floor of the mouth mucosa by removal of intervening minor salivary gland tissue.

Small- and Intermediate-Sized Stones

Intraductal mobile stones are ideal for endoscopic retrieval. A variety of endoscopic tools can be used to facilitate stone removal, i.e., stone baskets and stone forceps. The intermediate-sized stones provide a unique challenge to the sialendoscopist. These stones are too large to permit endoscopic removal unless they are favorably oriented and too small to be easily palpable in the floor of the mouth and consequently amenable to a combined approach procedure. Often stones within the duct may have a preceding stenosis that must be dilated or managed prior to an attempt at stone removal.

Intermediate-sized stones can either be observed if endoscopic access is not ideal or fragmented to allow piecemeal removal of the stone. These procedures may be lengthy and necessitate multiple passes of the endoscope, dilators, and instruments to permit stone removal. The length of the procedure and manipulation of the papilla and duct may cause ductal edema and injury. Endoscopic indwelling access sheaths can be used to minimize the ductal injury and provide a stable operative channel for intervention.

Fragmentation of the stone can be performed in one of several ways, often depending on the consistency and hardness of the stone. Some stones tend to be more resilient to mechanical pressure than others. The handheld micro-drill and forceps are options where mechanical energy can be used to fragment stones. This is combined with endoscopic retrieval of fragments. The micro-drill is ideally suited for stones at the hilum where the drill can be used to fix stone to the hilar wall to facilitate fragmentation. Stone forceps can be used to crush stones; however, the success of this method depends on the stone integrity and size. Large, spherical, and hard stones are not amenable to being fragmented by

this method. Laser lithotripsy has been used to fragment stones. The Holmium laser, which is a contact laser, is ideally suited for this purpose. However, inherent problems with the use of lasers include line of site view, i.e., the laser fiber can only be used and activated if a clear view of the stone can be obtained. Laser energy although effective in lithotripsy causes lateral thermal damage that can predispose the duct to stenosis. Lower-energy settings allow a more controlled breakdown of stones but also take longer operative time predisposing the duct to edema. In addition, the tip of the laser generates heat that could also damage the salivary endoscope. For these reasons, although effective, laser lithotripsy has been adopted in a limited fashion in most practice setting. Other regulatory hurdles include off-label use of the laser for salivary stones and need for hospital credentialing for the use of holmium laser; the holmium laser is most often used in urologic procedure and has limited ENT indications which sometimes makes it difficult for otolaryngologists to get adequate experience to fulfill institutional credentialing criteria.

Intraductal lithotripsy has been investigated in the past with limited success. However, recent studies with a newer pneumatic lithotripter device have shown promising results for stone fragmentation. The device is coupled with the use of the indwelling operative sheath and a salivary duct irrigator (SialoCath™, Cook Medical, USA) to create an all-in-one system for intraductal lithotripsy, stone fragmentation, and removal of stone fragments.

After complete stone removal in these scenarios, irrigation of the duct with steroid-based solution and stent placement may be a consideration depending on the surgeon's concern for ductal trauma, edema, and post-op stenosis.

Large Hilar Submandibular Stones

Stones that are not amenable to endoscopic removal or fragmentation can be removed from combined approach or hybrid techniques. The principle of these techniques is to use a combination sialendoscopy with open techniques to

facilitate gland preservation. Endoscopic localization is combined with transoral stone removal to guide dissection, perform a check endoscopy after stone removal, and facilitate stent placement if deemed necessary. Ultrasonography can also be a valuable adjunct to stone localization with sonopalpation. If the stone is trapped within a wire basket and endoscopic retrieval is not possible, the procedure can be converted to a combined technique wherein the trapped stone is secure and stable in position within the basket to complement transoral removal. If not trappable, the scope is replaced with a ductal dilator to allow for constant duct localization without risk to the scope from retractors. The understanding of the posterior floor of the mouth anatomy is vital to this technique. The lateral relation of the lingual nerve to the hilum of Wharton's duct as it passes over the nerve is important to visualize three-dimensionally. In some cases, the lingual nerve needs further mobilization and medialization to get a more direct view of the hilar portion of the duct. It is also important to realize the posterior portion of the sublingual gland may obscure the view of the posterior Wharton's duct, lingual nerve, and medial pterygoid muscle and often needs to be excised to provide necessary exposure for sialodochotomy (Fig. 6.4a, b).

An assistant provides elevation of the gland toward the floor of the mouth. An intraoral incision is made in the floor of the mouth over the stone guided by transillumination, palpation of the stone itself, or the stone basket combination. The stone within the duct and the lingual nerve are localized primarily via blunt dissection. With the lingual nerve in view, the duct is incised over the stone and the stone is delivered. Dissection of the stone from the walls of the duct is often necessary to free the stone completely. Extension of the ductal incision may be necessary to deliver a large stone or megalith (≥ 15 mm). It must be borne in mind that the ductal lumen is smaller distally and anterior extensions of the sialodochotomy may lead to subsequent stenosis; stent placement may be reasonable in this is a concern. Similarly, posterior extension of the ductal incision brings the incision closer to the lingual nerve

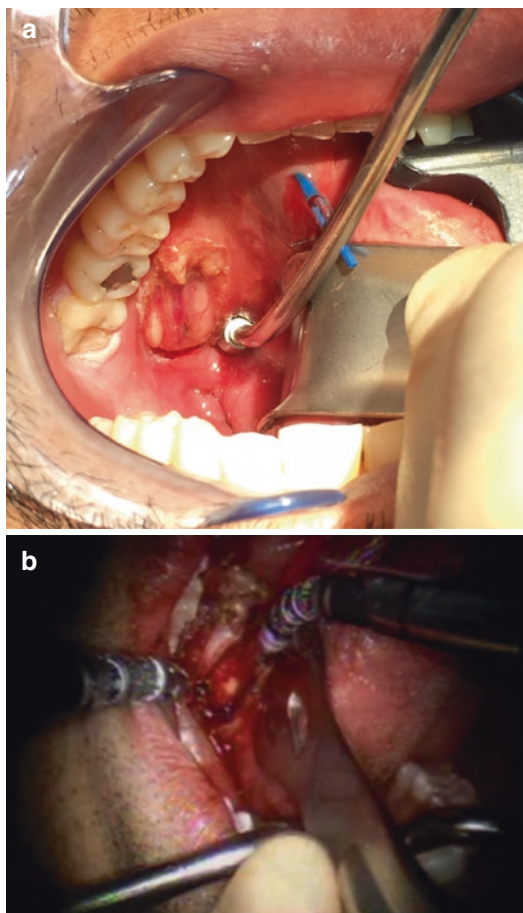


Fig. 6.4 (a) A posterior floor of the mouth incision showing posterior sublingual glandular tissue obscuring the view of the submandibular duct and lingual nerve. This must be excised to visualize the posterior floor of the mouth structures. A 1.2 mm WS stent in place to help localize the duct. (b) End-on view of robot-assisted stone removal showing the relation of the submandibular duct with hilar stone (medially) and lingual nerve (laterally) in the posterior floor of the mouth

as it crosses the duct, and care must be taken to avoid injury to the nerve.

Salivary endoscopy is performed to check for additional stones and to remove stone remnants which will lead to recurrence. The Wharton's duct is repaired or stented when possible. There is no evidence to suggest that a formal repair or stenting of the duct avoids subsequent stenosis and consequently correlates with long-term gland preservation, salivary gland function, or symptom resolution.

Salivary Duct Stenting

Stenting of the salivary duct for the submandibular glands is controversial. Stenting is not evidence based but is usually considered when postoperative ductal stenosis after papillotomy, sialodochotomy, interventional sialendoscopy, or combined approach technique is considered to be possible based on clinical judgment. A variety of existing devices have been modified or used as alternatives for stenting such as infant feeding tubes, angiocatheters, dilators, and access sheaths meant for salivary duct access that are used to fashion stents. Stents specifically designed for short-term intubation of the salivary ducts are also available commercially (Walvekar Salivary Duct Stent, Schaitkin Salivary Cannula; Hood Laboratories, Pembroke, MA) (Fig. 6.5).

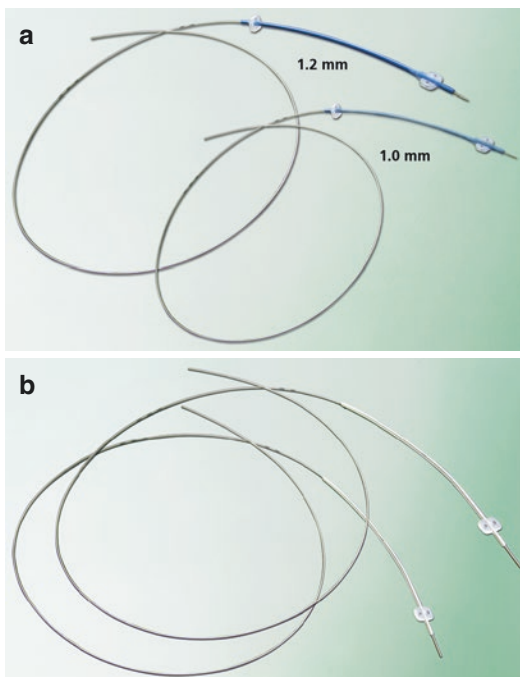


Fig. 6.5 (a) Walvekar Salivary Stent with guide wire (Hood Laboratory, Pembroke MA). (b) Schaitkin Salivary Duct Cannula (Hood Laboratory, Pembroke, MA)

Postoperative Issues

Routine Postoperative Management

The majority of patients who undergo diagnostic and interventional sialendoscopy can be discharged the same day. If there is a concern for postoperative floor of the mouth edema causing airway distress due to extravasation of irrigating fluid, patients can be observed for 23 h or admitted for inpatient observation. In the authors' practice, patients are discharged with the following instructions:

- Half-strength hydrogen peroxide or chlorhexidine rinse 15 mL TID, after meals, to keep clean if there is a suture line.
- In general, postoperative antibiotics are not necessary. However, if a salivary stent is left in place to manage a damaged submandibular duct, a course of postoperative antibiotics for 10–14 days is recommended. The stent is usually left in place for 10–14 days as well.
- Patients with salivary duct stent placement are asked to inspect the stent for loosening or extrusion daily. If there is a concern for stent displacement, the patients are encouraged to contact the treating team. Other instructions include to avoid massage of the gland since the floor of the mouth elevation during gland massage puts tension on stent anchoring sutures and can cause early extrusion of the stent.
- Follow-up visits are scheduled in 1–2 weeks.

Complications and Management

- *Tongue hypoesthesia due to lingual nerve paresis.* The overall incidence of lingual nerve paresis with combined approach techniques is around 20%. This tends to improve over 4–8 weeks, and symptomatically the patients may feel tongue numbness or experience a metallic taste in the mouth.
- *Bleeding/hematoma*
 - Hematoma requires evaluation and control of bleeding to avoid floor of the mouth swelling and potential airway compromise.

- *Postoperative infection*
 - Incision and drainage, culture, antibiotics, and removal of stent if placed.
- *Wharton's duct injury*
 - Salivary fistula. Often physiologic and does not require treatment

Duct perforation. If there is a minor ductal injury during endoscopy, this does not need intervention. Once the injury is identified, irrigation must be stopped, and the procedure is aborted.

In case of a major ductal injury, the procedure is aborted, but due consideration should be given to ductal stenting or marsupialization.

In case of duct avulsion, a rare complication, usually associated with excessive force being used to deliver a stone trapped in the stone basket, the procedure must be aborted, and gland excision will be necessary.

- Stricture or stenosis. Sialendoscopy with dilation and stent placement or submandibular gland excision for recalcitrant cases

Discussion

Marchal categorized as small or large stones based on the maximal dimension of the stone, along its length or width that can safely be removed using an endoscopic technique [3]. Small stones, i.e., stones that are 4 mm or less, that are located anteriorly within endoscopic reach, can typically be removed with sialendoscopy alone. Large stones, i.e., stones that are more than 4 mm in maximal dimension, stones that are unfavorably located, or impacted stones often require a combined approach, which incorporates sialendoscopy and open transoral surgery. This method has been shown to have overall good success rates with minimal complications. A retrospective analysis by Schwartz et al. looked at 49 combined approach cases for submandibular sialolithiasis. The success rate was 87% with symptom control in 76%. There were no significant complications, and gland preservation rate was 95% [4].

Stones larger than 15 mm are called “giant stones” or “megaliths” and are relatively rare in occurrence. Traditional management of these has been transoral sialolithomy for ductal and easily palpable submandibular stones and submandibular gland excision for hilar or intraglandular stones. A case series by Wallace et al. described management of megaliths utilizing a combined approach with improved gland preservation rates [5]. Advantages of this method include visualization and localization of the stone using sialendoscopy, along with facilitated lingual nerve identification by transillumination. Other advantages include the capability to perform sialendoscopy after stone extraction to check for residual stone fragments or additional stones, as well as the ability to irrigate and check the site of repair in cases where salivary duct repair is indicated. Robot-assisted transoral removal has also been described in the case of a hilar-intraglandular submandibular megalith, allowing for excellent visualization of Wharton's duct and the lingual nerve [6].

The authors do not routinely repair or stent the salivary duct after stone removal for submandibular cases, in contrast with parotid cases. The rationale being that if the ductal incision fistulized into the floor of the mouth, it would be physiologic. Short-term follow-up outcomes have been encouraging [3]. A prospective study by Woo et al. investigated anatomic changes to the submandibular duct following transoral excision of hilar stones without sialodochoplasty. Sialography at 3 and 12 months showed good anatomic restoration of flow through the submandibular duct in all but one patient (3%), who developed partial ductal stenosis. This patient was noted intraoperatively to have severe adhesions between the stone and the duct [7].

Lithotripsy has also been described for larger stones or stones difficult to reach endoscopically. External lithotripsy involves several sessions and does not involve extraction of fragmented stones; stones are expected to evacuate spontaneously, but remaining debris can serve as a nidus for further calcification and recurrence of sialolithiasis. In Capaccio's study of 322 patients undergoing extracorporeal electromagnetic shock wave

lithotripsy for submandibular and parotid stones, the stone was completely eliminated in 45%, while 27% of patients were left with residual stone fragments >2 mm in size. Symptom relief was achieved in 88%. Worse outcomes were associated with submandibular stones and stones >7 mm [8]. Various methods of intracorporeal lithotripsy have been described, with laser and pneumatic lithotripsy techniques being the most common. Holmium laser lithotripsy, while effective, can cause adverse thermal effects by reflection of shock wave energy generated by the laser off of the stone, and concerns exist over ductal trauma and stenosis. A study by Schrotzlmaier et al. found that using Ho:YAG laser lithotripsy with energy higher than 500 mJ per pulse was associated with damage to the surrounding tissue [9]. Endoscopic pneumatic lithotripsy using the StoneBreaker lithotripter, which was originally described for use in renal stones, was described in a live porcine model using artificial submandibular calculi, showing effectiveness of the method while avoiding thermal ductal damage [10]. Preliminary studies in a human model have also been favorable [11].

References

1. Walvekar RR, Bomeli SR, Carrau RL, Schaitkin B. Combined approach technique for the management of large salivary stones. *Laryngoscope*. 2009;119:1125–9.
2. Sigismund PE, Zenk J, Koch M, Schapher M, Rudes M, Iro H. Nearly 3,000 salivary stones: some clinical and epidemiologic aspects. *Laryngoscope*. 2015;125:1879–82.
3. Marchal F, Dulguerov P. Sialolithiasis management: the state of the art. *Arch Otolaryngol Head Neck Surg*. 2003;129:951–6.
4. Schwartz N, Hazkani I, Goshen S. Combined approach sialendoscopy for management of submandibular gland sialolithiasis. *Am J Otolaryngol Head Neck Surg*. 2015;36:632–5.
5. Wallace E, Tauzin M, Hagan J, Schaitkin B, Walvekar RR. Management of giant sialoliths: review of the literature and preliminary experience with interventional sialendoscopy. *Laryngoscope*. 2010;120:1974–8.
6. Walvekar RR, Tyler PD, Tammareddi N, Peters G. Robotic-assisted transoral removal of submandibular megalith. *Laryngoscope*. 2011;121:534–7.
7. Woo SH, Kim JP, Kim JS, Jeong HS. Anatomical recovery of the duct of the submandibular gland after transoral removal of a hilar stone without sialodochoplasty: evaluation of a phase II clinical trial. *Br J Oral Maxillofac Surg*. 2014;52:951–6.
8. Capaccio P, Ottaviana F, Manzo R, Schindler A, Cesana B. Extracorporeal lithotripsy for salivary calculi: a long-term clinical experience. *Laryngoscope*. 2004;114:1069–73.
9. Schrotzlmaier F, Miller M, Pongratz T, Eder M, Johnson T, Vogeser M, von Holzschuher V, Zengel P, Sroka R. Laser lithotripsy of salivary stones: correlation with physical and radiologic parameters. *Lasers Surg Med*. 2015;47:342–9.
10. Walvekar RR, Hoffman HT, Kolenda J, Hernandez S. Salivary stone pneumatic lithotripsy in a live porcine model. *Otolaryngol Head Neck Surg*. 2015;154:1023–6.
11. Koch M, Mantsopoulos K, Schapher M, von Scotti F, Iro H. Intraductal pneumatic lithotripsy for salivary stones with the stonebreaker: preliminary experience. *Laryngoscope*. 2016;126:1545–450.

M. Boyd Gillespie

Key Points

1. Salivary duct scar is the second most common cause of obstructive salivary disorders after stones.
2. Multiple different salivary disorders can result in salivary duct scar.
3. Management of salivary duct scar may alleviate obstructive symptoms, but therapy must be directed at the underlying etiology in order to prevent recurrence.
4. Gland-preserving therapy is highly successful for salivary duct scar and is currently the first-line treatment of choice.

Background

Extent of the Problem

Obstructive sialadenitis is the most common benign disease of the major salivary glands, affecting approximately one in 10,000–20,000 of the general population [1]. Blockage of the salivary ducts may be caused by stones, scar,

mucous plugs, and anatomic anomalies in the ductal system, inflammatory polyps, or foreign bodies. Any of these factors may lead to impaired physiologic flow of saliva through the duct, resulting in salivary stasis and glandular inflammation.

Gland preservation surgery utilizing sialendoscopy has been adapted to a wide range of salivary disorders beyond stones. Currently, salivary disorders other than stones constitute 50% of the patient visits for obstructive salivary disorders. The second most common reason for an obstructive salivary disorder other than stones is salivary duct scar which is estimated to contribute to 25% of obstructive cases overall. In patients with obstructive symptoms and negative imaging for stones, ductal scar is found in up to 50–90% of patients who undergo diagnostic sialendoscopy [2, 3].

Like other obstructive salivary disorders, salivary duct scar typically presents with painful swelling of the affected gland, most commonly during meals. This may occasionally result in recurrent bouts of bacterial sialadenitis with fever, glandular swelling, overlying skin erythema, and purulent ductal secretion. Less commonly patients will note increased dry mouth with a reduction in the amount of saliva that they experience. Ductal scar most commonly presents in the parotid gland in 75% of cases. The scar tissue is most often localized to the main duct and ostium.

M. Boyd Gillespie, M.D., M.Sc.
Department of Otolaryngology—Head and Neck
Surgery, University of Tennessee Health Science
Center, 910 Madison Ave., Suite 408, Memphis,
TN 38163, USA
e-mail: mgilles8@uthsc.edu

Etiology of the Salivary Duct Scar

Although salivary duct scar is frequently the proximal cause of obstructive salivary symptoms, the underlying etiology of the scar may be variable. Causes of salivary duct scar include salivary stones, autoimmune inflammation (Sjögren's disease, lupus), infection (viral or bacterial), radioiodine exposure, allergy, ductal reflux, juvenile recurrent parotitis, trauma (external and iatrogenic), foreign bodies, and congenitally small ducts. Occasional changes in the external tissue surrounding the duct can produce kinks that create a functional blockage of the duct [4]. Cases of ductal kinking have been observed after face-lift surgery, external beam radiation, masseteric hypertrophy, and compression from tumors or inflammatory lesions. Knowledge of the underlying cause of the ductal scar will allow application of appropriate medical therapy which may reduce the likelihood of recurrent symptoms and lead to better gland preservation and function in the long term. Salivary duct scar appears to have a female predominance with approximately 60% of cases occurring in women. Although the strong association between autoimmune disorders and female gender may be a factor, the exact reason for this observation is unknown.

Ductal Anatomy and Definitions

In order to recognize narrowing of a salivary duct, the sialendoscopist must first be aware of

the average caliber of normal salivary ducts. In a histologic study of human cadaveric glands, Zenk et al. demonstrated an average diameter of 2–2.5 mm for Stensen's duct and 2.5–3.0 mm for Wharton's duct [5]. The narrowest point for both the parotid and submandibular systems was the ostium, each of which measured only 0.5 mm on average. Although most ductal scar will be found between the ostium and hilum, up to 30% of patients will have scar tissue limited to or extending into the intraparenchymal ductal system [3]. In addition to having normal caliber, healthy ductal walls have a well-vascularized pinkish or salmon hue compared to the whitish, avascular appearance seen with ductal scar.

Based on the collective experience of numerous sialendoscopists, most patients who present with salivary obstruction from scar tissue have main ductal lumens that measure less than 1.5 mm in greatest diameter [6]. Therefore, as a practical consideration, main ducts that are unable to accommodate a standard 1.6 mm scope should be considered narrowed. According to Poiseuille's law, resistance to flow is inversely proportional to the radius to the fourth power. Therefore, narrowing of even a fraction of a millimeter in diameter can result in a magnified resistance to salivary flow. In addition, the fibrotic nature of the scarred duct may also be less responsive to the excretory force of myoepithelial cells and smooth muscle.

Salivary duct scar typically presents as either an area of ductal stricture or a segmental stenosis (Fig. 7.1) [3]. *Strictures* are defined as short

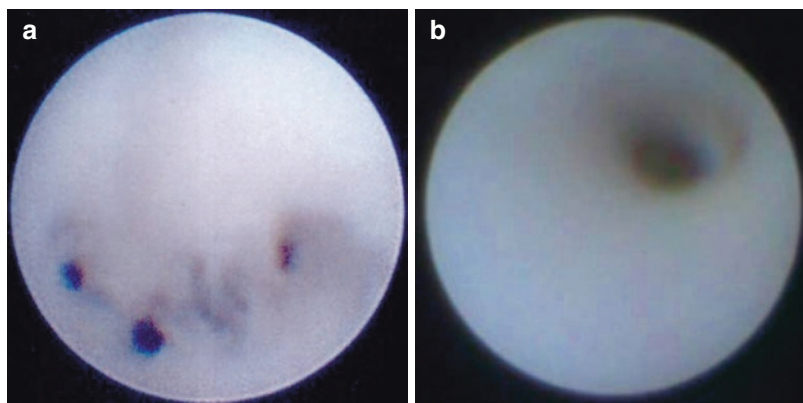


Fig. 7.1 Endoscopic view of a salivary duct stricture (a) and stenosis (b)

segment scar bands that extend across the ductal lumen. Strictures can be thin and weblike diaphragms or dense, fibrous plugs. *Stenosis* denotes a lengthwise segmental narrowing of the duct to a diameter to less than 1.5 mm without complete obliteration of the lumen. Strictures are more commonly observed in the setting of a focal ductal disruption from stone or trauma, whereas stenoses indicate a more generalized glandular inflammation associated with chronic, autoimmune, or radioiodine sialadenitis.

Patient Evaluation

History and Physical Examination

The presentation of salivary duct scar is no different than that of obstructive sialadenitis. Patients complain of an almost daily painful swelling of the affected gland, typically during meals or upon salivary stimulation. The ostium of the affected gland may intermittently drain a thick, mucoid discharge with a salty or foul taste. More rarely, the patient may present with an episode of acute inflammation, fever, overlying skin erythema, and purulent ductal discharge.

A thorough history should investigate potential causes of obstructive sialadenitis such as passage of stones, local trauma, history of radioiodine, or history of autoimmune disease. Ductal scar typically presents with obstructive symptoms in a single gland, most commonly a parotid gland. However, ductal scar is usually present in a gland with worsening obstructive symptoms in the setting of a multi-gland disorder such as Sjögren's or radioiodine sialadenitis.

Xerostomia can precipitate and exacerbate the symptoms of obstructive sialadenitis due to low salivary flow and the formation of mucous plugs. Patients should be questioned as to whether they frequently experience a dry mouth and/or dry eyes. The patient's medication list should be reviewed for medications that cause xerostomia such as diuretics, antidepressants, and antihistamines. Patients should be advised to reduce caffeine and abstain from tobacco

products. A 15-min unstimulated saliva collection is a straightforward method of screening for Sjögren's disease. Patients are instructed to spit all of their saliva into a measuring cup for 15 min. Total collected volumes less than 1.5 mL are suggestive of Sjögren's and should be followed by Sjögren's antibody testing [7]. Minor salivary gland biopsy, which is more sensitive but less specific than antibody testing, should be considered in cases with negative Sjögren's serologies if the patient has complaints of xerostomia and/or xerophthalmia, has multi-gland involvement, or has intraglandular adenopathy on imaging.

The involved gland may or may not appear obviously swollen on visual inspection. Palpation of the affected gland will typically feel more firm than non-involved glands and may be tender. If periglandular or upper cervical lymph nodes are palpated, infection or malignancy should be ruled out. Although Sjögren's patients frequently have scattered intraglandular adenopathy, these nodes are usually not palpable. If palpable nodes are present in the setting of autoimmune disorder, fine needle aspiration with flow cytometry is indicated in order to rule out lymphoma. The duct of the gland should be inspected while massaging the gland to note the volume and character of the saliva. In the setting of ductal scar, flow will often be absent or may spurt out of the duct when massaging pressure is applied to the gland. Bimanual palpation can assess for stones in the distal portion of the duct.

Imaging

The next step in the management of a patient with obstructive salivary symptoms is imaging. Although rare, the first reason for imaging is to rule out a salivary tumor or mass as a cause of the obstruction. Computed tomography is often the initial imaging modality of choice in North America, and although excellent for the detection of small sialoliths, it is not as sensitive as other modalities for the detection of salivary duct scar. Scintigraphy demonstrates retention of radiolabel upon sialogogue challenge but fails to differentiate the cause of obstruction.

Similar to their European colleagues, many experienced North American sialendoscopists now favor in-office ultrasonography as the initial imaging modality of choice. If a salivary clinic is equipped with an ultrasound machine, it can be used in real time to render a presumptive diagnosis during the patient visit. Ultrasonography is sensitive, relatively inexpensive, and noninvasive and avoids exposure to ionizing radiation. The best advantage is that it allows dynamic imaging of the blocked salivary gland when performed after a sialagogue challenge with sour candy or lemon juice. Obstructed glands will typically reveal engorged, blocked ducts on ultrasound after sialagogue challenge since the blockage prevents the saliva from freely passing into the oral cavity. The ultrasonographer can then trace the swollen duct with the ultrasound probe until it comes to a choke point at the blockage. If the acoustic signal and shadow of a salivary stone are not seen at this blockage point, it is likely that the blockage is caused by a salivary scar although other possibilities include small (<3 mm) or poorly calcified stones. The region of the duct in which the blockage is visualized should be noted in order to guide subsequent endoscopic approaches. Patients with generalized ductal stenosis may have dilated ducts with smaller lumens and thickened ductal walls (Fig. 7.2).

Currently there is no imaging modality with sufficient resolution to definitely show intra-

ductal scar tissue. Ultrasound can detect a blockage or pinch point; however the actual cause of the blockage may not be revealed until direct inspection with sialendoscopy. Therefore, most sialendoscopists will proceed to diagnostic sialendoscopy at this point in patient management. If the patient or physician desires more information prior to sialendoscopy, additional imaging options are available. If a stone is suspected at the blockage point, the physician may proceed to CT scan without contrast since this will be more sensitive for small stones. If scar is suspected, the ultrasound can be followed by either standard contrast sialography or magnetic resonance (MR) sialography to better delineate the luminal anatomy of the salivary duct. Although rarely used, sialography is the most sensitive technique for visualizing luminal filling defects and can differentiate between focal stricture and segmental stenosis. In addition, sialography will often reveal multiple stenoses not seen by ultrasound or small stenoses in second and third level ducts beyond the hilum within the intraglandular ductal system. Standard sialography may involve some discomfort to the patient due to the need for ductal dilation and infusion of contrast and carries the small risk of a contrast dye reaction. In addition, many radiologists are not familiar with ductal cannulation; therefore the sialendoscopist must be willing to escort the patient to the radiology suite in order to capture

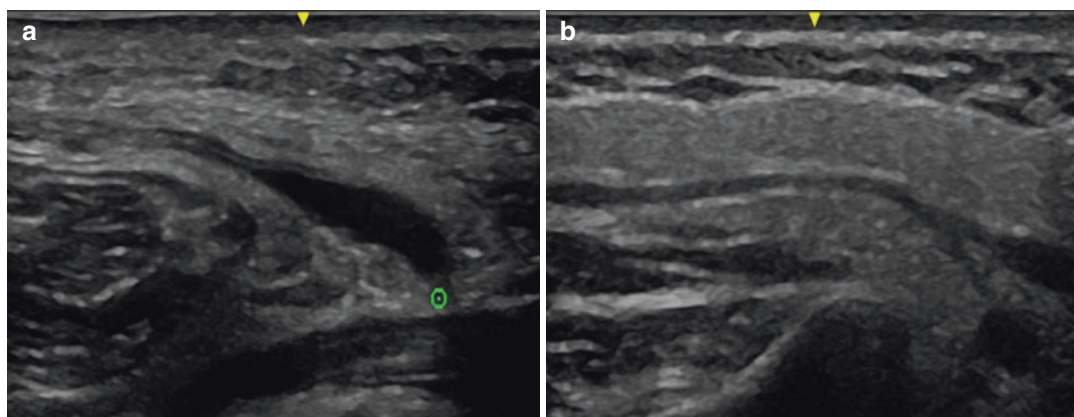


Fig. 7.2 Transverse view on ultrasound of a dilated right Stensen's duct with obstruction at the ostium (a); a left dilated Stensen's duct with thickened duct wall (b)

an acceptable image. In a large review of 1349 sialograms performed on patients with obstructive symptoms, Ngu et al. found that 64% demonstrated ductal anomalies, 23% of which were ductal strictures. Of the 198 cases of ductal stricture, 66% were single site, 33% were multiple sites, and 7% were bilateral. The authors noted that patients with stricture were predominantly female (72%) with a mean age of 52 years [8]. MR sialography provides a virtual image of the salivary ductal system using a T2-weighted algorithm which enhances water-containing fluids such as saliva. MR sialography is noninvasive but requires expertise in the technique and may be more expensive than other currently available modalities. A series of patients with obstructive sialadenitis imaged with MR sialography found that the technique was 100% sensitive and 93% specific for patients found to have ductal stenosis on sialendoscopy [9]. MR sialography may therefore be an underutilized technique in the evaluation of patients with ductal scar.

Identification and Classification of Ductal Scar: Diagnostic Sialendoscopy

Diagnostic Sialendoscopy

Diagnostic sialendoscopy is the next appropriate step in a patient who presents with obstructive symptoms and imaging consistent with ductal scar. Diagnostic sialendoscopy is the only means to confirm the diagnosis of ductal scar via direct visualization. In addition to confirming the diagnosis, the type and extent of the ductal scar can be characterized in order to inform the subsequent treatment approach. Diagnostic sialendoscopy is frequently performed as a stand-alone procedure in an awake patient at European salivary centers. In North America, diagnostic sialendoscopy is more often performed under general anesthesia in an ambulatory operative setting [10]. Performing diagnostic sialendoscopy under general anesthesia has several advantages but a few disadvantages compared to office-based diagnostic sialendoscopy (Table 7.1).

Table 7.1 Comparison of in-office and operating room sialendoscopy

Clinical factor	In-office	Operating room
Cannulation success	+	++
Patient tolerance	+	++
Scope damage prevention	–	+
Single treatment	+	++
Multiple gland involvement	+	++
Therapeutic intervention	+	++
Incisional approach	+	++
Resource allocation	++	–
Expense	++	–

Excellent (++); good (+); below average (–)

The sialendoscopist should document the appearance and character of the salivary duct papilla and ostium. The oral mucosa surrounding the papilla may be thin and atrophic or inflamed and hypertrophic. The ostium is readily identified under loop magnification if saliva flows from the ostium with gland massage. If salivary flow is limited or the tissues atrophic, ostial identification is aided by applying a thin layer of methylene blue to the papilla while vigorously milking the gland under microscopic visualization. The smallest salivary dilator is then introduced into the ostium, followed by progressively larger dilators. The dilator needs to be inserted for only 2–3 mm or just enough to allow the ostium to accommodate the diagnostic sialendoscope (0.8 mm outer diameter Erlangen or Marchal salivary endoscope, Karl Storz, Tuttlingen, Germany). Overly deep or aggressive dilation may lead to inadvertent perforation of stiff and brittle ductal scar which is often present in the distal main duct.

The ostium itself, which is the narrowest point of a normal duct, may be a site of ductal scar in up to 20% of cases. In such cases, the ostium cannot be effectively dilated to allow scope insertion [3]. Attempts can be made to pass a guidewire followed by dilation over the wire using a disposable salivary dilator kit (Cook Medical, Bloomington, IN, USA) (Fig. 7.3). However, a combined “cut-down” approach must be considered in the event that neither dilator nor guidewire cannulation is feasible.

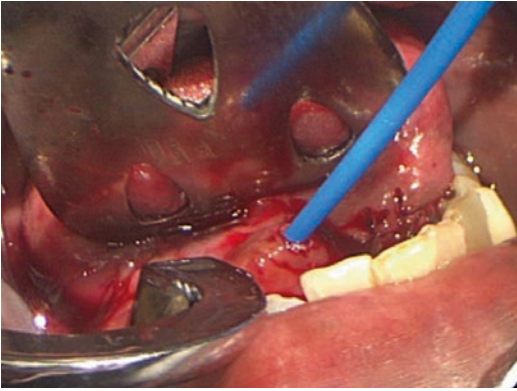


Fig. 7.3 Dilation of right Wharton's duct with guidewire and malleable dilator set

Classification of Ductal Scar

Once scar tissue within the ductal system is confirmed with diagnostic sialendoscopy, the sialendoscopist surveys the ostium, main duct, hilum, and intraglandular ducts in order to fully describe the severity and extent of the disorder. A complete diagnostic endoscopy identifies sites in need of therapeutic intervention, along with the techniques that will be needed to treat the affected ductal segment. In addition, the survey has prognostic significance since patients with limited, short, thin scars respond better long-term than patient with long segment or dense scarring.

The goal of diagnostic sialendoscopy is a complete description of the ductal scar (Table 7.2). At the very least, this should include a description of the ductal tissue, the presence of stricture versus stenosis, as well as the location, grade, and length of the scar. Ductal tissue may be inflamed with fuzzy pinkish edema of the ductal wall with increased vascularity, or white, and atrophic with loss of vascular markings. It is common for the tip of the endoscope to produce streaks of de-epithelization in atrophic scarred ducts. A stricture is usually a short segment of intraluminal scar with either a complete blockage or pinhole lumen. A stenosis is a long segment circumferential narrowing of the ductal lumen. The location of the scar should be described anatomically by ductal site (ostium, main duct, hilum, intraglandular duct) and distance from the

Table 7.2 Description of salivary duct scar tissue

Factor	Description
Tissue color	Pink salmon/thin vessels Pale/avascular Erythematous/red/dilated vessels
Tissue consistency	Pliable Stiff
Scar location	Ostium Main duct (distal) Main duct (proximal) Hilum Intraglandular duct
Scar distance from ostium	Centimeters
Scar type	Stricture Stenosis
Scar grade	1 (0–50% stenosis, 1.3 mm scope) 2 (50–70% stenosis, 1.1 mm scope) 3 (70–99% stenosis, 0.8 mm scope) 4 (100%)
Scar extent	S0 no stenosis S1 one or more diaphragmatic stenoses S2 single stenosis, main duct S3 multiple stenosis or complete main duct S4 diffuse (main duct and intraglandular)
Scar inflammation	Type 1 inflammatory Type 2 web stenosis, segmental dilations Type 3 fibrotic, long-segment stenosis

ostium. Distance from the ostium can be conveniently measured using the laser markings that are placed at each centimeter along the length of the shaft of the salivary scope. In general, the distal duct is within 2 cm of the ostium, the main duct 2–4 cm, the perihilar area 4–6 cm, and the intraglandular region beyond 6 cm. In addition, it should be noted if the scar tissue involves a single or multiple sites and whether it is a short (<1 cm), intermediate (1–3 cm), or diffuse (>3 cm or multiple segments) stenosis [11].

In order to provide an accurate description of the scar, the sialendoscopist must be familiar with the diameter of different salivary scopes in relation to average ductal diameters. The Erlangen Salivary Scope system (Karl Storz, Tuttlingen, Germany) comes in three diameters including a 0.8 mm diagnostic scope and two therapeutic scopes of 1.1 mm and 1.6 mm diameter with working channels. The Marchal Salivary

Scope system (Karl Storz, Tuttlingen, Germany) includes a 0.89 mm diagnostic scope and three therapeutic scopes of 1.1, 1.3, and 1.6 mm diameter. Knowing that ductal scar rarely causes symptoms if the ductal lumen is greater than 1.5 mm in diameter, a gland does not have pathologic stenosis if the main duct can accommodate passage of a 1.6 mm scope. In general, it is best to begin salivary endoscopy with the narrow diagnostic scope in order to dilate the duct with saline and prepare the way for the larger therapeutic scopes. Assuming the luminal diameter of the normal duct is between 2.0 and 2.5 mm, ease of passage of the various salivary scopes can be used as a quick and dirty guide for estimating the diameter of the lumen. If the 0.8 mm scope cannot pass easily, meets significant resistance, or creates drag on the ductal wall, the ductal diameter is 0.8 mm or less (>66% stenosis). If the 1.1 mm scope cannot pass easily, the stenosis is estimated at 50% or greater, whereas inability to pass a 1.6 mm scope indicates a 33% stenosis. If a stricture with a small opening is encountered, the diameter of the opening can be estimated by placing the tip of the scope against the pinhole and estimating its diameter compared to the known diameter of endoscope (minus the working and irrigating channel). Pinholes that do not allow passage of a salivary guidewire have a diameter less than 0.4 mm (85% stenosis). A convenient grading system to use that is familiar to otolaryngologist is the grading system for tracheal stenosis [12]. In such a description, Grade 1 is a luminal stenosis of 50% or less (allows passage of 1.3 mm scope); Grade 2 is a stenosis of 50–70% (allows passage of 1.1 mm scope); Grade 3 is a stenosis of 70–99% (0.8 mm scope can pass or pinhole seen); and Grade 4 is a 100% blockage (no lumen).

Several sophisticated classification systems of salivary duct scar have been proposed. One descriptive classification system that focuses on the extent of the stenosis is the L, S, D (lithiasis, stenosis, dilation) grading Scheme [13]. In this system, a given salivary duct can be classified as S0, no stenosis; S1, one or more diaphragmatic stenoses; S2, single stenosis of the main duct; S3, multiple stenoses of the main duct, or a single

stenosis involving the entire main duct; and S4, generalized or diffuse duct stenosis. Another classification system seeks to describe various tissue types that are associated with ductal scar. In this system, Type 1 stenosis is characterized by an inflamed, hyperemic ductal system; Type 2 is weblike ring stenosis with associated dilated ductal segments; and Type 3 is a longer segment, fibrotic salivary duct [11]. The relative frequency of tissue types encountered at a major European salivary center was 10% Type 1, 20% Type 2, and 70% Type 3. The authors of the tissue type classification scheme propose that the Type 1 may be a predecessor to the Type 3.

Classification systems have the most utility if they, similar to tumor staging, lend insight into the cause of a disorder, the optimal treatment plan, or the prognosis of the patient. The present classification schemes are predominantly descriptive and have not been fully validated to determine how they inform treatment decisions or prognosis. After a mean follow-up of greater than 8 years, Koch et al. noted that all three tissue types of stenosis had significant improvement in symptoms; however patients with Type 3 stenosis experience lower rates of pain (16%) compared to Type 1 (23%) and Type 2 (27%) [14]. This finding suggests that Type 1 and 2 stenoses may represent an ongoing disorder, whereas Type 3 represents an end-stage process.

Management of Salivary Duct Scar

Conservative Management

The initial treatment of obstructive sialadenitis involves conservative measures designed to stimulate salivary flow and reduce inflammation including increased hydration, avoidance of drying medications and ingestions, sialagogues, warm compresses, anti-inflammatory medications, and massage of the affected gland. Mucolytics may be of benefit in patients who present with thick or gooey saliva. Antibiotics may be required if bacterial infection is suspected. Conservative management should be attempted for the first two to three swelling

episodes, but more frequent episodes suggest the need for greater intervention. Most patients will have undergone unsuccessful conservative management by the time that they present to a salivary surgeon.

Endoscopic Approach

In cases where conservative management fails and patient symptoms are severe, surgical excision of the salivary gland has historically been the mainstay of definitive treatment but has largely lost favor in the era of gland-preserving endoscopic techniques. In North America, therapeutic sialendoscopy is routinely performed in an ambulatory operative suite under general anesthesia immediately after diagnostic sialendoscopy [10]. The surgeon cannot be 100% certain of the diagnosis and treatment plan until a diagnostic survey of the ductal system is complete. In addition, the therapeutic intervention may be as brief as 30 min or as long as 2 h depending on the severity of the underlying disorder. As a rule of thumb, most gland-preserving surgeries can be performed in 90 min or less; therefore this appears to be an appropriate posting time to allow the surgeon to complete the intervention without feeling excessively rushed. Nasal intubation facilitates exposure of the floor of mouth and submandibular duct, whereas the parotid duct and buccal space can be adequately accessed with standard oral intubation.

The surgeon must have available a wide range of accessory equipment to effectively manage salivary duct scar and be prepared for a variety of endoscopic and open approaches for treatment. In addition to salivary scopes and video system, other helpful tools include a variety of salivary dilator sets, operating microscope, intraoperative ultrasound machine, facial nerve integrity monitor, salivary guidewire with malleable dilators, micro hand drill, salivary baskets, salivary duct balloons, and a salivary stent. The sialendoscopist must also know the diameter of the scope working channel in relationship to the instruments that may be needed during the procedure. For example, the 1.1 mm salivary endoscopes have

a 0.45 mm working channel that allows passage of endoscopic guidewires, micro hand drills, baskets, and holmium YAG laser fibers (200 micrometer diameter). The larger 1.6 mm scope with a 0.85 mm working channel is required for use of micro forceps and balloons (0.8 mm diameter). In practice, this makes it difficult to use the micro forceps or balloon during the treatment of ductal scar since it is often impossible to pass a 1.6 mm sialendoscope through a stenosed duct. With practice, balloons can be passed alongside a smaller scope to reach scar within the main duct. Currently, there are commercially available stents made by various manufacturers (Hood Laboratories, Pembroke, MA; Sialo Technology, Ashkelon, Israel), although surgeons often prefer to fashion their own stents with a 16 (1.65 mm outer diameter) or 18 (1.27 mm outer diameter) gauge angiocatheter or a 1 mm pediatric feeding tube. Although used on occasion to shatter stones, lasers (holmium YAG contact laser) are currently not favored in the treatment of ductal scar tissue. In fact, the formation of ductal stricture is a potential complication when used for stones due to ductal wall damage from excessive heat transmission. Using a laser to treat scar could directly damage the duct wall and thereby worsen the scar in the long run.

Salivary duct scar is often more amendable to a purely endoscopic approach compared to salivary stones. A large retrospective series found that significantly more non-stone obstructions could be treated with endoscopic approaches alone compared to stones (77% vs. 17%) [15]. The list of ductal scar types amendable to endoscopic methods is outlined in Table 7.3. In general, if the main duct is >50% (1.1 mm) of the normal lumen, the duct can be dilated with serial placement of progressively larger salivary endoscopes (0.8 mm; 1.1 mm; 1.3 mm; 1.6 mm) with associated hydrostatic dilation of saline through the irrigation channel. If <50% of the normal main duct lumen is present (<1.1 mm), additional dilation with an endoscopic balloon or guidewire with malleable dilator is necessary. If a 99–100% stricture or diaphragmatic web is encountered, the tip of a 0.8 mm endoscope or a micro hand drill can be used in an attempt to

Table 7.3 Management approach to different ductal scars

Scar type	Scope size	Intervention
Grade 1 (lumen \geq 50%)	1.1 mm, 1.3 mm, 1.6 mm	<ul style="list-style-type: none"> Serial passage of larger scopes Hydrostatic dilation
Grade 2 (lumen 30–50%)	1.1 mm	<ul style="list-style-type: none"> Guidewire/malleable dilators Endoscopic balloon
Grade 3/4 ($<$ 30% lumen)	0.8 mm, 1.1 mm	<ul style="list-style-type: none"> Perforate scar with hand drill, scope tip Guidewire/malleable dilators
Grade 3/4 ($<$ 30% lumen)	Unable to pass scope Unable to pass guidewire	<ul style="list-style-type: none"> Combined (incisional) approach
Intraglandular (proximal/higher-order ducts)	0.8 mm, 1.1 mm	<ul style="list-style-type: none"> Scope tip dilation Hydrostatic dilation Scope tip dilation

perforate the stricture into the lumen beyond. The jaws of endoscopic forceps can be used to stretch a scarred segment when open and can carefully debride loose strands of scar tissue in the lumen. This creates a passage for a guidewire that will allow passage of progressively larger malleable dilators. Additional dilation is then performed by passing progressively larger scopes through the now dilated segment. If a 5F (1.67 mm diameter) or 1.6 mm scope can be passed through the main duct, it is unlikely that the patient will have persistent obstructive symptoms as long as the scar does not reform. Diffuse scar tissue (S4 classification) extends beyond the main duct, and hilum occurs in approximately 15% of cases of parotid scar and 20% of cases of submandibular scar [14, 16]. When scar is in the intraglandular ductal system beyond the hilum, the surgeon will try to maneuver the tip of an 0.8 mm salivary scope into each second and third order duct in order to provide direct hydrostatic dilation. This will prepare the way for a 1.1 mm salivary scope with working channel to dilate each second and third order duct with an endoscopic basket. The basket is passed into the narrow duct while closed and then fully opened and used to dilate the duct with a gentle back and forth motion. It is important to massage and empty the gland when scopes are removed or exchanged in order to prevent overfilling of irrigation that could lead to duct rupture.

At the conclusion of the dilation, a steroid solution (5 ml of 10 mg/mL triamcinolone acetonide) can be infused with an angiocatheter and massaged into the gland to reduce glandular

swelling acutely and long-term scar formation. Steroids may be especially beneficial in cases of Type 1 inflammatory stenosis that presents with ductal wall edema and hyperemia. If scar tissue is localized in the ostium or main duct, the surgeon may elect to insert a salivary stent at the conclusion of the procedure, especially if the scar tissue is high grade [3, 4] and at risk of reforming. Although it is commonly advocated that a salivary stent remain in place for 2–3 weeks, stents often impede the flow of saliva and therefore may precipitate salivary stasis, swelling, infection, and discomfort. Due to ongoing symptoms, and frequent dislodgement during mastication, stents rarely remain in place for more than 1 week in the majority of patients. Therefore, stents are best avoided in patients who are likely to have sufficient flow to maintain ductal patency.

One special group of disorders which has a patient presentation similar to salivary duct scar is ductal kinks first described by Nahlieli et al. [4] Ductal kinks are functional obstructions of the duct from external compression, traction, or ductal folds that create pinch points that impede normal salivary flow. Common causes of kinks include congenitally redundant ductal folds, external traction from scar tissue (trauma, post-radiation, post-facelift, or skin cancer surgery), or compression from surrounding tissues (mandibular tori, masseteric hypertrophy). In the Nahlieli series, kinks diagnosed by sialography were treated with a combination of hydrostatic or balloon dilation with sialendoscopy or ductal advancement procedures with 80% complete

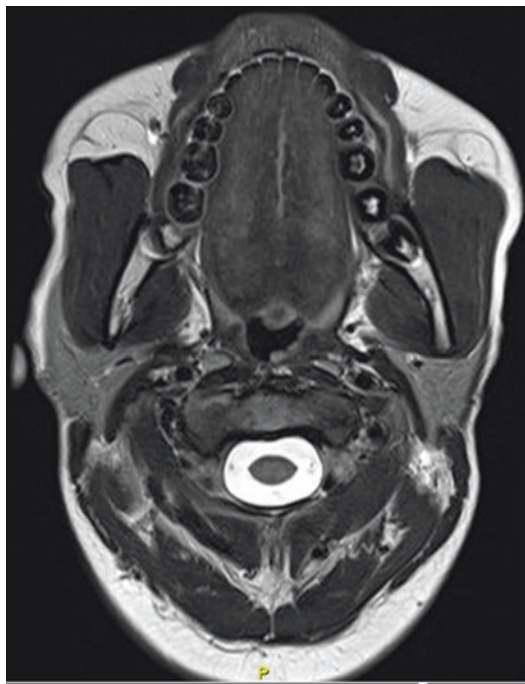

Fig. 7.4 Bilateral masseteric hypertrophy causing facial swelling as viewed on MRI

resolution of symptoms at 8–36 months. One type of kink which may mimic an obstructive salivary disorder is produced from an acute bend around a hypertrophied masseter muscle [4]. This disorder should be suspected if imaging reveals an enlarged masseter muscle and an associated obstructed Stensen's duct (Fig. 7.4). Patients with this presentation should be evaluated for bruxism, temporomandibular joint disorder, or underlying disorders that may lead to muscle or masseteric space hypertrophy (fibrous dysplasia, rhabdomyoma, lymphangioma, myopathy). In addition to immediate treatment of the ductal kink with sialendoscopy and dilation, long-term management includes therapy to reduce masseteric muscle bulk including oral bite appliances, botulinum toxin type A, and selective debulking of the muscle itself [17].

Iatrogenic ductal perforation is a potential complication of endoscopic management of salivary duct scar. The narrow, stiff scar tissue will deflect a dilator or scope through the inelastic ductal wall. Perforation rates may be as high as 10% during the initial 50-patient learning curve

but typically decrease to 2–3% with ongoing experience [15, 18]. Perforations may be more frequent when salivary endoscopy is performed under general anesthesia since the surgeon cannot note if the dilation is causing the patient significant discomfort. Most perforations are due to the initial blind dilation of a scarred ostium or distal duct due to the pinched nature and acute angulation of both Wharton's and Stensen's duct at this location. Therefore, the surgeon must exercise caution to not dilate an ostium in an overly aggressive fashion when ductal scar is suspected. The ostium should be dilated with only the first 2–3 mm of the dilator tip in order to allow enough opening to insert a salivary scope so that the remainder of the dilation can be performed under visualization. A perforation has occurred if upon insertion of the scope, the surgeon sees fat or cobweb-like connective tissue or notes swelling of the anterior cheek or floor of mouth when irrigation is applied. If the perforation occurs in the distal parotid duct or ostium, the first step is to stop the irrigation since the irrigation will fill the tissues surrounding the duct resulting in worsening ductal collapse. Next, the surgeon should slowly pull back the scope until the tip is back in the duct and the perforation visualized. Lastly, the true lumen can be visualized as a slit adjacent to the perforation. Placing a guidewire down the natural lumen reestablishes this pathway and serves as a guide to mal-leable dilators. The dilators enlarge the duct to a sufficient size to accommodate a scope and make the natural lumen, and not the perforation, the pathway of least resistance. The surgeon can then address pathology proximal to the perforation while applying gentle pressure to the skin overlying the perforation site in order to limit egress of saline irrigation into the surrounding soft tissues. Placement of a stent to bridge the area of the perforation is advised in order to reduce the potential for sialoceles or fistula. With early recognition and appropriate management, the perforation will have little effect on long-term outcome. As opposed to the parotid duct, perforations of Wharton's duct are more readily managed by incising the overlying mucosa which allows egress of the collecting fluid and

access to the duct which can be opened with a formal sialodochoplasty through the site of perforation. Salivary scopes can then be passed through the dichotomy to treat more proximal regions of the duct [18].

Postoperative care will generally consist of a short course of oral steroids (prednisone 40 mg/day for 3 days) and increased hydration and gland massage for 1–2 weeks. A week of antibiotics (amoxicillin/clavulanic acid) is indicated in the presence of underlying purulent or inflammatory exudate or in the event of perforation or incisional approach. Some patients may require 1 or 2 days of narcotic analgesics; however a nonsteroidal analgesic suffices for most patients.

Combined Approach

The combined approach involves the use of sialendoscopy in combination with strategically placed incisions to repair ductal pathology that is not amendable to endoscopic treatment alone. The combined approach may be needed in cases of Grade 3 or 4 scar of the ostium or main duct which does not allow passage of a guidewire. Certain types of ductal kinks and Type 2 web stenoses with associated megaduct respond well to this approach. Performing gland-preserving surgery under general anesthesia in the ambulatory setting allows the surgeon a certain amount of flexibility and eases the transition from an endoscopic to combined approach with maximal patient comfort.

The combined approach is used more often for Wharton's than Stensen's duct due to straightforward access to this duct underneath the floor of mouth mucosa. If ostial dilation is not possible due to scar, a limited distal sialodochoplasty is a rapid and reliable method of gaining access to Wharton's duct [19]. A 1 cm incision is made through the mucosa along the lingual surface of the salivary crest posterior and lateral to the papilla. Blunt dissection is used to identify the distal Wharton's duct which can be gently retracted with forceps or rubber vessel loop retractor (Fig. 7.5). A 2–3 mm slit is then made in the superior surface of the duct with an

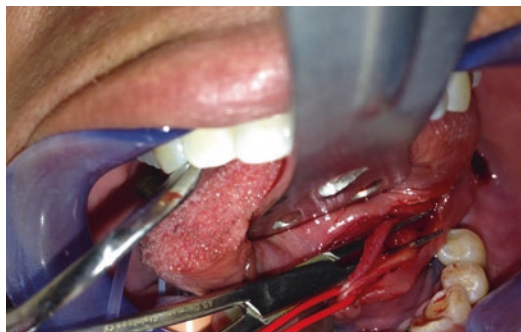

Fig. 7.5 Retraction of left Wharton's duct with vessel loop

11 blade. The duct wall is then secured to the surrounding floor of mouth mucosa with two or three 4.0 Vicryl sutures thereby effectively bypassing the ostial scar. The scope is then inserted through the dochotomy to examine the proximal ductal segments.

The entire Wharton's duct can be approached in a similar fashion from the ostium to the hilum along the posterior border of the mylohyoid should sialendoscopy reveal a Grade 3 or 4 stenosis or long-segment stenosis not amendable to endoscopic management. The area of the scar is marked on the floor of the mouth by noting the transillumination of the salivary endoscope. An incision is made through the mucosa only in the floor of the mouth medial to the sublingual gland. Incision of the sublingual should be avoided to prevent later ranula formation. Wharton's duct, which has been expanded with irrigation from the salivary scope, can be identified with blunt dissection running along the medial border of the sublingual gland. The superior surface of the scarred ductal segment can then be filleted open with an 11 blade and ball-tipped scissors until normal ductal lumen is encountered. Incisional along the superior surface of the duct avoids trauma to the branches of the lingual nerve which pass lateral to medial underneath Wharton's duct. Once normal lumen is encountered, the open duct is sutured to the surrounding floor of mouth mucosa with interrupted 4.0 Vicryl sutures. Stenting of the opening is left to the discretion of the surgeon but is generally not needed if good salivary flow is anticipated. The sialendoscope is

then passed through the sialodochoplasty into the hilum and proximal ductal system to assess for additional pathology. A similar approach can be used when treating kinks from a redundant duct. In the approach described by Nahlieli et al., an anterior floor of mouth incision is used to access Wharton's duct which is then bluntly dissected from surrounding tissues [4]. The freed duct is pulled forward to excise a segment of redundant duct followed by securing the lumen of the proximal stump to the floor of mouth mucosa thereby creating sufficient tension on the remaining duct to straighten the kinks and allow unimpeded salivary flow.

Scarring of the parotid ostia is less frequent due to a better formed papilla but is a more difficult problem when it does occur. There are three methods by which to access the duct: [1] method of Foletti with semicircular incision, [2] method of Marchal circular incision, and [3] transfacial approach [20]. The least invasive of the three is the method of Foletti. A semicircular incision is made in the buccal mucosa 5 mm anterior to the parotid papilla. The incision extends through the underlying buccinator muscle fibers. This approach essentially opens a window into the buccal space that allows visualization of the distal Stensen's duct as it makes its 90° turn into the oral cavity. Vicryl sutures can be placed in the papillary mucosa and anterior to the incision to retract the incision thereby allowing for wider visualization. Blunt dissection is then used to identify the distal segment of Stensen's duct and separate it from the surrounding buccal fat and soft tissue. A limited dichotomy of 3 mm can then be made with an 11 blade under magnified visualization. The diagnostic scope is then inserted to examine the proximal Stensen's duct and hilum. Attempts can be made to angle the scope retrograde to examine the distal duct and ostium, followed by threading of a guidewire (0.4 mm salivary guidewire, Cook Medical, Bloomington, IN, USA) to allow dilation and stenting of the stenosed distal duct and ostium. If this is not feasible due to severe or dense scar, or difficult angulation, the approach can be converted to the circular incisional approach of Marchal.

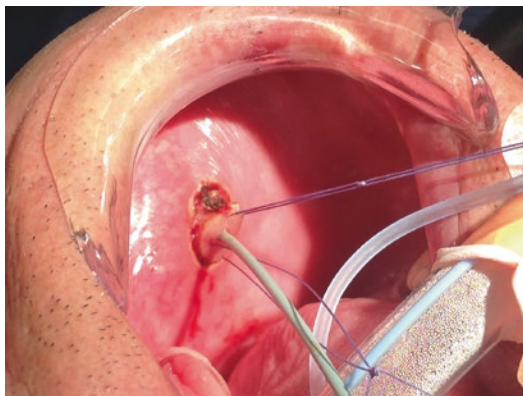


Fig. 7.6 Circumferential incision around left parotid ostium to gain access to distal Stensen's duct

In the Marchal approach, the mucosal incision is completed circumferentially around the papilla taking care to leave a 5 mm cuff of tissue (Fig. 7.6). Several Vicryl suspension sutures are placed in the peri-papillary mucosa, and the underlying buccinator muscle is incised in a similar circular manner. Blunt dissection is then used to deliver the ostium and distal duct into the oral cavity. The scarred distal duct and ostium are then excised and the more normal caliber proximal duct opened with a 1.0 cm slit along the medial surface with ball-tipped scissors or 11 blade under microscopic visualization. Limiting the incision to the medial surface protects the distal buccinator branch of the facial nerve. The opened duct wall is then sutured with sialodochoplasty to the surrounding buccal mucosa with 4.0 Vicryl suture, although some surgeons prefer 4.0 or 5.0 Monocryl or nylon suture with the thought that it will reduce tissue reaction and prevent stenosis or the neo-ostium. Stenting of the duct for 2–3 weeks postoperatively is needed in order to maintain the neo-ostium. This approach commits the patient to regular follow-up with serial in-office dilations in order to maintain the long-term patency of the neo-ostium.

A modification of the Marchal approach, the “pull-through sialodochoplasty,” is particularly useful when treating a distal ductal stricture with associated megaduct (Fig. 7.7). Type 2 stenoses of weblike rings alternating with dilations have a tendency to form megaducts due to a reservoir

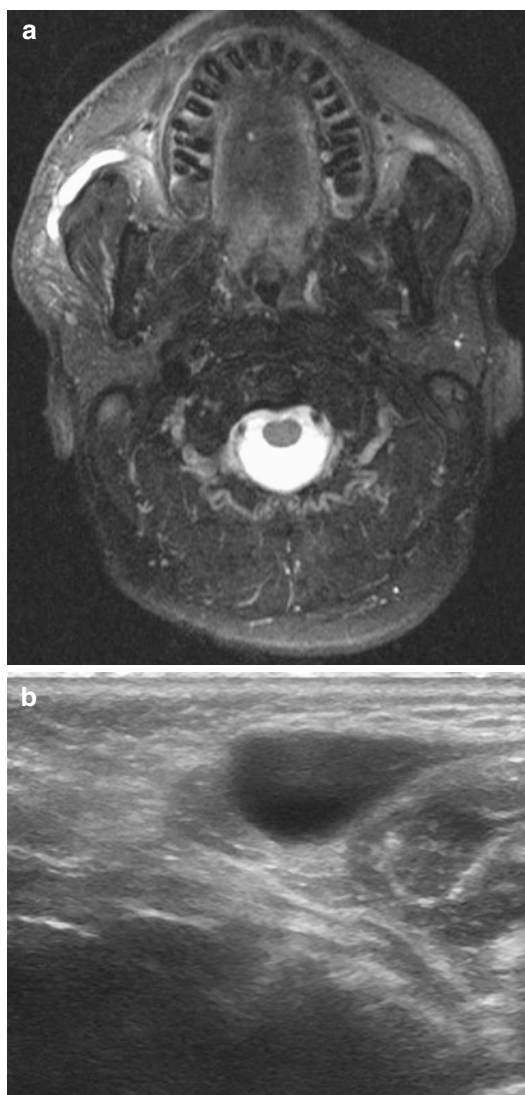


Fig. 7.7 Right parotid megaduct as viewed on MRI (a) and left Stensen's megaduct as seen on ultrasound (b)

effect [14, 21]. Megaducts are defined as Stensen's ducts with diameters exceeding 10 mm, often with thin walls that further contribute to the gland's weak excretory force [14, 22]. In addition to the obstructive symptoms, megaducts pose a cosmetic problem as they frequently appear as a bulge on the patient's cheek further reducing the patient's quality of life [14]. In pull-through sialodochoplasty, a flexible guidewire is passed through the area of stenosis into the megaduct under direct visualization with an endoscope or transcutaneous visualization via ultrasound. A

series of malleable flexible dilators (salivary access dilator set, Cook Medical, Bloomington, IN) are placed over the guidewire through the stenosis and into the megaduct (Fig. 7.8). A 4.0 Vicryl suture is then passed through the buccal mucosa adjacent to the ostium to allow traction on Stensen's duct. Megaduct dissection is performed by making a circumferential incision around the parotid ostia through the buccinator muscle. Additional blunt and sharp dissection is performed along the contour of the dilator to free the distal aspect of Stensen's duct. The megaduct is then pulled through the incision into the oral cavity. Kitner dissection is helpful to free the duct from the facial soft tissues. The megaduct is filleted open with a 15 blade or ball-tipped scissors through the ostium, stenosis, and megaduct along the medial surface of the duct in order to avoid buccal branches of the facial nerve. The wall of the megaduct is then sutured to the surrounding buccal mucosa with interrupted 4.0 Vicryl sutures. The scarred distal duct is excised. The integrity of the duct is confirmed by the salivary endoscope followed by placement of a salivary stent over a guidewire if there is any concern that the neo-ostium is narrow and might stenosis.

The method of Folletti and Marchal is indicated for short-segment scars of the ostium and distal 1–2 cm of Stensen's duct. If the scar extends beyond 2 cm or onto the anterior surface of the masseter muscle, a transfacial approach may be required [23]. A facial nerve integrity monitor is placed in the region of the ipsilateral upper lip in order to capture stimulation of the buccal branch of the facial nerve which is at greatest risk during this approach. The preauricular skin is incised with a modified Blair incision. The skin and subcutaneous tissue is raised over the parotid fascia to the distal border of the gland where the main Stensen's duct is found by direct visualization or intraoperative ultrasound. After isolating the main duct with blunt dissection, a 2–3 mm dichotomy can be opened in a segment of duct clear of nerve branches to allow passage of a scope into the proximal duct, hilum, and intraglandular ductal system (Fig. 7.9). The scope can then be passed in retrograde fashion in an attempt to find a passage to the distal duct and

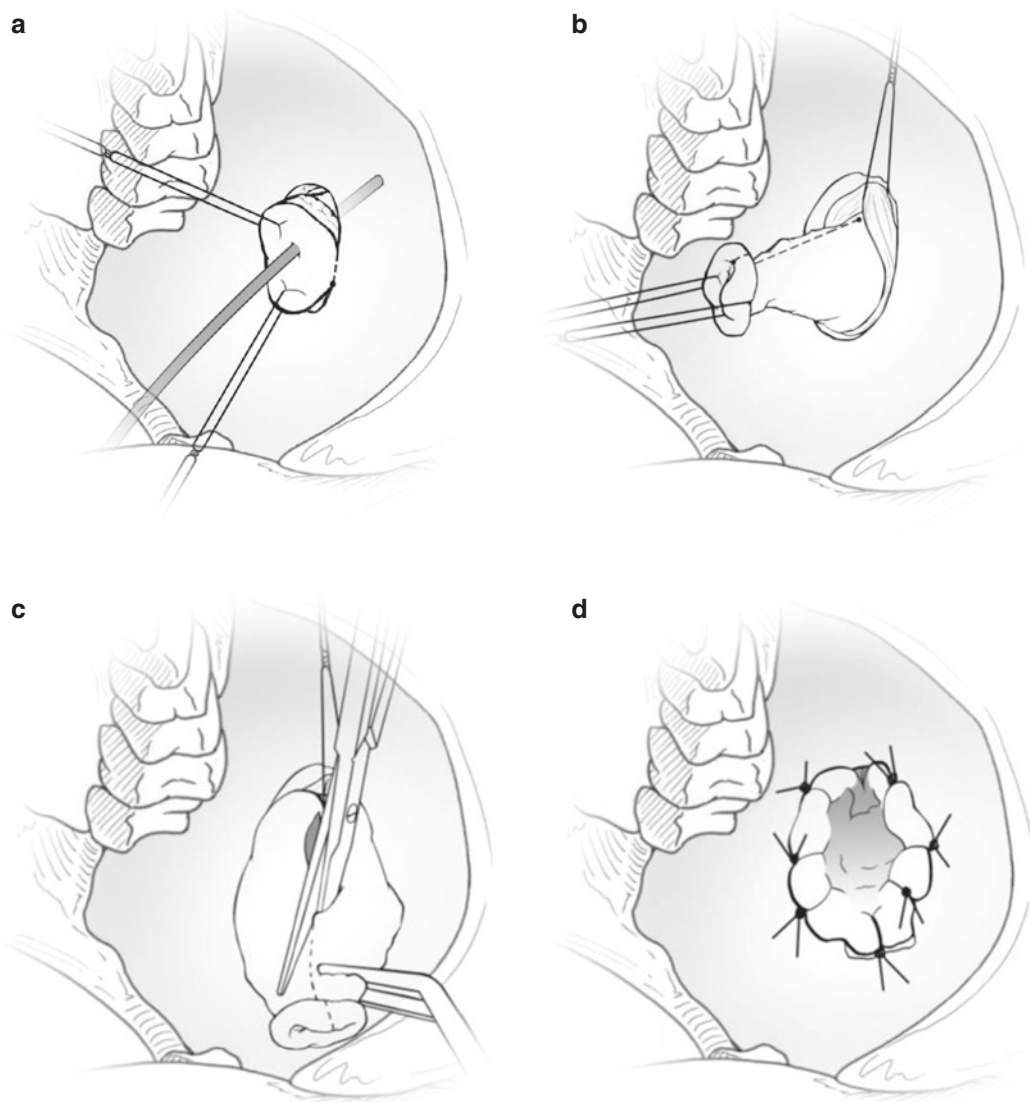


Fig. 7.8 Pull-through sialodochoplasty for Stensen's megaduct: a guidewire and dilator are passed through ostium (a); a circumferential incision is made through buccinator and the distal duct is pulled into the mouth (b);

the megaduct is opened on its medial surface (c); the megaduct wall is sutured to the buccal mucosa to make a neo-ostium (d)

ostium to dilate and stent. Once a stent is placed between the ostium and dichotomy site, the dichotomy is closed with a 5.0 Monocryl suture. The incision is then closed, typically without a drain, and a pressure dressing is applied for 72 h to prevent salivary leak. Advanced microvascular techniques may be required in the event of com-

plete Stensen's duct stricture (Grade 4) that does not allow passage of a scope or guidewire. Short segments of less than 5 mm can be treated by excision with end-to-end anastomosis. Longer segments have been successfully reconstructed using a vein graft from the external jugular or facial vein using 8.0–10.0 monofilament nylon

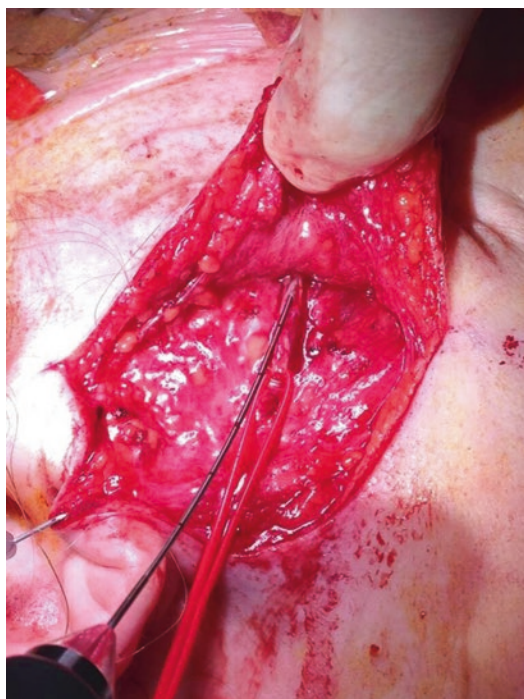


Fig. 7.9 Transfacial placement of scope to examine distal Stensen's duct

suture [24]. The vein graft can be sewn into the duct wall as a patch if the duct wall has enough integrity or can be sewn end-to-end as a tubular graft. Prolonged ductal stenting of 3–4 weeks is required until the anastomosis is fully healed.

Salvage Therapy

Despite the best efforts of sialendoscopy, certain cases of severe (Grade 4 stenosis) or diffuse scar (S4) disease are not amenable to gland preservation. Gland preservation is more difficult in systemic or multi-glandular inflammatory disorders such as Sjögren's syndrome that continue unabated and affect the gland parenchyma in addition to the ductal system. The goal of the surgeon is to maintain a functional gland while minimizing symptoms for as long as feasible. If the patient symptoms continue or worsen after first-line gland-preserving approaches, the surgeon and patient may choose to chemically or surgically silence the symptomatic gland. Although

anticholinergic drugs such as robinul and scopolamine reduce symptoms by reducing salivary production, the systemic nature of these medications affects other normal functioning glands and thereby increases the likelihood of xerostomia.

Botulinum toxin is a first-line alternative for symptomatic patients with glandular obstruction who are no longer considered candidates for gland preservation. Botulinum toxin chemically silences the gland by blocking the acetylcholine-mediated parasympathetic stimulation of salivary flow. By reducing salivary flow, the obstruction lessens and patient symptoms improve. Botulinum toxin provides additional anti-inflammatory effects reducing glutamate and substance P pain signaling [25]. Although botulinum toxin has only been recently applied to salivary obstructive disorders, it has been shown highly effective in patients with sialorrhea and has become the first-line treatment of choice for this disorder [26]. Botulinum toxin (100 units in 2 mL saline) is injected into two or three sites in the symptomatic gland under ultrasound guidance. Ultrasound ensures that the therapy is delivered into the gland thereby avoiding inadvertent injection of local muscle groups which could result in difficulties with speech and swallowing. Although the effect of the botulinum toxin is expected to last only 3–4 months, many patients experience longer periods of relief between injections. Often a patient with an end-stage scar may only need one or two injections before the gland become quiescent from natural involution.

Transoral duct ligation is an alternative if botulinum toxin is not available or repeated injections are required. Transoral duct ligation has been shown to provide more reliable and long-lasting relief of drooling compared to botulinum toxin [27, 28]. Following ligation, the gland may demonstrate temporary worsening in swelling and obstructive symptoms that reduce over time as the gland involutes. The expected postoperative swelling can be mitigated by botulinum toxin injection at the time of ligation and/or a course of oral steroids and bland diet. Ultimately a small percentage of patients (<5%) progress to sialendectomy due to persistent symptoms and/or

complications of salivary obstruction including glandular abscess.

Outcomes

Several large series have shown excellent long-term outcomes with gland-preserving therapy for salivary duct scar. In a series of 82 patients with 98 parotid duct stenoses treated with sialendoscopy, significant improvement was noted in symptoms and quality of life as measured by visual analog scale after a mean follow-up time of 98 months [14]. Although improved, 50% of patients continued to have low-grade swelling and 20% recurrent pain. No patient required gland resection; however 10% underwent repeat sialendoscopy. A separate large series of 206 patients with both stone and non-stone obstruction, most of which was due to ductal scar, observed improvement in both the stone (96%) and non-stone (81%) groups by patient report after sialendoscopy [15]. When compared to the stone group, non-stone obstructions were associated with significantly higher rates of persistent symptoms (59% vs. 34%) and lower quality of life as measured by a modified oral health outcome survey. There was no higher rate in repeat surgery (6% vs. 13%) or gland excision (8% vs. 9%) in the stone group compared to the non-stone group. In summary, gland-preserving therapy for salivary duct scar results in a significant improvement in symptoms for most patients while avoiding the risks and complications of sialendectomy. Ongoing follow-up is required however due to an expected persistence of low-grade symptoms.

Future Directions

Gland-preserving therapy for salivary duct scar has undergone tremendous advancement in the past 20 years and will continue into the future with ongoing refinement of technique and instrumentation. Greater understanding of the etiologies of salivary duct scar will lead to improved medical therapy for these disorders. Advancements in imaging will allow for virtual

sialendoscopy in order to improve diagnosis and surgical planning [29]. Placement of specially designed indwelling stents, similar to those used for coronary occlusion, by sialendoscopy or fluoroscopy may become an option for difficult or recurrent ductal scars. Resorbable or drug-eluting stents may become commonplace and help to reduce sources of ongoing inflammation [30]. With such improvements, gland-preserving therapy will become more commonplace and more widely accepted for salivary duct scar.

References

1. Marchal F, Dulguerov P. Sialolithiasis management: the state of the art. *Arch Otolaryngol Head Neck Surg*. 2003;129:951–6.
2. Koch M, Zenk J, Bozzato A, Bumm K, Iro H. Sialoscopy in cases of unclear swelling of the major salivary glands. *Otolaryngol Head Neck Surg*. 2005;133(6):863–8.
3. Vashishta R, Gillespie MB. Salivary endoscopy for idiopathic chronic sialadenitis. *Laryngoscope*. 2013;123:3016–20.
4. Nahlieli O, Shacham R, Yoffe B, Eliav E. Diagnosis and treatment of strictures and kinks in salivary gland ducts. *J Oral Maxillofac Surg*. 2001;59:484–90.
5. Zenk J, et al. Diameters of the main excretory ducts of the human submandibular and parotid gland: a histologic study. *Oral Surg Oral Med Oral Pathol Oral Radiol Endod*. 1998;85:576–80.
6. Koch M, Iro H, Zenk J. Role of sialoscopy in the treatment of Stensen's duct strictures. *Ann Otol Rhinol Laryngol*. 2008;117:271–8.
7. Ramos-Casals M, Tzioufas AG, Stone JH, Siso A, Bosch X. Treatment of primary sjogren's syndrome: a systematic review. *JAMA*. 2010;304:452–60.
8. Ngu RK, Brown JE, Whaites EJ, Drage NA, Ng SY, Makdissi J. Salivary duct strictures: nature and incidence in benign salivary obstruction. *Dentomaxillofac Radiol*. 2007;36:63–7.
9. Becker M, Marchal F, Becker CD, Dulguerov P, Georgakopoulos G, Lehmann W, Terrier F. Sialolithiasis and salivary ductal stenosis: diagnostic accuracy of MR sialography with a three-dimensional extended-phase conjugate-symmetry rapid spin-echo sequence. *Radiology*. 2000;217:347–58.
10. Gillespie MB, Koch M, Iro H, Zenk J. Endoscopic-assisted gland-preserving therapy for chronic sialadenitis: a German and US comparison. *Arch Otolaryngol Head Neck Surg*. 2011;137:903–8.
11. Koch M, Iro H, Zenk J. Sialendoscopy-based diagnosis and classification of parotid duct stenosis. *Laryngoscope*. 2009;119:1696–703.
12. Myer CM, O'Connor DM, Cotton RT. Proposed grading system for subglottic stenosis based on

- endotracheal tube sizes. *Ann Otol Rhinol Laryngol*. 1994;103:319–23.
13. Marchal F, et al. Salivary stones and stenosis. A comprehensive classification. *Rev Stomatol Chir Maxillofac*. 2008;109:233–6.
 14. Koch M, Kunzel J, Iro H, Psychogios G, Zenk J. Long-term results and subjective outcome after gland-preserving treatment in parotid duct stenosis. *Laryngoscope*. 2014;124:1813–8.
 15. Gillespie MB, O'Connell BP, Rawl JW, McLaughlin CW, Carroll WW, Nguyen SA. Clinical and quality-of-life outcomes following gland-preserving surgery for chronic sialadenitis. *Laryngoscope*. 2015;125:1340–4.
 16. Koch M, Iro H, Künzel J, Psychogios G, Bozzato A, Zenk J. Diagnosis and gland-preserving minimally invasive therapy for Wharton's duct stenosis. *Laryngoscope*. 2011;122:552–8.
 17. Reddy R, White DR, Gillespie MB. Obstructive parotitis secondary to an acute masseteric bend. *ORL J Otorhinolaryngol Relat Spec*. 2012;74:12–5.
 18. Gillespie MB, Intaphan J, Nguyen SA. Endoscopic-assisted management of chronic sialadenitis. *Head Neck*. 2011;33:1346–51.
 19. Chang JL, Eisele DW. Limited distal sialodochotomy to facilitate sialendoscopy of the submandibular duct. *Laryngoscope*. 2013;123:1163–7.
 20. Abboud O. Chapter 65: Impossible cannulation of the parotid papilla: what to do? In Marchal F, ed. *Sialendoscopy: The Hands-On Book*. 2015, European Sialendoscopy Training Centre, Geneva, Switzerland.
 21. Ardekian L, Shamir D, Trabelsi M, Peled M. Chronic obstructive parotitis due to strictures of Stenson's duct: our treatment experience with sialoendoscopy. *J Oral Maxillofac Surg*. 2010;68(1):83–7.
 22. Koch M, Iro H, Klintworth N, Psychogios G, Zenk J. Results of minimally invasive gland-preserving treatment in different types of parotid duct stenosis. *Arch Otolaryngol Head Neck Surg*. 2012;138(9):804–10.
 23. Ryan WR, Chang JL, Eisele DW. Surgeon-performed ultrasound and transfacial sialendoscopy for complete parotid duct stenosis. *Laryngoscope*. 2014;124:418–20.
 24. Heymans O, Nelissen X, Medot M, Fissette J. Microsurgical repair of Stensen's duct using an interposition vein graft. *J Reconstr Microsurg*. 1999;15:105–7.
 25. Blumefield A, Silberstein SD, Dodick DW, Aurora SK, Turkel CC, Binder WJ. Method of injection of onabotulinumtoxin A for chronic migraine: a safe, well-tolerated, and effective treatment paradigm based on the PREEMPT clinical program. *Headache*. 2010;50:1406–18.
 26. Vashista R, Nguyen SA, White DR, Gillespie MB. Botulinum toxin for the treatment of sialorrhea: a meta-analysis. *Otolaryngol Head Neck Surg*. 2013;148:191–6.
 27. Formeister EJ, Dahl JP, Rose AS. Surgical management of chronic sialorrhea in pediatric patients: 10-year experience from one tertiary care institution. *Int J Pediatr Otorhinolaryngol*. 2014;78:1387–92.
 28. Chanu NP, Sahni JK, Aneja S, Naglot S. Four-duct ligation in children with drooling. *Am J Otolaryngol*. 2012;33:604–7.
 29. Su YX, Feng ST, Liao GQ, Zhong YQ, Liu HC, Zheng GS. CT virtual sialendoscopy versus conventional sialendoscopy in the visualization of salivary ductal lumen: an in vitro study. *Laryngoscope*. 2009;119:1339–43.
 30. Beilvert A, et al. A resorbably shape-memory starch-based stent for the treatment of salivary ducts under sialendoscopic surgery. *Laryngoscope*. 2014;124:875–81.

Andrew T. Day and David W. Eisele

Key Points

1. Sialadenitis is the most common side effect of radioiodine therapy occurring in 10–60% of treated patients.
2. The major salivary glands concentrate radioiodine at 20–100 times the level of serum.
3. Predominantly serous salivary glands such as the parotid are more susceptible to radioiodine damage than mixed or mucinous-predominant glands.
4. Pretreatment with recombinant thyroid-stimulating hormone (rTSH) may reduce radioiodine-related salivary toxicity.
5. Therapeutic sialendoscopy reduces symptoms and obstructive episodes in the majority (>50%) of patients with radioiodine-related sialadenitis.

Introduction

Radioiodine

Radioiodine (^{131}I) is a radioactive isotope of iodine, a naturally occurring chemical element that is preferentially taken up by and stored

within the thyroid gland to serve a critical role in thyroid physiology and human metabolism [1–4]. An isotope is “any of two or more species of atoms of a chemical element with the same atomic number and nearly identical chemical behavior but with differing atomic mass or mass number and different physical properties” [5]. Isotopes may be either stable or unstable. Nuclei of unstable, or radioactive, isotopes dissipate excess energy by spontaneously emitting radiation in the form of alpha, beta, and gamma rays [6]. Among the 37 different isotopes of iodine (^{108}I – ^{144}I), only ^{127}I is stable [7]. Given its preferential uptake by the thyroid gland, 8-day half-life, and toxic beta wave emission during decay, radioiodine (^{131}I) has been effectively harnessed for the treatment of benign and malignant thyroid disorders via the destruction of thyroid follicular cells [3, 7, 8].

Today, radioiodine (^{131}I) administration is indicated in certain patients with well-differentiated thyroid cancer and hyperthyroidism due to Graves’ disease, toxic adenoma, or toxic nodular goiter [9, 10]. Given the increased frequency of incidental radiologically identified thyroid nodules, the United States has seen a significant increase in the detection of well-differentiated thyroid cancer and its subsequent treatment with surgery and radioactive iodine when indicated [11]. Indeed, Davies et al. identified a near three-fold increase in the incidence of thyroid cancer in the United States from 1973 to 2002, from 2.7

A.T. Day, M.D. • D.W. Eisele, M.D., F.A.C.S. (✉)
Department of Otolaryngology-Head and Neck
Surgery, Johns Hopkins University School of
Medicine, 601 N. Caroline Street, Suite 6210,
Baltimore, MD 21287, USA
e-mail: deisele1@jhmi.edu

to 7.7 cases per 100,000 [12]. Approximately 38–61% of patients received radiobiologic treatment during this period [13].

Radioiodine is administered orally as a single dose of ^{131}I -labeled sodium iodide (Na^{131}I) in liquid or capsule form. Patients with well-differentiated thyroid cancer treated with a total thyroidectomy may be given radioiodine for remnant ablation, adjuvant therapy, or therapy for known disease, with doses ranging from 30 millicuries (mCi) to 200 mCi [13]. While radioiodine is generally well-tolerated, increased attention has been drawn to its adverse effects. Early toxicities include gastrointestinal symptoms, radiation thyroiditis, sialadenitis/xerostomia, bone marrow suppression, gonadal damage, dry eye, painless neck edema, tumor hemorrhage, and nasolacrimal duct obstruction. Late toxicities include second primary cancers, pulmonary fibrosis, and permanent bone marrow suppression [14, 15]. Among these, sialadenitis/xerostomia and nausea/vomiting occur most frequently, with an incidence of approximately 30% [14, 16].

Radioiodine Sialadenitis

Sialadenitis is defined as inflammation of the salivary glands and may present in acute, recurrent, or chronic forms [17, 18]. Chronic sialadenitis is the most common disorder of the major salivary glands, affecting approximately 1 in 20,000 patients [19]. Causes of chronic sialadenitis include sialolithiasis, ductal scar tissue and previous parenchymal damage from previous sialolithiasis, radiation exposure or radioiodine administration, ductal trauma, autoimmune disorders (such as Sjogren's syndrome and juvenile recurrent parotitis), anatomic anomalies, and foreign bodies [20]. Symptoms of chronic sialadenitis include recurrent, often postprandial, swelling and pain of the involved gland. This disorder is occasionally complicated by bacterial superinfection with mucopurulent drainage [19–21].

While sialolithiasis is the most common cause of chronic sialadenitis, the increased use of radioiodine has resulted in an increased incidence of radioiodine sialadenitis [19]. Symptoms

of radioiodine sialadenitis are characteristically pain, swelling, and xerostomia [22]. A range of 10–60% of patients report symptoms of acute or chronic salivary gland dysfunction after exposure [23]. The salivary glands experience greater toxicity than other tissues because the parenchymal and ductal cells contain a sodium/iodine symporter that accumulates ^{131}I in the saliva at concentrations of 20–100 times the levels found in plasma. Ultimately, an estimated 24% of radioiodine is lost through the saliva [24]. Due to exposure to radiation, the ductal epithelial cells as well as the salivary parenchymal cells experience acute and chronic inflammatory changes with subsequent duct lumen narrowing, stricture formation, and altered, more viscous saliva. These factors contribute to ductal blockage and salivary stasis [22]. Since serous acini are most susceptible to this injury, the parotid gland tends to be more affected than the submandibular gland [23].

Prevention

Methods of preventing radioiodine sialadenitis are debated. Van Nostrand originally proposed pretreatment and posttreatment approaches to mitigation of radioiodine sialadenitis. He suggested assessment of radioiodine uptake in the salivary glands on preablation whole body scans with potential treatment adjustment as indicated, patient education, aggressive hydration, and suspension of anticholinergic medications. After therapy, he recommended aggressive hydration, frequent sialogogues, gland massage, and use of one or more of the following medications: cholinergic agents, nonsteroidal anti-inflammatory agents, prophylactic steroids, amifostine, and reserpine [25]. Other studies, however, questioned the efficacy of these recommendations, particularly with regard to frequent sialogogues, pilocarpine, and reserpine [26–28].

Recent studies of patients receiving radioiodine for well-differentiated thyroid cancer suggest the use of recombinant human thyroid-stimulating hormone (rhTSH) postoperatively may induce less salivary gland toxicity as opposed to thyroid hormone withdrawal because

the latter group experienced transiently impaired renal function and subsequent decreased renal clearance of radioiodine. In fact, in one prospective study, only 5.4% of 148 patients receiving rhTSH experienced adverse oral symptoms [29]. Ultimately, however, uniform consensus regarding successful preventative measures for radioiodine sialadenitis has yet to be achieved.

Management

Management of radioiodine sialadenitis is first medical. Medical therapy is intended to reduce the severity of symptoms and includes hydration, gland massage, application of warm heat, anti-inflammatories, and cholinergic medications. Antibiotics are administered should bacterial infection occur [23, 25, 30].

Interventional sialendoscopy is beneficial to most patients whose symptoms are refractory to medical management. In our experience, the procedure is best performed under general anesthesia. The ductal lumen is inspected thoroughly with a diagnostic sialendoscope. Typical endoscopic findings included pale ductal mucosa, thick mucus plugs, ductal debris, and ductal stenosis (Fig. 8.1). Salivary dilators and the sialendoscope may mechanically expand the duct

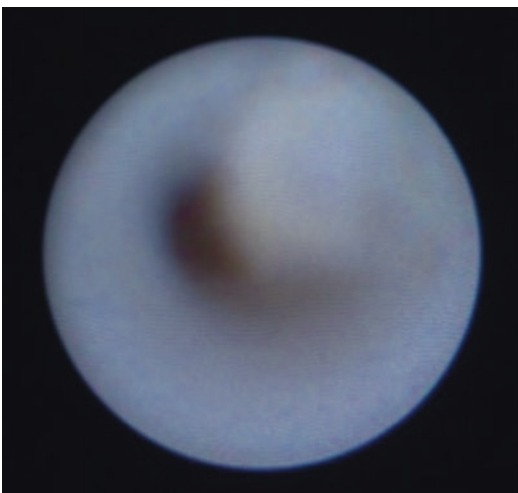


Fig. 8.1 Sialendoscopic appearance of parotid duct with characteristic findings of narrowed, pale duct with mucous plug due to radioiodine sialadenitis

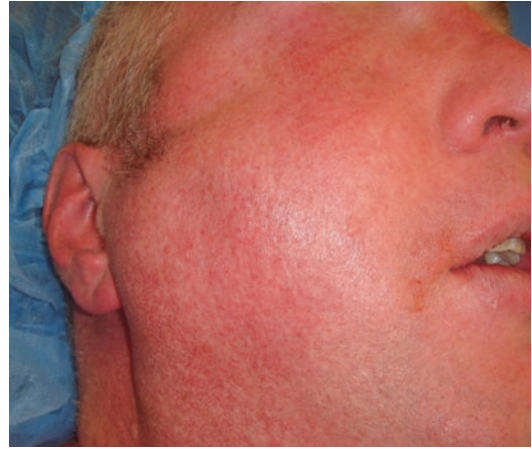

Fig. 8.2 Hydraulic expansion of the parotid gland

while sterile saline is introduced to hydraulically expand the ducts and engorge the gland (Fig. 8.2). Steroids can be instilled although the benefits of steroids are not well characterized. Some patients may benefit from several sequential procedures. Sialadenectomy is reserved for patients with severe symptoms that do not resolve with sialendoscopy.

Sialendoscopy Outcomes

According to the studies listed in Table 8.1, 50–100% of patients undergoing sialendoscopy for radioiodine sialadenitis report improvement in sialadenitis symptoms [22, 23, 30–35]. Three studies reported complete resolution of symptoms in 55–100% of patients [22, 23, 31]. While almost all studies validated the use of sialendoscopy for these patients, a study of 12 patients by Kim et al. demonstrated that sialendoscopy consistently provided no benefit in some sialadenitis outcome measures. Their patients reported a significant improvement in obstructive symptoms but no improvement in xerostomia symptoms, unstimulated salivary flow rate, or salivary gland scintigraphy [35]. Among patients within all studies, the cumulative doses of radioiodine administered ranged from 125 to 250 mCi [33, 34]. Four studies demonstrated follow-up of greater than 1 year in some of their patients, suggesting symptom relief may be long-lasting [22, 23, 30, 31]. According to

Table 8.1 Selected studies assessing interventional sialendoscopy for patients with radiation sialadenitis

Group	Year	Sample size	Total glands	Additional interventions	Follow-up	% Improved symptoms	% Symptom free	Other
Nahlieli et al.	2006	15	NR	Hydrocortisone 100 mg irrigation	Range: 1–4 years	100%	100%	
Kim et al.	2007	6	NR	None	Range: 8–10 months	50%	NR	
Bomeli et al.	2009	12	NR	Triamcinolone 40 mg	Median: 6 months	75%	NR	Balloon dilation used
Prendes et al.	2012	11	28	None	Mean: 7–18 months	91%	55%	
DeLuca et al.	2014	30	75	Hydrocortisone solution irrigation	Range: 2 weeks–84 months	77%	NR	
Bhayani et al.	2015	26	68	Kenalog-40 irrigation	Median: 23.4 +/– 12.1 months	92%	64%	Improved unstimulated saliva production at 6 months
Wu et al.	2015	12	19	Gentamicin irrigation	NR	92%	NR	Stent left in for 2 weeks postoperatively
Kim et al.	2016	10	15	NR	3 months	NR	NR	See text

De Luca et al. and Bomelli et al., the most common causes of recurrence were ductal stenosis and mucus plugs [30, 33].

Ultimately, while all studies to date report improved symptoms in at least half of patients undergoing sialendoscopy, additional higher-powered studies are needed to further assess the degree, quality, and length of symptom improvement. The studies are further limited by the lack of a validated objective measure of symptoms and the various administered treatments prohibiting direct comparison of outcomes.

Conclusion

Sialendoscopy is effective in providing symptomatic relief to a majority of patients with radioiodine sialadenitis not responding to conservative medical therapy.

References

- Ahad F, Ganie SA. Iodine, Iodine metabolism and iodine deficiency disorders revisited. *Indian J Endocrinol Metab.* 2010;14(1):13–7.
- Cavalieri RR. Iodine metabolism and thyroid physiology: current concepts. *Thyroid.* 1997;7(2):177–81.
- American Thyroid Association. Radioactive iodine. <http://www.thyroid.org/radioactive-iodine/>. Accessed 31 Jan 2016.
- Van Dyke M, Punja M, Hall MJ, Kazzi Z. Evaluation of toxicological hazards from medical radioiodine administration. *J Med Toxicol.* 2015;11(1):96–101.
- Merriam-Webster. Isotope. <http://www.merriam-webster.com/dictionary/isotope>. Accessed 1 June 2016.
- Encyclopædia Britannica. Radioactive isotope. 2016. <http://www.britannica.com/science/radioactive-isotope>. Accessed 31 Jan 2016.
- Audi GWA, Thibault C, Blachot J, Bersillon O. The NUBASE evaluation of nuclear and decay properties. *Nucl Phys A.* 2003;729:3–128.
- Suwinski R, Gawkowska-Suwinska M. Radiobiologic basis for using ¹³¹I to treat patients with thyroid cancer. *Wiad Lek.* 2001;54(Suppl 1):266–77.
- Haugen BR, Alexander EK, Bible KC, Doherty GM, Mandel SJ, Nikiforov YE, et al. 2015 American Thyroid Association management guidelines for adult patients with thyroid nodules and differentiated thyroid cancer: The American Thyroid Association guidelines task force on thyroid nodules and differentiated thyroid cancer. *Thyroid.* 2016;26(1):1–133.
- Ross DS. Radioiodine therapy for hyperthyroidism. *N Engl J Med.* 2011;364(6):542–50.
- Alexander EK, Larsen PR. Radioiodine for thyroid cancer—is less more? *N Engl J Med.* 2012;366(18):1732–3.
- Davies L, Welch HG. Increasing incidence of thyroid cancer in the United States, 1973–2002. *JAMA.* 2006;295(18):2164–7.
- Patel SS, Goldfarb M. Well-differentiated thyroid carcinoma: the role of post-operative radioactive iodine administration. *J Surg Oncol.* 2013;107(6):665–72.
- Fard-Esfahani A, Emami-Ardekani A, Fallahi B, Fard-Esfahani P, Beiki D, Hassanzadeh-Rad A, et al. Adverse effects of radioactive iodine-131 treatment for differentiated thyroid carcinoma. *Nucl Med Commun.* 2014;35(8):808–17.
- Sherman SI. Thyroid carcinoma. *Lancet.* 2003;361(9356):501–11.
- Klein Hesselink EN, Links TP. Radioiodine treatment and thyroid hormone suppression therapy for differentiated thyroid carcinoma: adverse effects support the trend toward less aggressive treatment for low-risk patients. *Eur Thyroid J.* 2015;4(2):82–92.
- Francis CL, Larsen CG. Pediatric sialadenitis. *Otolaryngol Clin N Am.* 2014;47(5):763–78.
- Wilson KF, Meier JD, Ward PD. Salivary gland disorders. *Am Fam Physician.* 2014;89(11):882–8.
- Vashishta R, Gillespie MB. Salivary endoscopy for idiopathic chronic sialadenitis. *Laryngoscope.* 2013;123(12):3016–20.
- Gillespie MB, O'Connell BP, Rawl JW, McLaughlin CW, Carroll WW, Nguyen SA. Clinical and quality-of-life outcomes following gland-preserving surgery for chronic sialadenitis. *Laryngoscope.* 2015;125(6):1340–4.
- Aubin-Pouliot A, Delagnes EA, Eisele DW, Chang JL, Ryan WR. The chronic obstructive sialadenitis symptoms questionnaire to assess sialendoscopy-assisted surgery. *Laryngoscope.* 2016;126(1):93–9.
- Prendes BL, Orloff LA, Eisele DW. Therapeutic sialendoscopy for the management of radioiodine sialadenitis. *Arch Otolaryngol Head Neck Surg.* 2012;138(1):15–9.
- Bhayani MK, Acharya V, Kongiatkamon S, Farah S, Roberts DB, Sterba J, et al. Sialendoscopy for patients with radioiodine-induced Sialadenitis and Xerostomia. *Thyroid.* 2015;25(7):834–8.
- Mandel SJ, Mandel L. Persistent sialadenitis after radioactive iodine therapy: report of two cases. *J Oral Maxillofac Surg.* 1999;57(6):738–41.
- Van Nostrand D. Sialoadenitis secondary to ¹³¹I therapy for well-differentiated thyroid cancer. *Oral Dis.* 2011;17(2):154–61.
- Nakada K, Ishibashi T, Takei T, Hirata K, Shinohara K, Katoh S, et al. Does lemon candy decrease salivary gland damage after radioiodine therapy for thyroid cancer? *J Nucl Med.* 2005;46(2):261–6.
- Silberstein EB. Reducing the incidence of ¹³¹I-induced sialadenitis: the role of pilocarpine. *J Nucl Med.* 2008;49(4):546–9.
- Kim SJ, Choi HY, Kim IJ, Kim YK, Jun S, Nam HY, et al. Limited cytoprotective effects of amifostine

- in high-dose radioactive iodine 131-treated well-differentiated thyroid cancer patients: analysis of quantitative salivary scan. *Thyroid*. 2008;18(3):325–31.
29. Rosario PW, Calsolari MR. Salivary and lacrimal gland dysfunction after remnant ablation with radioactive iodine in patients with differentiated thyroid carcinoma prepared with recombinant human thyrotropin. *Thyroid*. 2013;23(5):617–9.
 30. De Luca R, Vicidomini A, Trodella M, Tartaro G, Colella G. Sialoendoscopy: a viable treatment for I(131) induced sialoadenitis. *Br J Oral Maxillofac Surg*. 2014;52(7):641–6.
 31. Nahlieli O, Nazarian Y. Sialadenitis following radioiodine therapy—a new diagnostic and treatment modality. *Oral Dis*. 2006;12(5):476–9.
 32. Kim JW, Han GS, Lee SH, Lee DY, Kim YM. Sialoendoscopic treatment for radioiodine induced sialadenitis. *Laryngoscope*. 2007;117(1):133–6.
 33. Bomeli SR, Schaitkin B, Carrau RL, Walvekar RR. Interventional sialendoscopy for treatment of radioiodine-induced sialadenitis. *Laryngoscope*. 2009;119(5):864–7.
 34. CB W, Xi H, Zhou Q, Zhang LM. Sialendoscopy-assisted treatment for radioiodine-induced sialadenitis. *J Oral Maxillofac Surg*. 2015;73(3):475–81.
 35. Kim YM, Choi JS, Hong SB, Hyun IY, Lim JY. Salivary gland function after sialendoscopy for treatment of chronic radioiodine-induced sialadenitis. *Head Neck*. 2016;38(1):51–8.

Trevor Hackman

Key Points

1. Salivary duct trauma is the most common complication of sialendoscopy.
2. The ostium and distal duct have the smallest caliber and are the most susceptible sites to ductal perforation.
3. Lasers can be a source of ductal wall trauma due to inadvertent thermal spread to the ductal wall.
4. Controlled opening of the duct for stone extraction (combined approach) will result in less duct trauma than excessive endoscopic instrumentation in an attempt to remove an impacted stone.

dibular duct has been recorded as 58 mm, and the mean widths of the proximal, mid-, and distal segments of the submandibular duct have been estimated to be 2.0 mm, 2.7 mm, and 2.1 mm, respectively [1]. While Wharton's duct has a thin compressible duct wall, it has excellent elastic properties making it ideal for dilation. As it courses through a submucosal space, the one focal area of compression comes as it courses over the free posterior edge of the mylohyoid, a common site for sialolith formation, where the average angle of the duct turn is 115° [1]. Finally, there is a variance in the papilla anatomy, as some patients have redundant mucosa limiting visibility and access to the orifice of the duct, while other patients may have limited papilla height.

Anatomy

Wharton's Duct

Wharton's duct extends from the hilum of the submandibular gland around the free posterior edge of the mylohyoid muscle in the submucosal space of the posterior floor and then courses anteriorly to terminate at the mucosal papilla in the anterior floor of mouth. The average length of the subman-

Stensen's Duct

Stensen's duct originates between the superficial and deep lobes of the parotid gland and courses over the masseter muscle, piercing the buccinator muscle to enter the submucosal of the cheek before terminating at the papilla lateral to the maxillary premolar. Stensen's duct has an average length of 50 mm and the mean widths of the proximal, mid-, and distal segments of the parotid duct have been measured as 1.8 mm, 1.1 mm, and 1.6 mm [1]. In addition to its narrow caliber, the parotid duct wall is also thicker and much less elastic, decreasing its capacitance for dilation and manipulation.

T. Hackman, M.D., F.A.C.S.
Department of Otolaryngology—Head and Neck
Surgery, University of North Carolina,
G108 Physicians Office Building, 170 Manning
Drive, Chapel Hill, NC 27599-7070, USA
e-mail: trevor_hackman@med.unc.edu

Risk Factors for Duct Trauma

With the unique anatomy of these two ducts, the trauma profile is distinctly different. Wharton's duct is larger in caliber, and resides within a pliable submucosal space, allowing for great capacitance for dilation. However, the orifice may be difficult to find and access due to the variance in pliability and volume of the papilla anatomy. In addition, the mylohyoid muscle edge, which separates the gland into its floor of mouth and neck components, creates a sharp angle in the duct, which will trap stones and may limit scope access or stone removal. Therefore, the high-risk zones for trauma are at the papilla and in the posterior floor of mouth. Patients are at risk for papillary stricture with overaggressive manipulation of the papilla, and this has led some to advocate a control ductotomy and formal sialodochoplasty proximal to the native papilla for all submandibular duct procedures [2]. In the posterior floor of mouth, the risks include bleeding (facial system), lingual nerve injury, trapped basket, and delayed duct stricture [3].

In contrast to Wharton's duct, access and dilation of the Stensen's duct papilla is typically straightforward. However, the potential tortuous contour of the duct over the masseter muscle may significantly limit further probe or scope manipulation. In patients with a prominent mandibular ramus and masseter muscle, the degree of angulation required to navigate over the anterior edge of masseter may be severe and challenging. As the scopes are semirigid, over torque can lead to ductal damage or scope fracture. Access is further limited by the smaller caliber of the ductal system and its limited capacitance for acute dilation due to its thicker duct wall and firmer, more constraining surrounding soft tissue anatomy (muscle, mandible, and parotid tissue).

Finally, these ducts are also at risk during oncologic resections and trauma [4]. In the management of oral cavity cancer, the submandibular duct is often an innocent victim of oncologic resection. In cases where the submandibular gland will not be removed during neck dissection, but the duct is violated during mucosal resection, efforts should be made to preserve submandibular outflow. Similarly, in the management of malignancy with buccal involvement, where the parotid gland will be preserved, efforts should be made to identify the parotid duct, reroute it to the oral

cavity, and preserve outflow. Additional iatrogenic causes include inadvertent trauma during facelift surgery or duct transection during external cheek skin cancer resection. Penetrating trauma to the face may result in parotid duct injury, which should be suspected when patients display frank salivary leak from the facial wound or weakness of the midface musculature to suggest facial nerve (buccal branch) injury.

Duct Trauma Profile

Tears/Abrasions

Minor tears and abrasions are inherent with salivary duct surgery (Fig. 9.1). As mentioned above, the high-risk zone for tears and abrasions in Wharton's duct is the papilla, as access can sometimes be challenging and the temptation to grasp the papilla with forceps may be high. A traumatized papilla will bleed and swell. Once the duct endothelial connection to the floor of mouth is disrupted, the ductal opening will collapse, making it virtually impossible to continue access and dilation as further attempts will result in false passage of dilators into the submucosa. There should be no resistance to passing a dilator into the duct, unless the orifice is blocked by stone or stricture, but the false passage dilation will be with resistance. If not perceived by the practitioner, further dilations may proceed with less resistance and a larger false passage tract may be created.

While prevention of injury will be reviewed later in the chapter, briefly, there are some techniques, which reduce the risk of perforation/trauma: gentle handling of the tissues, grasping and stabilizing mucosa away from the papilla, starting with small dilators and gradually increasing the dilator diameter, only removing the prior dilator once the subsequent dilator is ready for insertion (orifice easily collapses after removal of the dilator), passing the dilator tip just enough to dilate the ostium (passage of the full length of the dilator is the most common cause of perforation), and using methylene blue to localize the orifice.

Internal duct abrasions, if not circumferential, will heal within 1–2 weeks. However, circumferential abrasions can lead to stenosis or stricture. Duct abrasions occur with overaggressive or

Fig. 9.1 Sialendoscopy view of the parotid duct showing white purulent debris obscuring the proximal lumen and erythematous abrasion of along the duct lumen from 6 to 8 o'clock

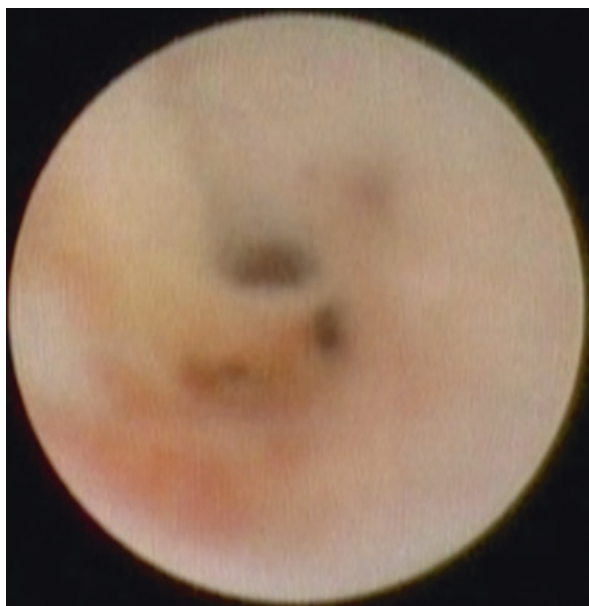
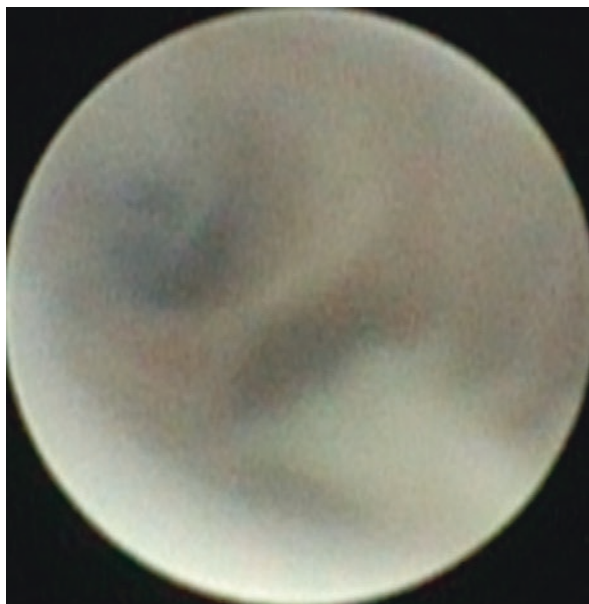


Fig. 9.2 Endoscopic view of the parotid duct during laser lithotripsy. Note the cloudy, obscured view created during laser activation



blinded endoscopy, uncontrolled instrumentation in the duct, or continued wire basket retrieval of a stone against resistance. Scope-related duct abrasions are more frequently seen in the parotid system, where the duct is more tortuous, narrow, and thicker walled. Blind scope advancement against resistance will damage the endothelium and may lead to perforation. In the case of stone management, hand drills and lasers have been proposed for reducing the stone caliber to afford endoscopic removal. As the ducts are pliable, the scope view

dynamic, fracturing the stone with a laser or drill is challenging and time-consuming. In addition, both methods include increase force or energy within a confined space, which increases the risk for ductal trauma, particularly given the cloudy view often seen with laser therapy (Fig. 9.2). The stones may suddenly move, traumatizing the duct or exposing the duct to direct trauma from the drill or laser. Such techniques are challenging and carry a high risk of duct trauma, and therefore should only be employed by experienced sialendoscopists.

Perforations

Duct perforations are a severe form of duct trauma which may make it more difficult to continue the procedure [5]. As mentioned above, overaggressive instrumentation with drills, lasers, or even the scope, can lead to perforations. The use of rigid instrumentation in pliable anatomy under a dynamic endoscopic view with hydrostatic pressure places patients at risk for perforation. In the setting of dilation, perforation occurs when salivary dilators are advanced against resistance into the orifice. The small, 0000, lacrimal probe will advance through soft tissue without much resistance once it breaks through the duct wall. Scope perforations typically occur when a practitioner attempts to advance the scope against resistance. The classic scenario for this is the treatment of parotid strictures, where the practitioner attempts to navigate the scope through the stricture and thereby dilate it. As the scope approaches the area of stricture, invariably the luminal view is lost, as the scope typically contacts the stricture wall. Attempts to push through the stricture may result in the scope puncturing the duct wall and a resultant

false passage. When this occurs, the luminal view is lost and instead lobules of fat are seen within a network of white, cobweb-like, fibrous bands (Figs. 9.3 and 9.4). Perforations may also paradoxically occur with the use of lasers and hand drills in an attempt to avoid a ductotomy by using a purely endoscopic approach to the treatment of sialolithiasis. The hand drill requires force to break the stone. Overaggressive force can push the stone into the duct wall, further impacting it and traumatizing the duct. The drill may also slip off the stone and directly puncture the duct view. The use of laser for stone fragmentation poses an even high risk for duct trauma/perforation, as the energy disperse will be partly absorbed by the duct wall. The laser fragmentation takes time, as the wavelength of the laser is not ideal for stone fragmentation. Therefore, the duct may absorb significant energy, which is somewhat offset by irrigation. In addition, the laser energy may abruptly move the stone, resulting in motion trauma to the duct, or opening the duct to direct laser trauma. As the stone moves or fragments, it becomes easier to inadvertently laser the duct wall, which will lead to debris and endothelial sloughing. During the laser treatment,

Fig. 9.3 Endoscopic view of a parotid duct following perforation. Cobweb-like debris filling the view indicates ductal damage and possible perforation

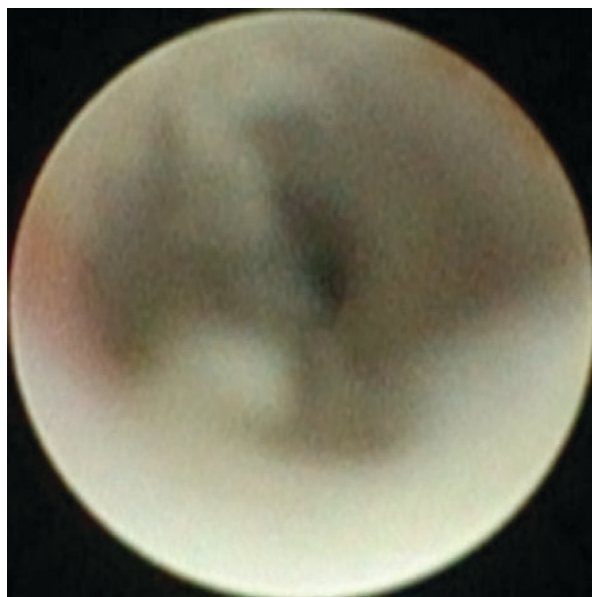


Fig. 9.4 Endoscopic view of a parotid duct following perforation. Cobweb-like debris and yellow fat in the view indicates possible perforation

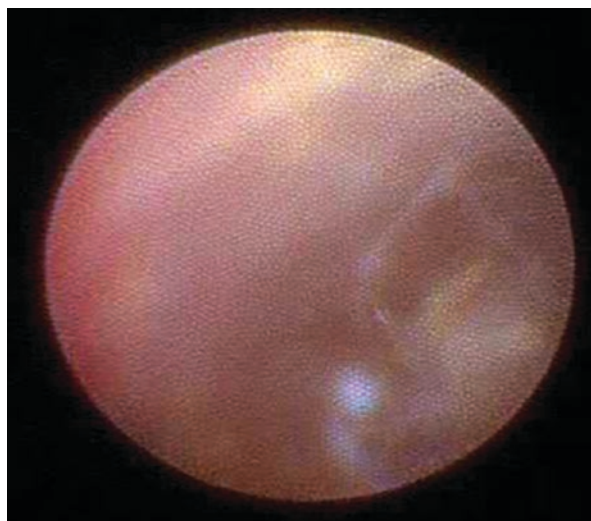
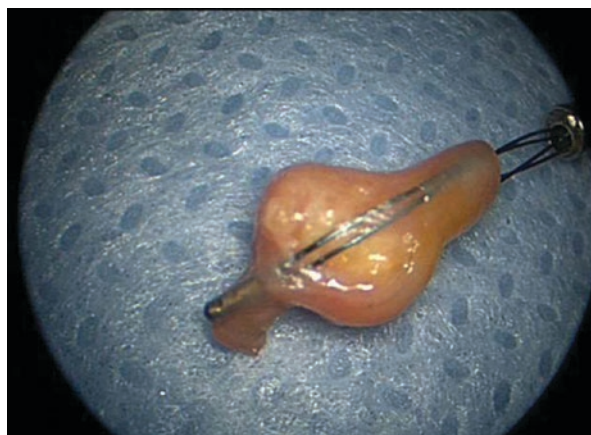

Fig. 9.5 Inadvertent submandibular duct avulsion during attempted wire basket retrieval of a submandibular stone. Ex vivo appearance of the stone and wire basket within the duct on the back table



the endoscopic view becomes more challenging due to the turbulence of the fluid and the generation of a debris, obscuring view, similar to how a breaking wave clouds the view of the ocean floor. As the view is often poor/cloudy during the laser pulse, inadvertent duct trauma is likely and thus may quickly lead to perforation.

a proximal submandibular duct stone with wire basket. This can occur if the basket gets stuck behind a stone fixed to the duct wall or if forceful attempts are made to retrieve a stone through a small or strictured duct. If enough force is placed on the wire basket, the duct will rupture and release out of the floor of mouth with the stone and basket (Fig. 9.5).

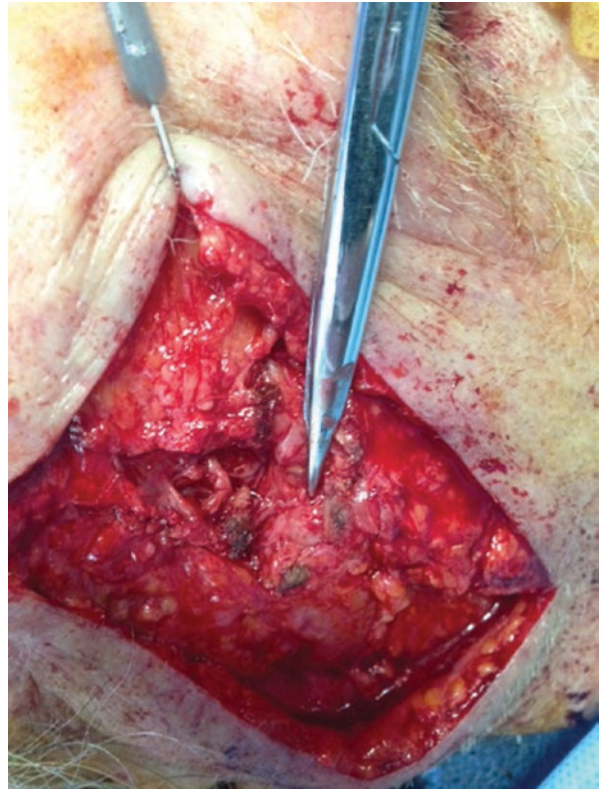
Avulsion

This is a rare and very preventable complication seen in the submandibular system. The mechanism for avulsion is an aggressive attempt at removing

Oncologic Trauma

During mucosal resection of malignancy in the floor of mouth or buccal mucosa, the salivary ducts are at risk. Sound oncologic principles

Fig. 9.6 Traumatic transection of the parotid duct during Mohs resection- lumen of the transected duct indicated by the tip of the scissors



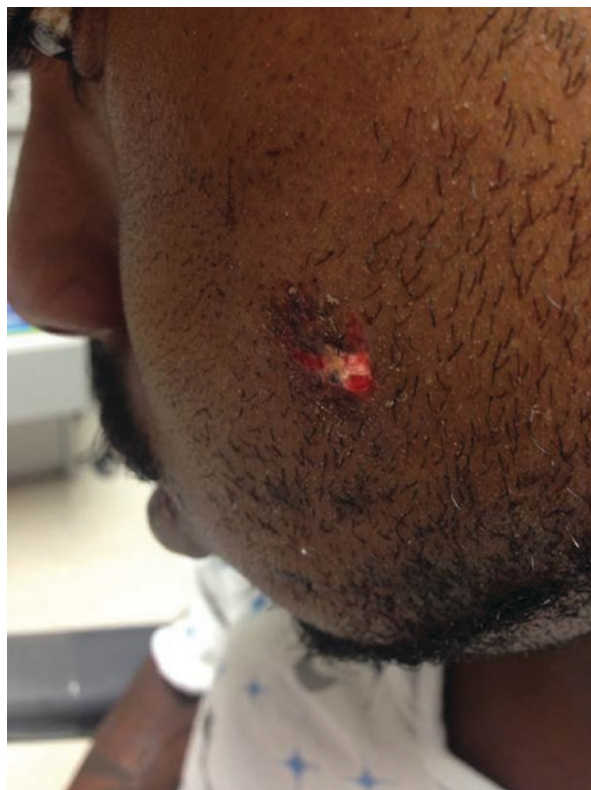should always dictate the resection margins. However, attention should be placed toward the location of the salivary duct punctum, and if preservation is possible, the punctum should be spared. When the punctum cannot be spared, efforts should be made to identify the duct in the submucosal space for future marsupialization if the intention is to preserve the gland. Otherwise, the patient may suffer glandular swelling, pain, and sialoceles or fistula formation [6]. Likewise, Stensen's duct can be traumatized during the resection of deeply infiltrative cutaneous malignancies of the external cheek (Fig. 9.6). Cannulating the duct prior to resection with a stent may help to identify the duct and allow direct repair in the event that the ductal wall is entered. If a portion of the duct requires sacrifice for oncologic margin, it is best to identify and formally ligate the stumps of the duct in

order to avoid salivary fistula. Injection of botulinum toxin A (100 units in 2 mL of sterile saline) over several locations in the remaining glandular tissue may reduce the short-term swelling and obstruction expected after ligation, and may hasten the natural involution of the remaining tissue [7].

Penetrating Trauma

Knife, gunshot, and degloving injuries to the face may involve the parotid duct [8], as it courses over the fixed complex of the masseter and mandible (Fig. 9.7). Indications for exploration include frank salivary leak, facial nerve injury, or full-thickness cheek injury [9]. Unmanaged, the trauma may lead to a chronic salivary fistula, infection, or stricture.

Fig. 9.7 Persistent salivary fistula following gunshot wound trauma



Consequences of Ductal Trauma

When trauma occurs across the spectrum listed above, there are a variety of short-term and long-term consequences that may occur. They should therefore receive appropriate preoperative counseling as to the risks of the procedure.

Pain

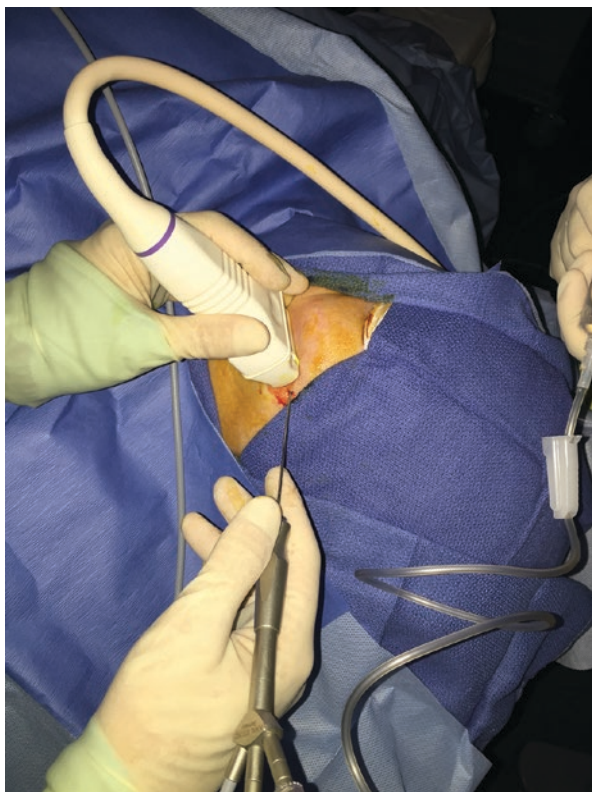
Endoscopy alone should not lead to pain. Scope-related perforation rates in North America (estimated 3–5%) may be slightly higher than what is observed in Germany (estimated 1–2%) since most North American endoscopies are performed under general anesthesia thereby preventing the patient from indicating pain which precedes a scope-related perforation. Although endoscopic

stone removal may require a controlled ductotomy or papilla incision, the degree of discomfort from this should be minor. Minor tears and duct abrasions are unlikely to result in pain.

Swelling

Mild gland swelling may be seen after endoscopy due to the continuous infusion used during the case. This can be reduced by taking time to massage excess irrigation from the gland during the course of the procedure. Although some swelling is expected, it is typically not associated with pain, and is self-resolving within 24–48 h. Focal facial or floor of mouth swelling will occur with duct perforation, and should be an indication to abort the procedure, or use an alternative technique. In cases of early recognized trauma

Fig. 9.8 Ultrasound guided percutaneous parotid sialendoscopy over a guidewire for treatment of a parotid stricture



without significant perforation or extravasation, the swelling will be limited and self-resolving over the week following the procedure. However, in the case of significant Wharton's duct perforation, with floor of mouth swelling, an incision should be made in the floor of mouth mucosa to drain the fluid. The duct can then be identified, a small sialodochoplasty performed, and the scope reinserted to complete the case.

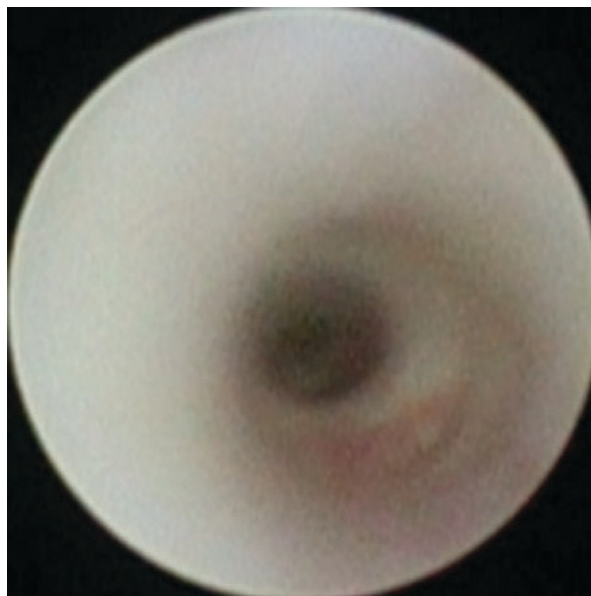
In the case of significant Stensen's duct perforation, the scope should be backed out of the perforation; continuous irrigation should stop to reduce fluid dissection and compression of the normal duct; a guidewire should then be passed down the normal lumen if visible followed by passage of several malleable dilators in order to allow the normal lumen and not the perforation to become the path of least resistance. If the normal lumen is not visible, ultrasonography can be performed of the parotid gland. If the duct is visible on ultrasound proximal to the perforation,

ultrasound guided needle placement of a guidewire can be performed to facilitate antegrade or retrograde dilation or endoscopy (Fig. 9.8). This will then allow the case to be completed. Stenting in the area of the perforation for 1 week will promote healing and reduce the chance of a sialoceles or salivary fistula.

Stenosis/Stricture

Salivary stenosis or stricture is a delayed complication from ductal trauma (Fig. 9.9) [10]. The common areas for duct stenosis or stricture are the papilla, prior sialolith location, ductotomy or marsupialization site, or the submandibular hilum at the posterior edge of the mylohyoid. These occur from excessive duct trauma, which is often circumferential, and are more likely to be seen in patients with low-volume salivary flow. Patients with swelling,

Fig. 9.9 Endoscopic view of the parotid duct showing delayed partial stenosis following spontaneous passage of a salivary stone



tearing, and/or bleeding at the papilla after the procedure are at a higher risk for stenosis or stricture. Often Wharton's duct marsupialization is performed to prevent stricture. However, if the closure is under tension, not performed meticulously, or the duct endothelium is traumatized, stenosis may nevertheless occur.

Sialocele/Salivary Fistula

A sialocele or fistula may occur after salivary procedures, oncologic resection, or trauma and is typically the result of a multilevel problem (Fig. 9.10a, b). Simply stated, it is the leak of saliva from the duct, which translates into either facial swelling with or without drainage in the parotid system or floor of mouth swelling in the case of the submandibular system. In severe cases, patients may develop sialadenitis requiring antibiotic therapy, and even gland excision.

The parotid sialocele is uncommon following accidental duct perforation if detected early and the case aborted. Sialocele is most often seen after a transfacial sialolithotomy, since it

is difficult to repair the duct in a watertight fashion without causing a stricture. However, sialocele is not common with this procedure, as the saliva will often follow the path of least resistance, which should be luminally out the duct into the mouth. Therefore, when a sialocele occurs, it is often suggestive of ductal obstruction to flow distal to the ductotomy site. In regards to Wharton's duct, the same rules of fluid flow dynamics apply, yet sialocele is much less common. Ductal obstruction distal to a prior ductotomy site will lead to saliva egress out of the ductotomy site. If the overlying mucosa heals, as often happens in the posterior floor of mouth, the saliva will collect in the submucosal space and result in ranula formation. Patients may report cyclic increasing swelling and/or pressure in the floor of mouth with periodic bursts of turbid flow and subsequent transient relief of the swelling.

Trauma or transection of the duct during cancer resection or penetrating injury is common. If larger injuries are not detected, and the gland is preserved, the patient will develop a sialocele, fistula, or in some cases an acute painful sialadenitis.

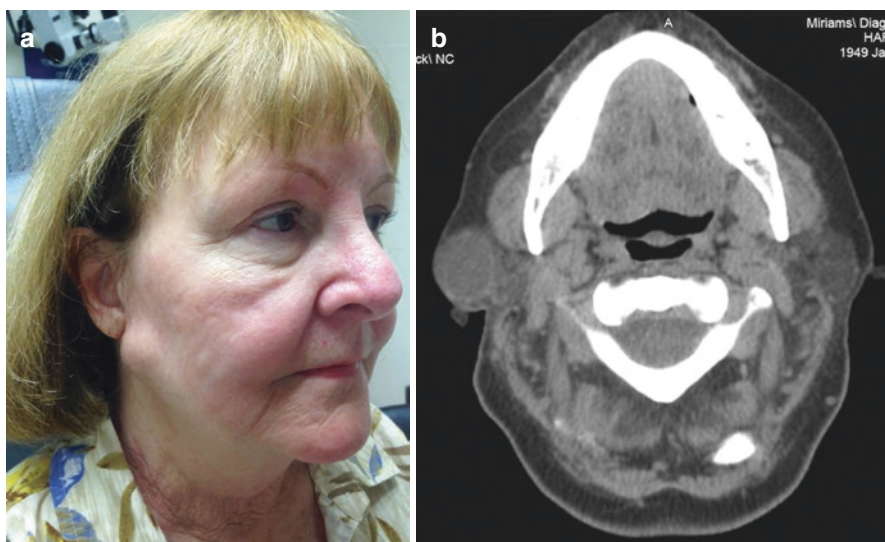


Fig. 9.10 (a) Parotid sialocoele formation after laser lithotripsy of a proximal ductal stone. (b) Axial CT scan at the level of the parotid gland displaying a cystic

lesion in the location of the right parotid gland, consistent with a sialocoele

Prevention

While duct trauma is a risk with salivary surgery, most trauma is preventable. Patience and proper technique are essential. As with any procedure, the practitioner should have a management algorithm to address varying degrees of procedural complexity and know his or her limits. The papilla is the gateway for salivary endoscopy and thus care must be taken to adopt “good practice” with papilla management. The recommended algorithm starts with a “no touch” technique, where the practitioner uses salivary probes or tapered dilators to access the duct with gentle probing [11]. Massage of the gland to produce flow may help with orifice identification. If the orifice is not apparent or the mucosal mound of the papilla prevents access, a controlled submucosal injection of local anesthesia in the floor of mouth anterior and inferior to the papilla (injection site should be far enough away to prevent confusion with orifice) will create a temporary increase in papilla turgor and simplify orifice identification, probe access and dilation. In addition,

methylene blue may be placed in the anterior floor of mouth to aid in identification of the ostium. Alternatively, a separate mucosal incision posterior to the papilla in the floor of mouth with controlled longitudinal ductotomy with secondary sialodochoplasty also affords access. Grasping, incising, or removing the papilla for access is not advised, as the wound created is at a high risk for stricture formation. When probe access is challenging, a guidewire may be used in Seldinger fashion followed by dilation over the guidewire. Probes and dilators need only pass 5–10 mm into the duct for the purpose of dilation. This prevents stone dislodgement and blinded duct trauma.

Once in the duct, care must be taken to only advance the scope under direct visualization, as is practiced with rigid esophagoscopy. In cases of salivary stricture, a guidewire may be useful to guide the sialendoscope through the stricture segment and avoid perforation. In complex cases of parotid salivary stricture and sialectasia, ultrasound guidance is an extremely useful tool. A dilated parotid duct, guidewire, dilators, and the

sialendoscope are easily visible on ultrasound. Therefore, when difficult strictures are encountered, the ultrasound can be used to guide the instruments through the stricture and minimize the risk of duct perforation.

In regard to stone management, the practitioner again needs to display patience. If a drill or laser is employed, the practitioner must limit pressure and energy on the duct, expect longer procedural time, and stay vigilant with regard to maintaining luminal view of the stone. The hand drill and laser may avoid a floor of mouth incision but increase the risk of duct trauma and the length of the procedure. Since the duct is not a rigid structure, the stone tends to move during drilling and laser treatment. The stone motion may lead to duct trauma by direct pressure from the stone or by movement of the stone out of the path of the treatment, resulting in direct trauma to the duct by the drill or laser, which may result in severe trauma or perforation. The duct should be examined throughout treatment and if a perforation is detected, infusion should cease. The practitioner also must recognize when progress stalls and have a backup plan for management. The surrounding soft tissue should be examined for floor of mouth edema in the case of Wharton's duct and facial or buccal edema in the case of Stensen's duct

procedures. If recognized early and the case aborted, duct perforations will heal and are unlikely to result in long-term consequences.

Treatment

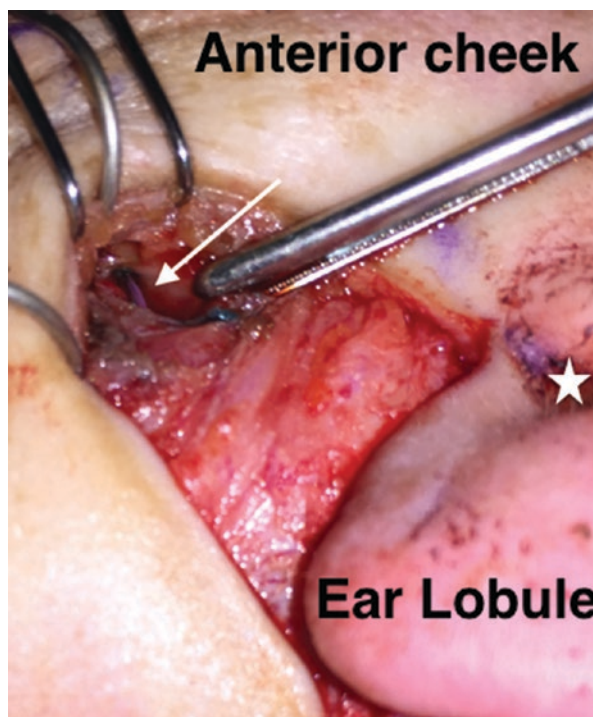
Salivary Procedures

When duct trauma occurs, the practitioner must have a plan for treatment and monitoring of the patient. If significant duct or papillary trauma is suspected, it is advisable to perform a formal marsupialization of healthy duct endothelium to oral mucosa and consider temporary stent placement. This may require cutting proximally to find healthy duct endothelium. Stent placement is controversial. In the submandibular system, the duct has the capacitance to allow for larger bore stents and therefore salivary flow is not limited. However, often the stents are removed 2 weeks after the procedure; at a time during which healing has not matured and collagen cross-linking has not occurred. Therefore, a well done sialodochoplasty is more vital to long-term patency (Fig. 9.11). In the parotid system, ductal trauma can be treated with stent placement [5]. Unfortunately, the caliber of the duct is so small that there are few

Fig. 9.11 Marsupialization of the right anterior submandibular duct to the anterior floor of mouth mucosa with 5-0 Chromic suture

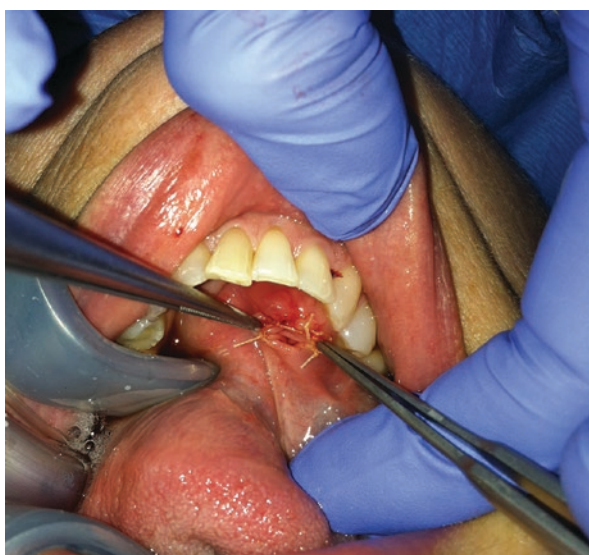

Fig. 9.12 Operative view of the left parotid following transfacial removal of an impacted stone displaying use of a pediatric 3 Fr feeding as a temporary duct stent (arrow)



options. Facial nerve monitoring is recommended given the proximity of the buccal branch of the facial nerve to the duct. The most popular stent is a pediatric 3 Fr feeding tube (Fig. 9.12), but even its lumen is small and has a high chance of clogging. Other options include angiocatheters, Silastic tubing, or various commercially available salivary stents. When a ductotomy is performed, primary repair with a 7-0 or 8-0 suture is recommended, and may be performed with absorbable or permanent suture [12]. Some practitioners who are concerned about sialocele formation after ductotomy will apply pressure dressings and/or dose the parotid gland with Botox (60–100 units) to decrease salivary outflow with the understanding that the onset of action will take 1 week and the duration may last 3 months [7].

Extrinsic Trauma

When the duct is transected during oncologic surgery and the gland is still functional, the lumen of the transected duct should be tagged. At completion of the surgery, the duct should be rerouted to the oral cavity surface and approximated to the

mucosa or flap skin at the surface. For parotid cases, given the circumferential anastomosis and risk for stricture, a long-term stent and Botox therapy to the gland are advisable.

In cases of penetrating facial trauma, the patient must be stabilized first. Exploration of the facial wounds should occur after the patient is otherwise stabilized and cleared. Antibiotic prophylaxis to oral flora (amoxicillin/clavulanate potassium) is recommended. Efforts should be made to identify facial nerve branches and the duct. Facial nerve monitoring may be helpful in cases of acute trauma. Often magnified visualization is needed with microscope or surgical loupes. Once identified, attempts should be made at primary repair of the duct over a stent. Again, Botox is advisable to decrease salivary outflow. If the duct trauma is too severe for direct repair, an interpositional vein graft may be used [13], but the long-term results with this are mixed, and in some cases proximal duct ligation with Botox therapy is the preferred management option. Finally, sialendoscopy may assist with major duct repair. Diagnostic sialendoscopy can be used to assess duct continuity immediately following repair and in the months following the procedure.

Treatment of Sialoceles

If a sialocele forms, intervention is required, as this fluid collection will not resolve spontaneously. First and foremost, the practitioner should confirm that patency, continuity, and integrity of the ductal system have been restored. Saliva will follow the path of least resistance, and if this path is not along the duct, the sialocele will persist. If the underlying pathology, which led to sialocele formation, has been addressed (i.e. removal of

obstructing stone, repair of damaged or stenotic duct), simple aspiration of the sialocele (Fig. 9.13) with or without pressure dressing should result in resolution [14]. In cases, of recurrent sialocele, the practitioner should confirm ductal patency (saliva excretion from the duct ostium with gland massage) and then consider Botox therapy of the gland. While an effective therapy, the onset of action takes approximately 7 days. In cases of severe ductal trauma, open repair or even parotidectomy may be necessary (Fig. 9.14).

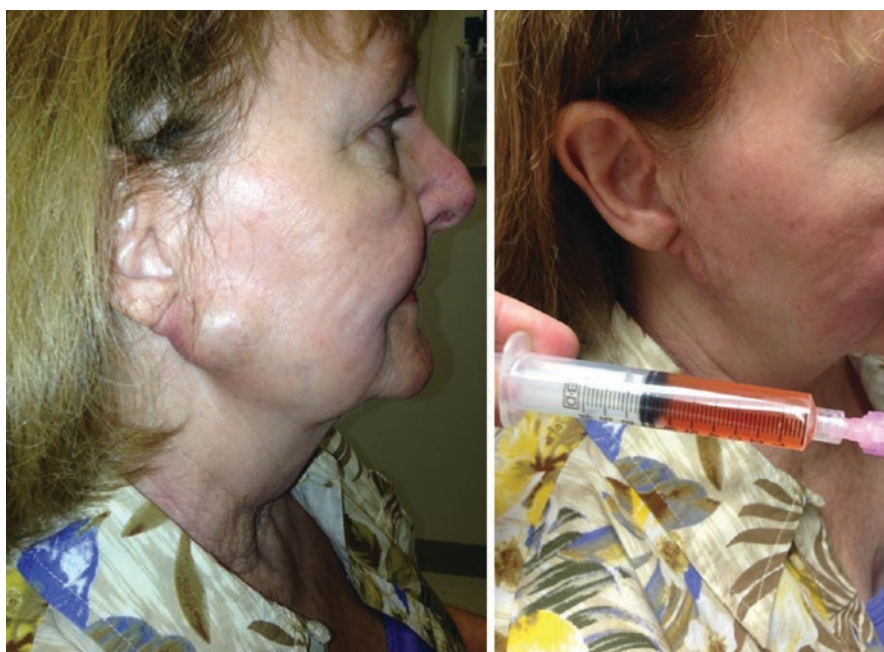

Fig. 9.13 Sialocele of the right parotid gland (*left image*), with resolution of swelling following aspiration of sialocele (*right*)

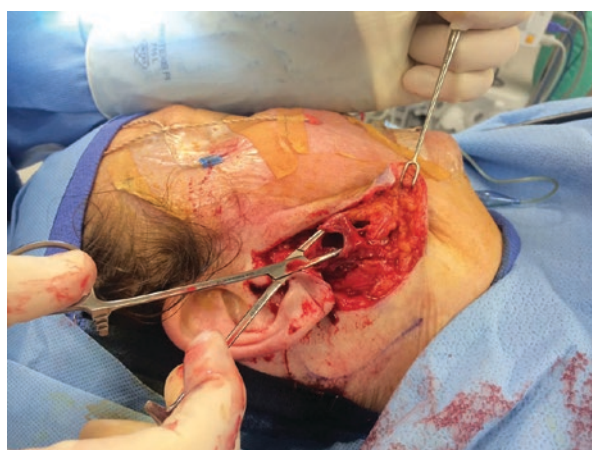

Fig. 9.14 Large recurrent sialocele necessitating operative exploration and parotidectomy

Conclusion

Salivary duct surgery has advanced significantly in the last few decades. The advancements in techniques and technology will continue to increase in parallel. However, the tenants of good surgical practice should be maintained. Much can and should be learned by the evolution of endoscopic sinus surgery, which revolutionized the field of sinus surgery, but also opened the door for drastic complications, which dramatically increased once it became a mainstream surgical technique. As the popularity of sialendoscopy increases and more practitioners adopt the technique, quality control is imperative to minimize the potential complications and protect patients. In the management of major duct trauma, meticulous repair technique with fine-gauge suture under magnification is vital. Endoscopy may provide immediate and delayed confirmation of duct repair and continuity.

References

1. Horsburgh A, Massouda TF. The salivary ducts of Wharton and Stenson: analysis of normal variant sialographic morphometry and a historical review. *Ann Anat.* 2013;195(3):238–42.
2. Chang JL, Eisele DW. Limited distal sialodochotomy to facilitate sialendoscopy of the submandibular duct. *Laryngoscope.* 2013;5:1163–7.
3. Nahlieli O. Complications of sialendoscopy: personal experience, literature analysis, and suggestions. *J Oral Maxillofac Surg.* 2015;73(1):75–80.
4. Gordin EA, Daniero JJ, Krein H, Boon MS. Parotid gland trauma. *Facial Plast Surg.* 2010;26(6):504–10.
5. Walvekar RR, Razfar A, Carrau RL, Schaitkin B. Sialendoscopy and associated complications: a preliminary experience. *Laryngoscope.* 2008;118(5):776–9.
6. Singh B, Shaha A. Traumatic submandibular salivary gland fistula. *J Oral Maxillofac Surg.* 1995;53(3):338–9.
7. Arnaud S, Batifol D, Goudot P, Yachouh J. Non-surgical management of parotid gland and duct injuries: interest of botulinum toxin. *Ann Chir Plast Esthet.* 2008;53(1):36–40.
8. Haller JR. Trauma to the salivary glands. *Otolaryngol Clin N Am.* 1999;32(5):907–18.
9. Epker BN, Burnette JC. Trauma to the parotid gland and duct: primary treatment and management of complications. *J Oral Surg.* 1970;28(9):657–70.
10. Steinberg MJ, Herrera AF. Management of parotid duct injuries. *Oral Surg Oral Med Oral Pathol Oral Radiol Endod.* 2005;99(2):136–41.
11. Nahlieli O, Baruchin AM. Sialoendoscopy: three years' experience as a diagnostic and treatment modality. *J Oral Maxillofac Surg.* 1997;55(9):912–8. discussion 919–920.
12. Van Sickels JE. Management of parotid gland and duct injuries. *Oral Maxillofac Surg Clin North Am.* 2009;21(2):243–6.
13. Awana M, Arora SS, Arora S, Hansraj V. Reconstruction of a traumatically transected Stensen's duct using facial vein graft. *Ann Maxillofac Surg.* 2015;5(1):96–9.
14. Landau R, Stewart M. Conservative management of post-traumatic parotid fistulae and sialoceles: a prospective study. *Br J Surg.* 1985;72(1):42–4.

Part III

Management of Non-obstructive Salivary Disorders

Oscar Trujillo and Rahmatullah W. Rahmati

Key Points

1. Sialadenitis can be acute or chronic in nature in the setting of salivary flow obstruction, bacterial/atypical bacterial or viral infections, and autoimmune or granulomatous diseases.
2. Many imaging modalities have been described to aid in diagnosis of sialadenitis including ultrasound (US), computed tomography (CT), sialography, and more recently magnetic resonance (MR) sialography with sialography considered the gold standard.
3. Since the advent of sialendoscopy, the surgical treatment of salivary stones has shifted from gland removal to gland preservation especially for stones <4 mm that are generally amenable to endoscopic removal.
4. Our chapter hopes to provide a management algorithm to help the clinician diagnose and treat a variety of diseases that cause acute or chronic/recurrent sialadenitis.

Introduction

Sialadenitis, acute, chronic, and recurrent, can occur in the setting of three major categories: obstructive diseases, viral and bacterial diseases, and autoimmune/granulomatous diseases. Acute sialadenitis is the most common condition involving the major salivary glands and is commonly due to a viral or bacterial infectious etiology, while chronic and recurrent sialadenitis typically occurs in the setting of an obstructive process. In this chapter, we will address each category but focus on salivary gland obstruction, mainly due to sialolithiasis and its general management, including with sialendoscopy.

Acute Sialadenitis

Many patients with salivary stones are asymptomatic, but when salivary stones become large enough to block salivary flow, acute onset symptoms can occur. These include facial and/or neck pain and swelling, purulent discharge, possibly systemic symptoms (e.g., fevers, chills, etc.), and tenderness associated with mealtimes, when salivary secretions tend to increase. The diagnosis of acute suppurative sialadenitis has been historically applied to patients meeting certain criteria, including (1) presence of a pathogen on a culture or gram stain of salivary drainage; (2) clinical manifestations of gland infection, such as swelling, tenderness, etc.;

O. Trujillo, M.D. • R.W. Rahmati, M.D., M.P.H. (✉)
Department of Otolaryngology—Head and Neck
Surgery, Columbia University Medical Center,
New York, NY 10032, USA
e-mail: rr2583@cumc.columbia.edu

(3) presence of extra-glandular complications, such as abscess formation, nerve palsy, extreme pain, etc.; and (4) presence of one or more additional risk factors for sialadenitis, such as xerostomia, poor oral hygiene, etc [1]. Physical exam with bimanual palpation may reveal expressible purulence, gland induration, fluctuance at the floor of the mouth, trismus, and, if located in the anterior two third of Wharton's duct, palpable stones [2, 3]. During acute sialadenitis, *Staphylococcus aureus* is most often isolated (50–90%), and *Haemophilus influenzae* and other streptococcal species have been less often isolated [3, 4].

Viral Causes

Mumps can cause salivary gland swelling and inflammation, typically occurs in patients aged 5–15 years (85% of cases occur <15 years of age), and is caused by a virus in the myxo family [4, 5]. Although mumps more frequently involves the parotid gland, it can also affect both submandibular and sublingual glands. Patients present with painful, often bilateral swelling, and systemic symptoms such as fevers, chills, nausea, loss of appetite, or headaches. Lack of purulence upon gland palpation and bilateral gland involvement helps differentiate mumps from acute bacterial infection. Mumps is also diagnosed with positive serology titers in the setting of leukocytosis.

Obstructive Diseases

Salivary calculi frequently present to the otolaryngologist, affecting approximately 1.2% of the population. The majority occur in the submandibular gland (80–90%) and some in the parotid (5–10%) [6]. Salivary stone formation can lead to mechanical obstruction, persistent mealtime swelling, and bacterial infections [2]. Salivary stones occur more commonly in males, generally presenting with glands on both sides equally affected, unusual bilateral involvement, and, more rarely, in the minor salivary glands [2]. All ages may experience salivary stone formation, but there is much higher incidence among

patients between the fourth and sixth decade of life, during which presentation of a single salivary stone occurs approximately 70–80% of the time [2]. A higher proportion of salivary stones are found in the submandibular gland relative to the parotid gland, which may be attributed to the former's longer and larger caliber duct, through which saliva flows against gravity at a slower rate, is more alkaline, and has higher relative mucin and calcium content [2].

Salivary stone formation is not completely understood, but it is likely that microscopic stones accumulate during normal salivary activity and produce atrophic foci that serve as proliferation sites for microbes ascending the main salivary duct, leading to inflammation, swelling, and fibrosis [7]. These conditions can cause compression of the large salivary ducts, where calcium-rich material can stagnate and deposit around desquamated epithelial cells, foreign bodies, products of bacterial decomposition, microorganisms, and/or mucus plugs [8].

Salivary stones are generally comprised of calcium phosphate with small amounts of magnesium, ammonium, potassium, and carbonate and grow at rate of 1–1.5 mm a year, ranging from 0.1 to 30 mm [9, 10]. The average daily flow of saliva is approximately 1–1.5 L/day. The submandibular gland provides most of the saliva at rest, and the parotid gland contributes as much as 50% of saliva during stimulation [3]. Factors associated with increased inflammation and a decreased rate of salivary flow may also be associated with increased risk of stone formation. These include smoking, low fluid intake, and medication that may decrease salivary output (e.g., anticholinergics) [6, 11]. Other risk factors that may predispose patients to acute sialadenitis include certain medical conditions, including Sjogren's disease, diabetes mellitus, hypothyroidism, and renal failure [4].

Obstructive diseases can be further categorized into sialolithiasis, mucus plugs, ductal strictures or stenosis, foreign bodies, and extra-ductal causes [5]. As noted, patients with salivary stones may be asymptomatic until the flow of saliva is blocked or infection occurs. Once salivary flow is obstructed, particularly postprandial, the gland swells, causing fullness and pain. The degree of

obstruction dictates the rapidity and severity of symptoms [5]. Persistent obstruction of the duct creates a nidus for bacterial infection, transforming sialolithiasis to acute sialadenitis. Similarly, mucus plugs can obstruct salivary flow, but typically to a less severe degree than sialolithiasis, because mucus plugs, unlike salivary stones, are not fully mineralized. Sialadenitis secondary to mucus plugs is therefore more rare [5].

Strictures and stenosis can also obstruct salivary flow. These occur in Wharton's and Stenson's ducts following trauma, scarring, calculi, recurrent infections, previous salivary duct procedures, intraductal tumor, or extra-ductal compression [5]. Treatment depends on whether the ductal stenosis or stricture is located at the papilla.

The presence of foreign bodies in the duct, such as grass, toothpicks, hay, and seeds, may also cause obstruction. These are more commonly found in the Wharton's duct than in the Stenson's duct [5]. Finally, extra-ductal causes, including intraoral tumors and enlarged level cervical/buccal lymph nodes, may be revealed by a thorough otolaryngological history and imaging.

Chronic/Recurrent Sialadenitis

Chronic/recurrent sialadenitis presents repeated or continued episodes of pain and inflammation due to decreased salivary flow, most frequently affecting the parotid gland [12]. Obstruction of the salivary gland duct is followed by recurrent inflammation, causing acinar destruction with lymphocytic infiltration and fibrous replacement with sialectasis [12]. Patients typically present with mild tenderness and recurrent or chronic gland swelling aggravated by eating. Approximately 80% of patients with chronic sialadenitis develop xerostomia over time.

Causes of Chronic Sialadenitis

Tuberculosis can involve the salivary glands and the surrounding lymph nodes and is the most common granulomatous infection of the major salivary glands (most commonly the parotid) [5]. Atypical mycobacteria can also cause peri-

glandular lymphadenitis or sialadenitis, typically in young adults and children. Symptoms include acute, non-tender swelling, occasionally with fistula tract formation. Peri-glandular lymphadenitis or sialadenitis must be distinguished from bacterial lymphadenopathy, leukemia, lymphoma, cat-scratch disease, and fungal infections [5].

Sarcoidosis is another granulomatous disease affecting many organs in the body, including the salivary glands. Patients are typically African-American in the age range of 20–40 years [5]. Heerfordt's syndrome affects approximately 8% of sarcoid patients where there is eye, facial nerve, and parotid gland involvement [5]. Heerfordt's syndrome patients present in the second or third decade of life, with fever, illness, uveitis, facial nerve palsy, and parotid gland swelling. It is diagnosed with a biopsy demonstrating non-caseating granulomatous lesions with giant cells [5]. Actinomycosis, specifically *A. israelii*, is part of the normal flora in the oral cavity and can cause retrograde salivary gland infection [5]. Symptoms include mildly tender, non-fluctuant, and indurate salivary glands and can present as acute, subacute, or chronic sialadenitis.

Autoimmune disease such as Sjogren's syndrome, the second most common autoimmune disease after rheumatoid arthritis, can also affect the salivary glands. Its pathogenesis is mediated by lymphocytic destruction of the exocrine glands, leading to xerostomia and keratoconjunctivitis sicca [12]. Approximately 90% of Sjogren's syndrome patients are women. The average age of onset is 50 years old, and it can involve unilateral or bilateral glands [12]. Sjogren's syndrome is further divided into (a) exocrine involvement only and (b) secondary Sjogren's when associated with a definable autoimmune disease, such as rheumatoid arthritis [12].

Juvenile recurrent parotitis is characterized by recurrent episodes of gland inflammation, causing swelling and pain [4]. The exact etiology is unknown, but it presents with either acute or subacute and either unilateral or bilateral gland swelling, typically parotid, with fever and malaise [4]. Such episodes may last for days or weeks and usually occur within a few months [4]. Examples of all acute and chronic diseases discussed so far are summarized in Table 10.1.

Table 10.1 Acute and chronic sialadenitis [9]

	Etiology	Presentation	Physical examination	Diagnosis	Treatment
<i>Acute sialadenitis</i>					
Bacterial	Staph aureus (50–90%), Strep species, H. influenza	Acute onset of pain, swelling, gland erythema and warmth	Purulence with gland message, tenderness on palpation	Purulence from gland, culture may help in diagnosis	Penicillin with beta-lactamase inhibitors (augmentin), warm compresses, gland massage, sialagogues, hydration, oral hygiene; Incisional and drainage if abscess present
Viral	Myxo family (mostly parotid; 85% occurring <15 years old), HIV (mostly parotid)	Acute onset of swelling, possible pain w/erythema in children w/ constitutional symptoms (fevers, chills, malaise, etc.)	Tender, pain on palpation, no purulence from duct w/ message	Viral serology titers	Supportive care, anti-retroviral HIV medications
<i>Chronic/recurrent sialadenitis</i>					
Obstructive	Underlying duct anomalies (stenosis, kinks, etc.), salivary stones	Recurrent episodes of pain and swelling associated with meals, possibly recurrent acute infections	Indurated gland, with no saliva expressed on gland message, may be tender	Imaging demonstrating stone or stricture w/possible duct dilation	Hydration, gland massage, Sialendoscopy +/- endoscopic intervention (stone removal, duct dilation) or open intervention
Bacterial/fungal	Atypical mycobacteria, cat scratch disease, fungal, actinomyces (most commonly A. Israeli)	Slow onset of gland swelling, mildly painful	Indurated gland, may be tender, no purulence from duct	History of slow growing mass and physical exam with mildly tender gland, unlikely purulence from duct	Long term antibiotics directed at atypical mycobacteria, Bartonella, Actinomyces
Systemic	Sjogren's disease, Rheumatoid arthritis, Lymphoma	Chronic gland swelling, non painful	Indurated gland, non tender, no purulence from duct	biopsy of gland, +/- imaging, inflammatory markers in blood work (RA, ANA, Anti-Ro, Anti-La)	Systemic treatment, hydration
Inflammatory/ granulomatous	Recurrent parotitis of childhood, Sacroidosis, Tuberculosis	Recurrent episodes of pain and swelling not associated with meals in children (Recurrent Parotitis), slow onset of painless gland swelling	Tenderness to palpation with recurrent parotitis in children; indurated, non tender to palpation with no purulence from duct	History and physical exam of tenderness of parotid gland in children; biopsy of gland, PPD, ACE levels	Antibiotics, hydration, gland massage, supportive care, possible sialendoscopy for children; System therapy for adults

Imaging

Ultrasound

Standard X-ray films were historically useful in diagnosing ductal stones, but intraglandular and small stones were easily missed, as up to 20% of stones are reported as radiotransparent [13]. It is also difficult to specifically locate stones using this imaging, and it is therefore better used as a screening tool. In studies comparing ultrasound, sialography, and endoscopy, ultrasound has been demonstrated to be 81% sensitive, 94% specific, and 86% accurate [13, 14]. Compared to magnetic resonance (MR) sialography, ultrasound has a demonstrated specificity and sensitivity of 80% [13, 15]. Ultrasound may demonstrate chronic parotid gland inflammation characterized by irregular hypodensities interspersed with hyperechogenic scar and increased vascular flow as seen in Sjogren’s disease, lymphoma, and granulomatous disease (Fig. 10.1).

Computed Tomography (CT) Scan

CT is useful to evaluate salivary stones if the stones are large, or if the cuts are fine and performed every millimeter [13]. However, like ultrasound, CT does not reveal duct anomalies or

precise stone location in the duct. With conventional contrast-enhanced CT, sialodochitis may present as irregularities in the duct wall and ductal wall thickening and increased enhancement [16]. Dilation of the duct frequently accompanies obstruction, as do hyperdense non-enhancing calcified stones in the same range of Hounsfield units as the bone [16]. With chronic sialadenitis, the acinar atrophy may appear on CT as the so-called “shrunkened” gland, with higher fat content [16]. CT scans of acute sialadenitis demonstrate glandular enlargement and enhancement with surrounding inflammatory changes of the subcutaneous fat and/or an associated abscess or underlying etiology such as a stone (Fig. 10.2).

Sialography

Sialography is the gold standard for evaluating salivary ducts, because it reveals the precise location of salivary stones as well as duct anomalies, after intraductal retrograde injection of water-soluble radiopaque dye [13]. Risks associated with sialography are (1) pain, (2) exposure to irradiation, (3) risk of canal wall perforation, (4) proximal displacement of the stone in the duct, and (4) complications, such as infection or anaphylaxis after dye injection [13].

Fig. 10.1 Parotid ultrasound showing characteristic findings of chronic sialadenitis including hypodense fluid collections surrounded by hyperintense scar

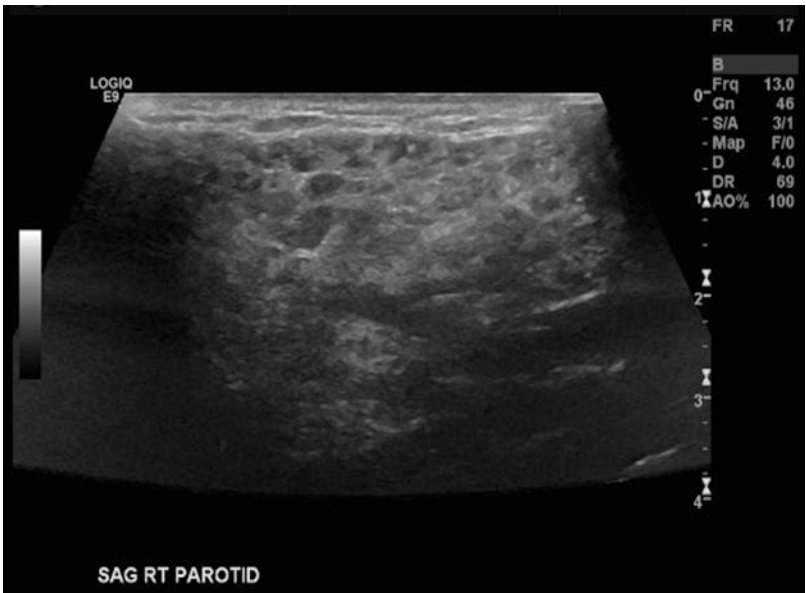


Fig. 10.2 CT scan of right submandibular stone with surrounding hypodensity consistent with early abscess (a) extending into an enlarged, edematous gland (b)

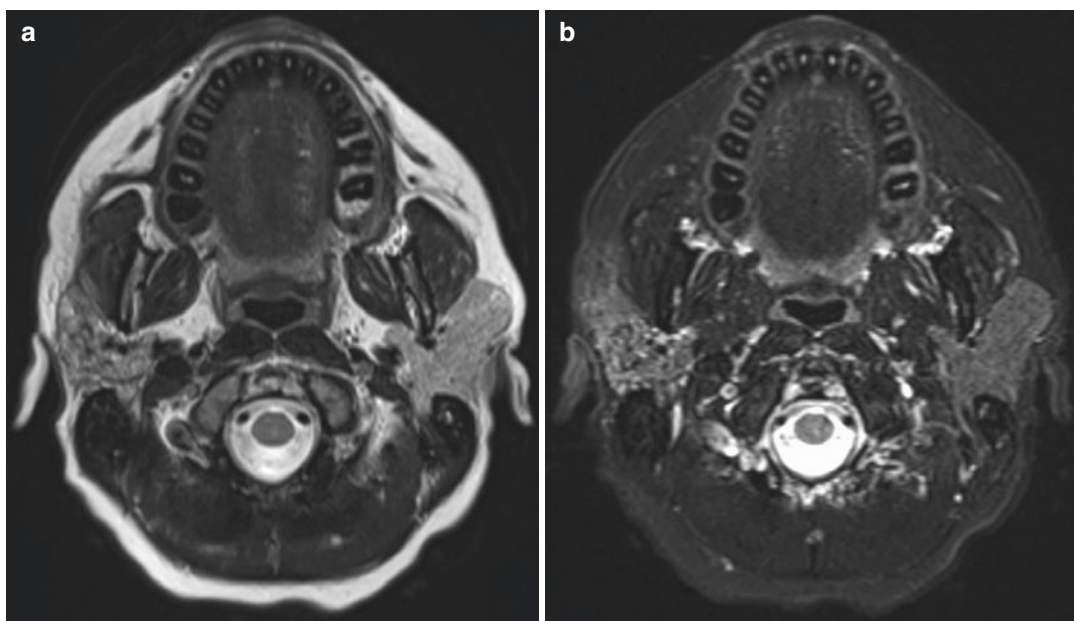
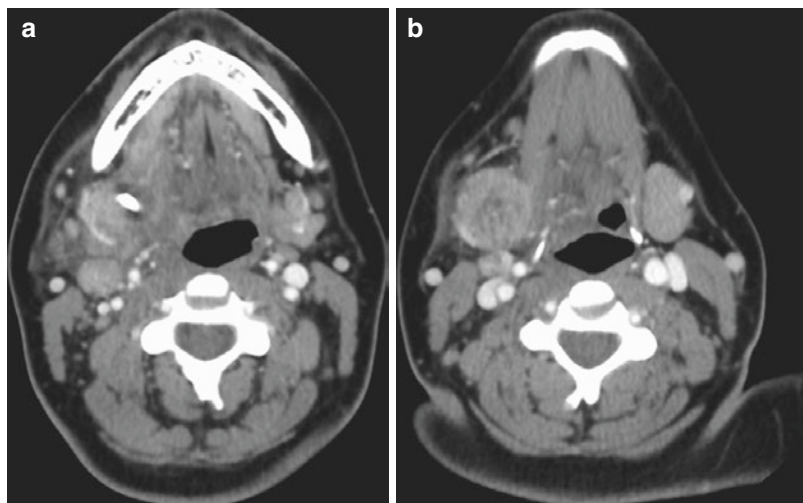


Fig. 10.3 T1- (a) and T2- (b) weighted axial MRI images with heterogeneous changes in a right parotid gland with chronic sialadenitis

MR and MR Sialography

Even though MR provides superior soft tissue contrast than CT, it is more difficult to distinguish duct obstruction due to calcified stones, air, fibrin, or mucus plugs [16]. Additionally, MR may overestimate the size of a calcified stone by approximately 10–30%, which may deter the

selection of sialendoscopic treatment methods [16]. Chronically inflamed parotid glands demonstrate heterogeneous enhancement on MRI (Fig. 10.3). The Marchal and Dulguerov paper in 2003 [13] describes MR sialography using 3 mm T2-weighted sequences in both the sagittal and axial planes. Volumetric reconstruction permitted precise localization of the stones in the duct, with

Table 10.2 Comparison imaging with sialendoscopy in salivary diseases [16]

	Plain X-ray	Ultrasound	CT (contrast enhanced)	Sialography	MR	Sialendoscopy
Radiation exposure	Yes	No	Yes	Conventional sialography-yes; MR sialography-no	No	No
Invasive	No	No	No	Yes	No	Yes
Visualization of duct to surrounding soft tissue structures	No	No	Yes	No	Yes	No
Visualization of duct anomalies	No	No	Limited	Yes	Limited	Yes
Precise location of stone in the duct	No	No	Limited	Yes	Limited	Yes
Availability	Widely available	Widely available	Widely available	Conventional widely available, MR sialography moderately available	Widely available	Moderately available
Cost	Low	Low	Moderate to high	Moderate to high for conventional; high for MR sialography	High	Moderate to high
Risks	Minimal	Minimal	Minimal	Contrast reaction, pain, inadvertant mobilization of stone, duct perforation (conventional); limitation from implants (MR)	Limitation from implants	Duct perforation, failure to remove stone, fistula, pain, facial nerve injury, lingual nerve injury

good visualization of duct anomalies [13]. The advantages of MR sialography over conventional sialography are that it is noninvasive and has no dye, pain, or radiation exposure, and it allows for rapid reconstruction of images after scan [13]. Limitations of MR sialography include cost, unavailability due to the presence of cochlear or other similar implants, and lengthy scan acquisition time of 45 min. All modes of imaging discussed so far and compared with sialendoscopy are summarized in Table 10.2.

Medical Management of Salivary Disease

The provider must first determine whether a patient is presenting with acute or chronic/recurrent sialadenitis. The cause of sialadenitis is most

frequently obstruction by salivary stone(s) (60–70% frequency), followed by stenosis (15–25% frequency), inflammation of the duct (around 5–10% frequency), and, least frequently, other obstructions, duct anomalies, or foreign bodies (around 1–3% frequency) [17].

Treatment for acute suppurative sialadenitis is typically antibiotic therapy targeted for gram-positive and anaerobic organisms, which are generally both penicillin sensitive [4]. As such, Augmentin® is usually the antibiotic of choice and is accompanied by gland massaging, sialogogues, warm compresses, and improved oral hygiene. When available, culture-directed antibiotics are a superior treatment. Treatment of underlying medical problems, such as diabetes, is also indicated, as is possible surgical or needle drainage in the event of abscess formation. With respect to chronic and recurrent

sialadenitis, the underlying cause of duct obstruction can be investigated with imaging, sialendoscopy, gland biopsy, gland excision, or open surgery.

Viral sialadenitis is treated with supportive care. Suspected granulomatous diseases may be diagnosed by performing a biopsy and drawing rheumatoid serologies [4].

Surgical Management of Salivary Disease

Under direct visualization, sialendoscopy provides the most accurate information concerning stone location and ductal pathology. Typically, sialendoscopy is appropriate for patients with chronic or recurrent sialadenitis or gland swelling of uncertain origin [13]. The Marchal and Dulguerov study looked at 450 diagnostic sialendoscopy cases and described successful stone localization in 98% of such cases [13]. The Zenk et al. study described failed stone localization in 7% of submandibular gland cases and in 21% of parotid cases out of 1154 sialendoscopy cases [18]. Risks associated with sialendoscopy are overall minor, such as failure to retrieve the stone or stone fragments, damage or perforation to the duct, possible swelling at the floor of mouth, or need to remove gland [19]. Patients with stones measuring <3 mm in the parotid duct, or <4 mm in the submandibular duct, are generally amenable to interventional sialendoscopy with wire basket extraction alone [13, 19]. Larger palpable or intraglandular stones likely require a transoral open excisional approach, with or without

the guidance of sialendoscopy. Stone removal by transoral ductal incision may be the first-line treatment for impacted stones or stones >5 mm [17]. Another treatment option is by intracorporeal laser through the working channel of the sialendoscope, in order to divide a large stone and create smaller, more mobile fragments [19]. Stones ranging from 5 to 7 mm usually require a concomitant sialolithotomy and/or may be amenable to laser fragmentation [19].

Stones that are not accessible with sialendoscopy may be amenable to treatment with extracorporeal shock-wave lithotripsy (ESWL), which uses ultrasound technology to break up a stone into fragments that can then be removed with wire basket [19]. This technique is less successful where the stone(s) is larger than 10 mm in size [19].

Stone removal may be complicated when encountering kinks in the ducts, or severe serpentine bends that do not permit endoscopic entry and typically obstruct salivary flow and can lead to chronic sialadenitis [18]. Stenosis of the duct may be treated with papillotomy or balloon dilation, depending on the location, severity, and segmental length [18]. An algorithm of how to initially treat acute and chronic sialadenitis is presented in Fig. 10.4.

Sialendoscopy has progressed over the past 10–15 years, but 5% of patients still ultimately require gland removal. Gland removal is generally necessary for patients with: (a) intraparenchymal stones not transorally accessible, (b) multiple intraparenchymal stones, (c) three failed ESWL attempts, or (d) megasialoliths >1 cm that cannot be transorally removed [19].

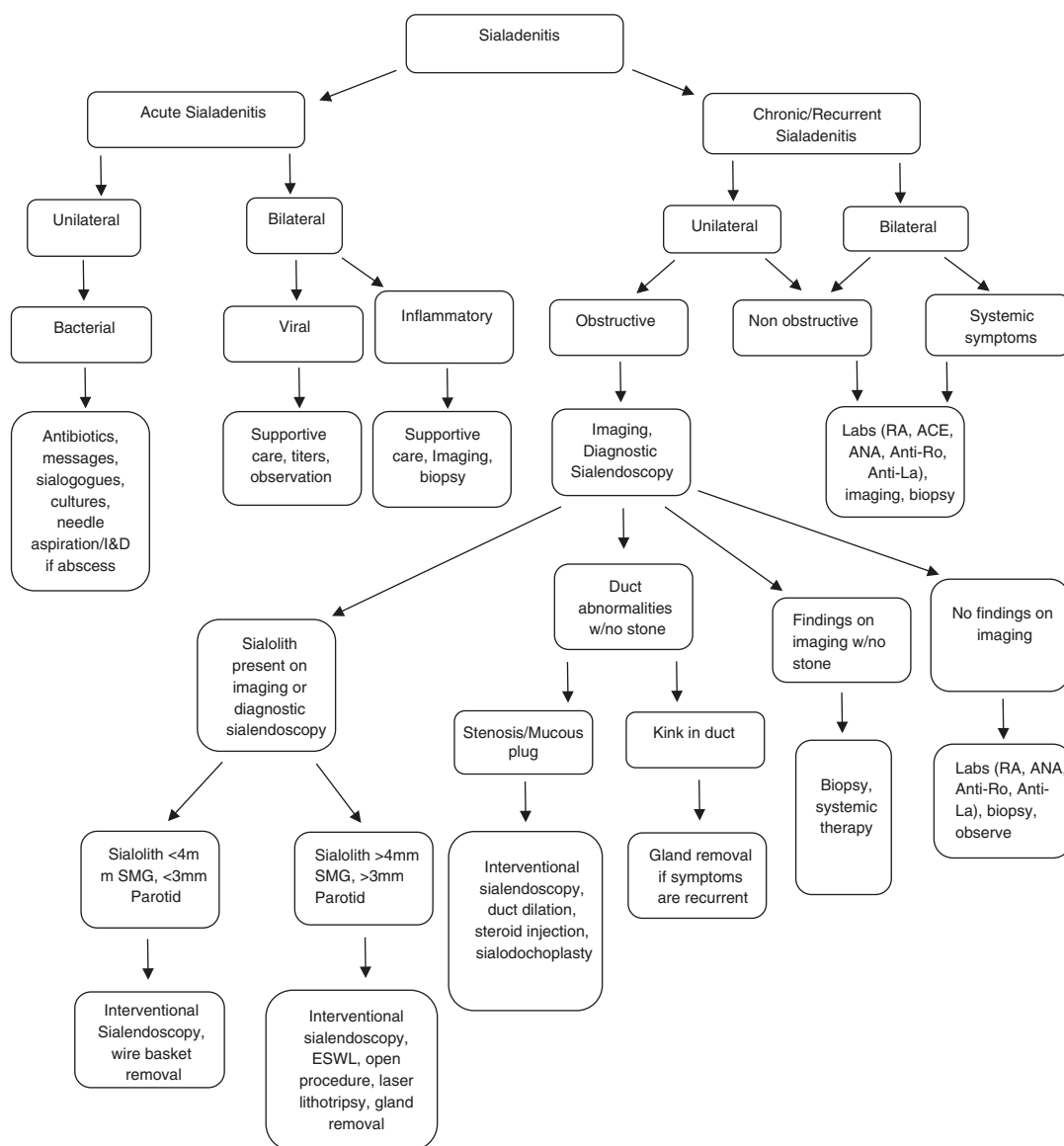


Fig. 10.4 Treatment algorithm for the management of acute and chronic sialadenitis

References

1. Raada II, Sabbagh MF, Caranasos GJ. Acute bacterial sialadenitis: a study of 29 cases and review. *Rev Infect Dis.* 1990;12(4):591–601.
2. Lustmann J, Regev E, Melamed Y. Sialolithiasis. A survey on 245 patients and a review of the literature. *Int J Oral Maxillofac Surg.* 1990;19(3):135–8.
3. Hernandez S, Busso C, Walvekar RR. Parotitis and sialendoscopy of the parotid gland. *Otolaryngol Clin North Am.* 2016;49(2):381–93.
4. Wilson KF, Meier JD, Ward PD. Salivary gland disorders. *Am Fam Physician.* 2014;89(11):882–8.
5. Epker BN. Obstructive and inflammatory diseases of the major salivary glands. *Oral Surg Oral Med Oral Pathol.* 1972;33(1):2–27.
6. Huoh KC, Eisele DW. Etiologic factors in sialolithiasis. *Otolaryngol Head Neck Surg.* 2011;145(6):935–9.
7. Harrison JD. Causes, natural history, and incidence of salivary stones and obstructions. *Otolaryngol Clin North Am.* 2009;42(6):927–47.
8. Zheng L, Kim YA, Yu EB, Yang CA, Park JC, Chen ZZ. A retrospective case series illustrating a pos-

- sible association between a widened hilum and sialolith formation in the submandibular gland. *J Craniomaxillofac Surg.* 2013;41(7):648–51.
9. Austin T, Davis J, Chan T. Sialolithiasis of submandibular gland. *J Emerg Med.* 2004;26(2):221–3.
 10. Makdissi J, Escudier MP, Brown JE, Osailan S, Drage N, McGurk M. Glandular function after intraoral removal of salivary calculi from the hilum of the submandibular gland. *Br J Oral Maxillofac Surg.* 2004;42:538–41.
 11. Williams MF. Sialolithiasis. *Otolaryngol Clin North Am.* 1999;32(5):819–34.
 12. Rice DH. Chronic inflammatory disorders of the salivary glands. *Otolaryngol Clin North Am.* 1999;32(5):813–8.
 13. Marchal F, Dulguerov P. Sialolithiasis management: the state of the art. *Arch Otolaryngol Head Neck Surg.* 2003;129:951–6.
 14. Marchal F, Becker M, Dulguerov P, Lehmann W. Prospective evaluation of the accuracy of ultrasound in the detection of sialography. *Eur Radiol.* 2000;217(2):347–58.
 15. Jäger L, Manauer F, Holzknecht N, Scholz V, Grevers G, Reiser M. Sialolithiasis: MR sialography of the submandibular duct—an alternative to conventional sialography and US? *Radiology.* 1993;216:665–71.
 16. Mosier K. Diagnostic radiographic imaging for salivary endoscopy. *Otolaryngol Clin North Am.* 2009;42:949–72.
 17. Koch M, Zenk J, Heinrich I. Algorithms for treatment of salivary gland obstructions. *Otolaryngol Clin North Am.* 2009;42:1173–92.
 18. Zenk J, Koch M, Klintworth N, et al. Sialendoscopy in the diagnosis and treatment of sialolithiasis: a study on more than 1000 patients. *Otolaryngol Head Neck Surg.* 2012;147:858–63.
 19. Rahmati R, Gillespie MB, Eisele DW. Is sialendoscopy and effective treatment for obstructive salivary gland disease? *Laryngoscope.* 2013;123:1828–9.

Inflammatory Conditions of the Salivary Glands: Sjögren's Disease, IgG4-Related Disease, and Sarcoidosis

M. Allison Ogden

Key Points

- Systemic inflammatory conditions may affect the salivary glands.
- Sjögren's syndrome is an autoimmune disease characterized by sicca syndrome and lymphocytic infiltration of salivary and lacrimal glands.
- IgG4-related disease is a recently defined entity resulting in salivary gland swelling and dysfunction.
- Sarcoidosis is a granulomatous disease chiefly presenting with cough and dyspnea and may progress to involve the salivary glands.

Introduction

The clinical presentation of inflammatory diseases of the salivary glands is often nonspecific, and clinical suspicion is required for diagnosis, especially when present in isolation. Symptoms can include dry mouth, salivary gland swelling, and pain localizing to the salivary gland. Management of systemic inflammatory conditions is primarily medical, under the direction of medical specialists (rheumatology, pulmonary, etc.);

however, surgery may play a role in both diagnosis and management of these conditions or their complications. Although the role of surgery in treatment is often supportive, salivary surgeons are often the first to see the patients and must be aware that these conditions exist in order to achieve a timely diagnosis.

Inflammatory Salivary Conditions

Sjögren's Syndrome

Sjögren's syndrome is a systemic autoimmune disease affecting exocrine glands, primarily the salivary and lacrimal glands, resulting in sicca symptoms (dry eyes and dry mouth) and fatigue. Extraglandular manifestations, including arthralgias, are common. Secondary Sjögren's syndrome occurs in setting of other autoimmune diseases, most often rheumatoid arthritis, whereas primary Sjögren's syndrome is in its absence. Sjögren's syndrome is the second most common autoimmune disease, behind rheumatoid arthritis. The prevalence is estimated to be 0.6–6/1000, with a female-to-male ratio of about 10:1 [1, 2].

Patients primarily are bothered by the xerostomia and xerophthalmia and the associated dysphagia, difficulties with articulation and mastication, and sleep disturbance. They are at increased risk for oral candidiasis and dental caries. Salivary gland swelling can occur, more

M. Allison Ogden, M.D.
Department of Otolaryngology—Head and Neck
Surgery, Washington University School of Medicine,
660 S. Euclid Ave, Box 8115,
St. Louis, MO 63110, USA
e-mail: ogdenm@wustl.edu

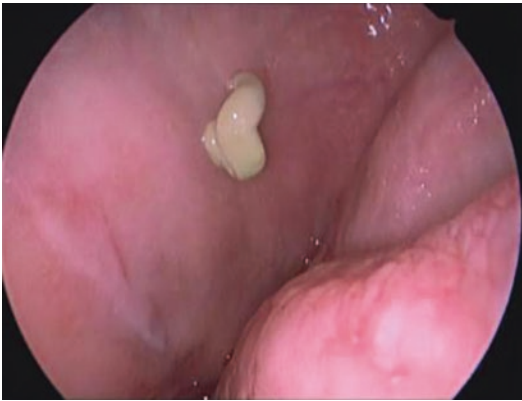

Fig. 11.1 Purulent, thick mucoid discharge from the right parotid ostium in a patient with advanced Sjögren’s syndrome (Image courtesy of M. Boyd Gillespie, MD)

often in the parotid gland, and may be fluctuating or stable, painful, or with minimal symptoms (Fig. 11.1).

Pathophysiology: Sjögren’s syndrome is characterized by lymphocytic infiltration of the salivary glands. A trigger, possibly viral, results in overactive immune response in a likely genetically sensitive individual causing the development of ectopic lymphoid tissue, which further exacerbates the chronic autoimmune response within the exocrine glands and systemically [3]. Salivary glandular cells and ductal cells are affected.

Diagnosis: The diagnosis of Sjögren’s syndrome is based on the American-European Consensus Group classification criteria from 2002 [4]: the presence of (1) ocular and (2) oral symptoms, as well as objective measures for (3) ocular and (4) oral symptoms, the presence of (5) autoantibodies (anti-SSA (Ro), anti-SSB (La)), and (6) labial salivary gland biopsy detailing focal lymphocytic sialadenitis (focus score $\geq 1/4\text{ mm}^3$). Four of the six items need to be present, including at least either the autoantibodies or the labial salivary gland biopsy. An updated classification criteria endorsed by the American College of Rheumatology (ACR) in 2012 from the Sjögren’s International Collaborative Clinical Alliance (SICCA) has been proposed [5]. For patients with clinical features of Sjögren’s syndrome, namely, sicca syndrome, fatigue, arthralgias, and/

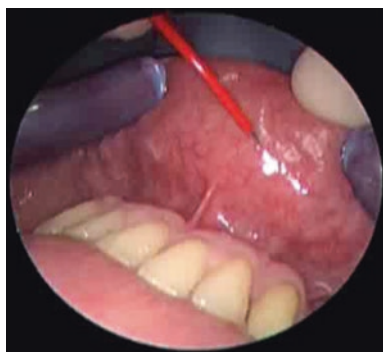Table 11.1 Currently suggested diagnostic criteria for Sjögren’s syndrome [5]

ACR classification criteria for Sjögren’s syndrome
Applied to individuals with s/sx suggestive of Sjögren’s syndrome, in patients with two of the following three objective features
1. Positive serum anti-SSA (Ro) and/or anti-SSB (La) or (positive rheumatoid factor and ANA $\geq 1:320$)
2. Labial salivary gland biopsy showing focal lymphocytic sialadenitis with focus score ≥ 1 focus/ 4 mm^3
3. Keratoconjunctivitis sicca with ocular staining score ≥ 3 (excepting patients on eye drops for glaucoma and corneal or cosmetic eyelid surgery in the last 5 years)

or other symptoms, two of three possible objective criteria need to be met to confirm the diagnosis (Table 11.1). The SICCA/ACR criteria have a sensitivity and specificity for Sjögren’s syndrome of 93 and 95%, respectively [5], while the AECG criteria have sensitivity and specificity of 93% and 94%, respectively [6]. With the reliance on objective criteria, specifically focal lymphocytic sialadenitis and autoantibodies, both criteria have the potential to miss early- or late-stage disease and may have more applicability to clinical trials over clinical practice [6].

In general, laboratory testing should include anti-SSA (Ro), anti-SSB (La), rheumatoid factor (RF), antinuclear antibody (ANA), as well as evaluation for alternate disease entities, such as IgG4-related disease, based on the clinical features. A labial minor salivary gland biopsy may also be performed (Fig. 11.2). Ultrasound can be useful in evaluation of salivary gland abnormalities in Sjögren’s syndrome patients; however, currently there is not a standardized scoring system, and ultrasound is not a part of the diagnostic criteria. Ultrasound findings can show hypoechoic areas and punctate calcifications, corresponding to sialectasia and ductal strictures, primarily in later stage disease (Fig. 11.3). The role of ultrasound in early identification needs further clarification [7].

Medical management: The medical treatments of Sjögren’s syndrome can be divided into managing the symptoms and addressing systemic and extraglandular disease. Tear substitute and



MINOR SALIVARY GLAND BIOPSY

Fig. 11.2 Minor salivary biopsy is the most sensitive method for confirming the diagnosis of Sjögren's syndrome. A total of 4 mm³ of minor salivary gland tissue should be harvested from a 1 cm incision on the mucosal surface of the lower lip and sent to pathology to report the focus score (*Image courtesy of M. Boyd Gillespie, MD*)

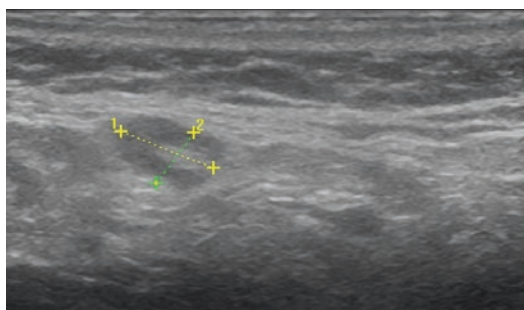


Fig. 11.3 Ultrasound examination of parotid gland in a patient with Sjögren's syndrome often reveals a shrunken gland with hyperechoic scar and scattered lymph nodes (marked) (*Image courtesy of M. Boyd Gillespie, MD*)

ocular lubricants can be helpful. Ophthalmologists may recommend lacrimal punctum plugs, topical cyclosporine, or corticosteroids to reduce risks associated with xerophthalmia. Similarly, artificial saliva, oral moisturizers, and sugar-free chewing gum can be utilized for xerostomia. Where residual salivary function exists, pilocarpine or cevimeline, muscarinic agonists, may temporarily induce salivation, although its use may be limited by side effects such as nausea, sweating, and palpitations. While the evidence is generally limited, immunosuppressants, such as hydroxychloroquine and corticosteroids, are considered by rheumatologists to address the sicca and systemic symptoms. Rituximab may

be considered for severe, extraglandular disease in patients who are not responsive to more standard therapies [1].

Long-term outcome: Patients with Sjögren's syndrome are at risk for development of non-Hodgkin lymphoma, usually presenting as mucosa-associated lymphoid tissue lymphoma. The overall relative risk is 10–15 compared to the general population, with overall increased risk with longer disease duration. Lymphoma usually arises in the parotid or submandibular gland, although it can develop elsewhere. MRI or US may be able to distinguish salivary gland hypertrophy from lymphoma (Fig. 11.4). Lymphoma should be suspected in patients with a known history of Sjögren's syndrome who present with sudden or progressive enlargement of a major salivary gland. Biopsy is indicated when clinical suspicion is present. The MALT lymphoma in Sjögren's syndrome patients is associated with good prognosis [2].

IgG4-Related Disease

IgG4-related disease is a multisystem inflammatory disorder with a variable clinical presentation. Historically, this disease has been recognized as several different entities, including Mikulicz disease, Küttner tumor, Riedel thyroiditis, and autoimmune pancreatitis, and is now recognized as IgG4-related disease [8]. IgG4-related disease is known to affect all organ systems, including multiple sites in the head and neck [9]. The salivary glands are a commonly affected organ, estimated to be involved in 40–50% of systemic disease [9]. The submandibular glands are most often affected, followed by the parotid gland; the sublingual gland has rarely been implicated. In the head and neck, disease occurs equally in males and females, whereas there is a strong male predominance elsewhere in the body [10]. Patients present with painless, firm swelling of the involved salivary gland(s), fluctuating or stable. Sicca symptoms are often present, though not to the same degree as in Sjögren's syndrome.

Pathophysiology: While the inciting events and predisposing factors underlying development

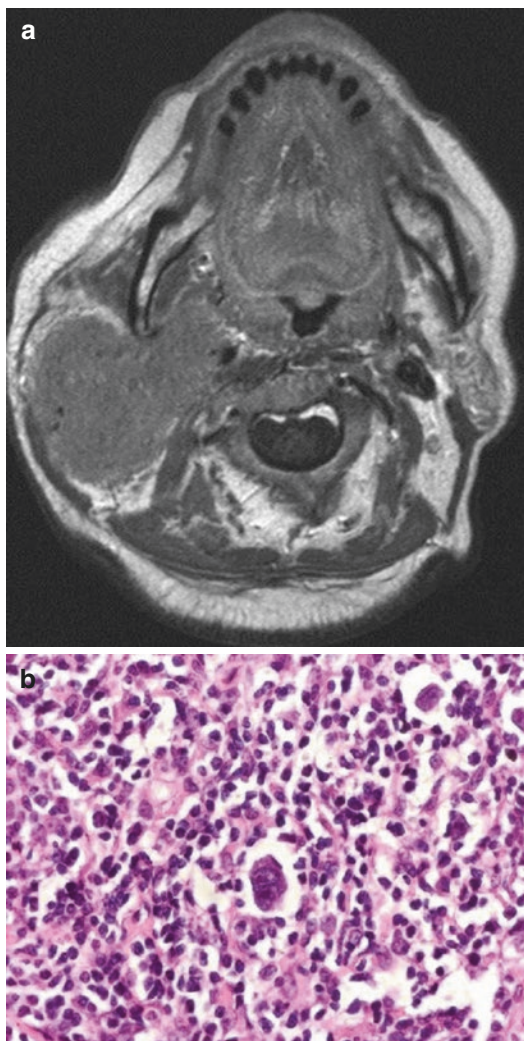


Fig. 11.4 T1-weighted MRI of a patient with Sjögren's syndrome who experienced rapid growth of the right parotid (a). Subsequent biopsy confirmed a mass of monoclonal lymphocytes consistent with lymphoma (b) (Image courtesy of M. Boyd Gillespie, MD)

of IgG4-related disease are not known, the resulting immune dysregulation leads to increased plasma cells and production of IgG4, as well as inflammatory monocytes [11]. Tissue infiltration by inflammatory cells, including plasma cells, leads to enlargement, fibrosis, and ultimate gland dysfunction [12]. The role of IgG4 is not clear. While many patients have elevated serum levels of IgG4, up to 30–40% have normal levels.

Diagnosis: IgG4-related salivary disease should be considered based on clinical presentation, after

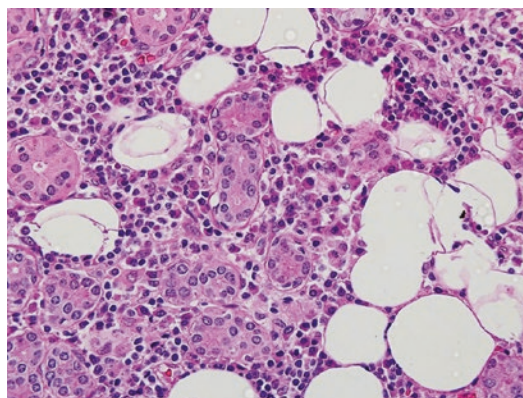


Fig. 11.5 Histopathology from a patient presenting with an enlarged firm mass in the submandibular gland showing lymphocytic infiltration of salivary tissue. Special stains confirmed the lymphocytes to be IgG4 (Image courtesy of M. Boyd Gillespie, MD)

exclusion of other potential etiologies, primarily neoplasm. Elevated serum levels of IgG4 and IgE, hypergammaglobulinemia, and eosinophilia support the diagnosis. If the serum IgG4 is twice or more above the cutoff value, the specificity is high [11]. Normal serum IgG4 does not exclude the diagnosis of IgG4-related disease. The diagnosis is confirmed by biopsy of the affected gland detailing lymphoplasmacytic infiltrates, fibrosis, and obliterative phlebitis, as well as immunostaining positive for IgG4 [11, 12] (Fig. 11.5).

Compared to Sjögren's syndrome, patients with IgG4-related disease do not have elevated levels of SSA/SSB, RF, or ANA. The xerostomia is not generally as severe and improves rapidly with corticosteroid therapy, which is thought to be due to the relative lack of injury to the salivary ducts in IgG4-related disease.

Medical management: Corticosteroids are the first-line treatment of IgG4-related disease, and most patients respond within 2–4 weeks [11]. In fact, if a patient does not respond to corticosteroid therapy, the diagnosis should be reevaluated. Treatment regimens starting with prednisone 40 mg/day for 2–4 weeks, followed by gradual taper, have been proposed; however, higher initial doses may be required based on clinical severity. Corticosteroid therapy is typically continued for weeks to months, sometimes years,

based on disease severity and/or relapse. Steroid-sparing immunomodulators, such as rituximab, have also been used and are being further studied. For minimally symptomatic patients and/or with little disease, observation can be undertaken with monitoring for signs of worsening organ dysfunction. Reports of extranodal marginal zone B-cell lymphoma occurring in salivary glands of patients affected by IgG4-related disease warrant long-term follow-up.

Sarcoidosis

Sarcoidosis is a systemic granulomatous disease with a variable clinical presentation and course, most commonly manifesting with pulmonary signs and symptoms. Sarcoidosis has a higher incidence in African-Americans and women [13]. Head and neck disease may occur in 10–15% of patients, most commonly presenting as cervical adenopathy. The salivary glands are affected in 3% of patients [14]. Salivary gland signs and symptoms are nonspecific, including painless swelling of the involved gland(s), symmetric parotitis, and dry mouth [15]. Heerfordt's syndrome, or uveoparotid fever (parotitis, uveitis, fever, +/- facial nerve palsy), is rare and is considered a manifestation of neurosarcoidosis (Fig. 11.6).

Diagnosis: Sarcoidosis is a diagnosis of exclusion and delay of diagnosis is not uncommon [15]. If the clinical signs and symptoms, supported by radiographic findings, are consistent with sarcoidosis, then biopsy detailing non-caseating granulomas can further support the diagnosis. Biopsy is most often of mediastinal lymph nodes; however, in the head and neck, biopsy of cervical lymph nodes, skin lesions, or salivary glands can be undertaken, based on clinical presentation. Heerfordt's syndrome does not require biopsy for diagnosis. Biomarkers, such as serum angiotensin-converting enzyme (ACE), which can be elevated in 40–80% of patients, can further support diagnosis, however are not specific to sarcoidosis. Currently no biomarker is reliable enough for sarcoidosis diagnosis, exclusion, or disease monitoring [16].

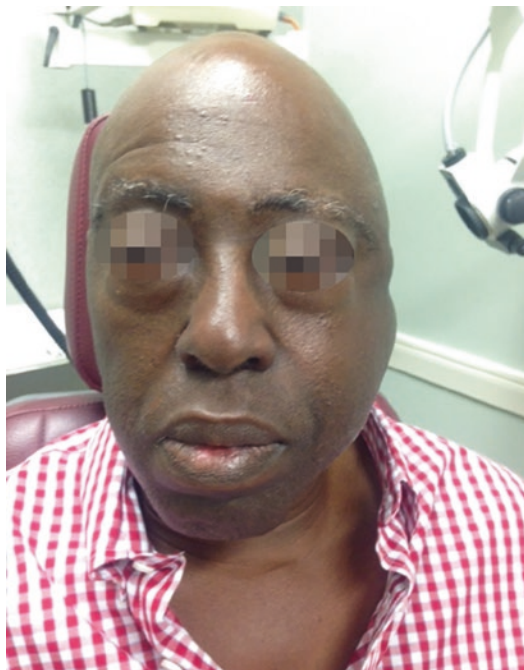

Fig. 11.6 Patient with a history of sarcoid who presented with fever, left parotid swelling, and facial weakness consistent with Heerfordt's syndrome (Image courtesy of M. Boyd Gillespie, MD)

Medical management: Not all patients with sarcoidosis require treatment and spontaneous resolution can occur [17]. In patients with high burden of disease, treatment with corticosteroid is considered the first-line therapy. Steroid-sparing agents such as cytotoxic medications, tumor necrosis factor antagonists, and antimalarials are also utilized as single or multidrug therapy [13, 17].

Surgical Management

Diagnostic Biopsy

Labial minor salivary gland biopsy: The labial minor salivary gland biopsy can be beneficial in the diagnostic evaluation for Sjögren's syndrome and possibly for IgG4-related disease. The biopsy can be performed in the office under local anesthesia or in the operating room, based on the patient and surgeon preference. A horizontal superficial incision is made in the midline lower

labial mucosa, 5–10 mm in length. Three to five minor salivary glands for a total volume of at least 4 mm³ are dissected sharply from the surrounding soft tissue and excised. Magnification with operating loupes is beneficial, though not necessary. After hemostasis with pressure or bipolar cauterization, the incision is closed with interrupted, dissolvable suture.

Incisional or excisional biopsy: In cases of diagnostic uncertainty or when there is a concern for lymphoma, an incisional biopsy of the parotid gland or excisional biopsy of the submandibular gland (sialadenectomy) may be warranted. Prior to incisional parotid biopsy, a primary salivary neoplasm should be excluded by imaging and/or fine-needle aspiration cytology. The risks associated with the incisional parotid biopsy include facial nerve palsy and sialoceles, though both events would be unlikely. The incision should be congruent with a parotidectomy incision and can often be kept to less than 2 cm in length. After raising a skin flap, the parotid fascia is incised, and a small amount of parotid tissue is excised sharply. After hemostasis, fibrin sealant may be applied for further hemostasis and to potentially reduce risk of sialocoele.

Sialendoscopy

There is no evidence looking specifically at IgG4-related disease nor sarcoidosis and sialendoscopy, and the data is relatively limited regarding Sjögren's syndrome. While the underlying disease is not the same as systemic inflammatory diseases, in the setting of idiopathic chronic sialadenitis, sialendoscopy can provide benefit in diagnosis (stenosis, stricture, unidentified sialolith) and, in some cases, symptom improvement [18–20]. Three small studies addressing Sjögren's syndrome and sialendoscopy demonstrate feasibility and possible improvement in some metrics [21–23].

Given the difficulty in diagnosing IgG4-related disease and Sjögren's syndrome, it is likely that at least some patients with idiopathic chronic sialadenitis have either of these entities as their underlying etiology. In fact, Vashishta

and Gillespie found 10% of their idiopathic sialadenitis cohort to have labial minor salivary gland biopsies with a lymphocytic infiltration focus score supportive of Sjögren's syndrome [18]. A labial minor salivary gland biopsy should be considered in a patient with clinical signs and symptoms suggestive of Sjögren's syndrome at the time of sialendoscopy; similarly, a salivary gland biopsy (labial, parotid, submandibular) should be considered if clinical suspicion for IgG4-related disease is present.

Indications: Sialendoscopy is a reasonable consideration for patients with salivary gland inflammatory diseases who have obstructive salivary gland symptoms, including pain and/or swelling. The risks with the procedure are minimal, and there are few alternative options likely to be beneficial. The patient should be appropriately counseled preoperatively to address the uncertainty of outcome.

Technique and findings: The duct in Sjögren's syndrome is typically stenotic, with intraluminal mucus plugs and/or fibrinous debris. The mucosa appears pale and stiff (Fig. 11.3). A smaller endoscope may be required, due to the duct stenosis. Ancillary techniques and equipment, such as semirigid dilators, balloon dilators, forceps, and wire-loop baskets, may be helpful to clear intraluminal debris and to dilate strictures.

Outcomes: Sialendoscopy offers several areas of potential benefit in addressing inflammatory conditions of the salivary gland. The endoscopy enables dilation of stricture and stenosis under direct visualization, as well as clearance of fibrinous debris and mucus plugs. Intraductal corticosteroid applied at the completion of the procedure may have significant benefit, especially in conditions where systemic corticosteroids are an established treatment. It is reasonable to consider that the degree of symptom improvement may depend upon the stage of disease and presence or absence of residual salivary function. In other words, patients with little to no residual salivary gland function are not likely to have benefit in xerostomia, yet obstructive symptoms of swelling and ache may improve with stricture dilation and intraductal corticosteroid application. Patients may have more potential for benefit early in the

disease course. The challenge lies in identifying patients in whom sialendoscopy may provide significant clinical benefit. In this author's experience, sialendoscopy in the setting of chronic inflammatory disease yields little improvement in xerostomia; however, in the appropriately selected patient, i.e., with symptoms of pain and swelling of the salivary gland, the symptoms may improve. Further study with validated outcome measures is needed to elucidate the areas of benefit in this cohort and the timing of intervention.

References

1. Ramos-Casals M, Tzioufas AG, Stone JH, Siso A, Bosch X. Treatment of primary Sjogren syndrome: a systematic review. *JAMA*. 2010;304(4):452–60.
2. Nocturne G, Mariette X. Sjogren syndrome-associated lymphomas: an update on pathogenesis and management. *Br J Haematol*. 2015;168(3):317–27.
3. Ambrosi A, Wahren-Herlenius M. Update on the immunobiology of Sjogren's syndrome. *Curr Opin Rheumatol*. 2015;27(5):468–75.
4. Vitali C, Bombardieri S, Jonsson R, Moutsopoulos HM, Alexander EL, Carsons SE, et al. Classification criteria for Sjogren's syndrome: a revised version of the European criteria proposed by the American-European consensus group. *Ann Rheum Dis*. 2002;61(6):554–8.
5. Shiboski SC, Shiboski CH, Criswell L, Baer A, Challacombe S, Lanfranchi H, et al. American College of Rheumatology classification criteria for Sjogren's syndrome: a data-driven, expert consensus approach in the Sjogren's international collaborative clinical alliance cohort. *Arthritis Care Res (Hoboken)*. 2012;64(4):475–87.
6. Brito-Zeron P, Theander E, Baldini C, Seror R, Retamozo S, Quartuccio L, et al. Early diagnosis of primary Sjogren's syndrome: EULAR-SS task force clinical recommendations. *Expert Rev Clin Immunol*. 2016;12(2):137–56.
7. Jousse-Joulin S, Milic V, Jonsson MV, Plagou A, Theander E, Luciano N, et al. Is salivary gland ultrasonography a useful tool in Sjogren's syndrome? A systematic review. *Rheumatology (Oxford)*. 2015;55(5):789–800.
8. Stone JH, Khosroshahi A, Deshpande V, Chan JK, Heathcote JG, Aalberse R, et al. Recommendations for the nomenclature of IgG4-related disease and its individual organ system manifestations. *Arthritis Rheum*. 2012;64(10):3061–7.
9. Brito-Zeron P, Ramos-Casals M, Bosch X, Stone JH. The clinical spectrum of IgG4-related disease. *Autoimmun Rev*. 2014;13(12):1203–10.
10. Guma M, Firestein GS. IgG4-related diseases. *Best Pract Res Clin Rheumatol*. 2012;26(4):425–38.
11. Vasaitis L. IgG4-related disease: a relatively new concept for clinicians. *Eur J Intern Med*. 2016;27:1–9.
12. Ghably JG, Borthwick T, O'Neil TJ, Youngberg GA, Datta AA, Krishnaswamy G. IgG4-related disease: a primer on diagnosis and management. *Ann Allergy Asthma Immunol*. 2015;114(6):447–54.
13. Badhey AK, Kadakia S, Carrau RL, Iacob C, Khorsandi A. Sarcoidosis of the head and neck. *Head Neck Pathol*. 2015;9(2):260–8.
14. Baughman RP, Teirstein AS, Judson MA, Rossman MD, Yeager H Jr, Bresnitz EA, et al. Clinical characteristics of patients in a case control study of sarcoidosis. *Am J Respir Crit Care Med*. 2001;164(10 Pt 1):1885–9.
15. Govender P, Berman JS. The diagnosis of sarcoidosis. *Clin Chest Med*. 2015;36(4):585–602.
16. Wessendorf TE, Bonella F, Costabel U. Diagnosis of sarcoidosis. *Clin Rev Allergy Immunol*. 2015;49(1):54–62.
17. Wijsenbeek MS, Culver DA. Treatment of sarcoidosis. *Clin Chest Med*. 2015;36(4):751–67.
18. Vashishta R, Gillespie MB. Salivary endoscopy for idiopathic chronic sialadenitis. *Laryngoscope*. 2013;123(12):3016–20.
19. Koch M, Zenk J, Bozzato A, Bumm K, Iro H. Sialoscopy in cases of unclear swelling of the major salivary glands. *Otolaryngol Head Neck Surg*. 2005;133(6):863–8.
20. Pace CG, Hwang KG, Papadaki ME, Troulis MJ. Sialadenitis without sialolithiasis treated by sialendoscopy. *J Oral Maxillofac Surg*. 2015;73(9):1748–52.
21. Jager DJ, Karagozoglu KH, Maarse F, Brand HS, Forouzanfar T. Sialendoscopy of salivary glands affected by Sjögren syndrome: a randomized controlled pilot study. *J Oral Maxillofac Surg*. 2016;74(6):1167–74.
22. Shacham R, Puterman MB, Ohana N, Nahlieli O. Endoscopic treatment of salivary glands affected by autoimmune diseases. *J Oral Maxillofac Surg*. 2011;69(2):476–81.
23. De Luca R, Trodella M, Vicidomini A, Colella G, Tartaro G. Endoscopic management of salivary gland obstructive diseases in patients with Sjogren's syndrome. *J Craniomaxillofac Surg*. 2015;43(8):1643–9.

Christopher G. Larsen, Carrie L. Francis,
and Chelsea S. Hamill

Key Points

1. In children, sialadenitis is more common in the parotid gland and most commonly caused by viral inflammation or juvenile recurrent parotitis (JRP).
2. Sialolithiasis occurs in children less commonly. When present, the submandibular gland is most commonly involved.
3. Sialendoscopy is a useful diagnostic and potentially therapeutic procedure in children with recurrent or refractory inflammation in the parotid or submandibular gland.
4. Imaging should be limited to ultrasound, unless a tumor is expected, to avoid undue radiation exposure in children.

Introduction

Pediatric sialadenitis accounts for up to 10% of all salivary gland pathology [1]. Viral parotitis and juvenile recurrent parotitis (JRP) are the two

most common etiologies. JRP is the most common inflammatory salivary gland disorder in children in the United States and is second only to mumps worldwide [2]. Many factors contribute to salivary gland disease in children, including viral or bacterial infections, congenital or traumatic duct obstruction, autoimmune disease, and genetic defects. In children, parotid sialadenitis is more common than submandibular sialadenitis. Tumors of the salivary glands are rare in children and rarely present with inflammatory symptoms. Salivary stones are a frequent cause of chronic or recurrent obstructive sialadenitis, though much less common in children than adults. Stones are much more common in the submandibular gland than parotid gland, in both populations.

The aim of this chapter is to present a comprehensive review of pathophysiology, clinical presentation, diagnosis, and treatment of pediatric salivary gland disorders and the emerging role of sialendoscopy in the treatment of these disorders.

C.G. Larsen, M.D. (✉)

C.S. Hamill, M.D.

Department of Otolaryngology-Head
and Neck Surgery, University of Kansas
Medical Center, Kansas City, KS 66160, USA
e-mail: clarsen@kumc.edu

C.L. Francis, M.D.

Department of Otolaryngology-Head and Neck
Surgery, University of Kansas Medical Center,
Kansas City, KS 66160, USA

Division of Pediatric Otolaryngology, Children's
Mercy Hospitals and Clinics,
Kansas City, MO 64108, USA
e-mail: cfrancis@kumc.edu

Etiologies

Viral Sialadenitis

Viral parotitis is generally caused by the paramyxovirus. Mumps is the most common infectious inflammatory condition but has become much less common with immunization. The effectiveness of the vaccine approaches 90% [3, 4]. However, clinicians should distinguish mumps from other causes of sialadenitis in the pediatric population, as outbreaks have occurred among highly vaccinated individuals [3, 4]. Mumps is a systemic illness that infects the salivary glands without producing purulence. Prodromal symptoms include fever, headache, and malaise, with subsequent gland involvement. Additional exocrine glands can be affected, and systemic complications, such as encephalitis, are not uncommon. Serologic assays are useful in confirming the diagnosis. Other viruses (EBV, parainfluenza, HIV) are less commonly associated with salivary gland inflammation.

Bacterial Sialadenitis

Pediatric bacterial sialadenitis most commonly occurs in children younger than 2 months and is usually in the parotid gland [5, 6]. Predisposing factors for pediatric bacterial sialadenitis include chronic tonsillitis, dental abscess, and mumps parotitis [7–9]. In the newborn period, it usually presents as an acute single episode; however, after infancy, multiple recurrent episodes can occur and can continue into late adolescence [7, 8, 10]. Bacterial sialadenitis in neonates typically occurs within the first 2 weeks of life and, unlike adult parotitis, generally occurs bilaterally. Generally, neonatal bacterial parotitis occurs in premature infants due to the greater propensity of dehydration, duct stasis, and immune suppression [7, 8, 10].

Bacterial sialadenitis is characterized by acute swelling of the cheek that extends to the angle of the mandible. It is usually distinguished from other inflammatory diseases of the salivary gland by the presence of pus. In the absence of purulence,

fever and leukocytosis support the diagnosis. Any purulence should be sent for gram stain as well as aerobic and anaerobic culture. While awaiting the culture results, antistaphylococcal penicillinase-resistant antibiotics should be started. The pathogens recovered in acute bacterial sialadenitis depend on the age group. In the neonate, *Staphylococcus aureus*, gram-positive cocci, and gram-negative bacilli are the predominant organisms [11, 12]. Unlike the neonate, however, children older than 1 year of age predominately grow *Staphylococcus aureus*, streptococcus species, and anaerobic pathogens [5, 12, 13].

Progression of bacterial sialadenitis to abscess formation, although rare, should be evaluated with imaging such as ultrasound and often occurs as a result of *Streptococcus pneumoniae* [14]. Due to the vertical separation of the parotid fascia, a fluctuant mass is seldom appreciated in acute parotitis, so clinical signs such as progressive edema, induration, and sepsis are usually indicative of a parotid abscess [7]. If progression to abscess formation occurs in the submandibular gland, it may result in floor of mouth edema and respiratory compromise so attentive observation must be initiated.

Mycobacterial Infection

Mycobacterium is known to cause infections of the head and neck; however, they have rarely been reported to involve the parotid gland [6, 15]. Infection of the glandular parenchyma is usually secondarily spread from the intraglandular and periglandular lymph nodes [16]. This is due to the fact that the salivary glands are typically spared from direct mycobacterial infection because of the proteolytic enzymes with antibacterial properties and the continuous flow of saliva preventing stagnation and growth [6, 16]. A mycobacterial abscess presents as a chronic, non-tender salivary gland mass, nonresponsive to antimicrobials, and can often be indistinguishable from a neoplasm [6, 15–18]. Because of this, culture, histology, chest XR, and PPD are all used to aid in diagnosis; however, FNA proves most valuable as,

histologically, granulomas will be present [6, 15, 16]. If histology proves to be noncontributory, parotidectomy is essential to differentiate this infection from other neoplasms [6, 16].

These mycobacterial infections can be caused by *Mycobacterium tuberculosis* (TB) as well as nontuberculous mycobacteria (NTM) such as *Mycobacterium avium-intracellulare* [12]. In order to differentiate between TB and NTM, a Wade-Fite stain can be performed to detect differences in the glycoprotein coat [15]. It is important to differentiate TB from NTM because the management differs. A diagnosis of TB requires possible treatment of any contacts and initiation of rifampin, isoniazid, ethambutol, and pyrazinamide [15]. NTM on the other hand appears to have nonperson-to-person contact and requires azithromycin, clarithromycin, and ethambutol treatment [15]. For either case, if patients are nonresponsive to or noncompliant with treatment, surgical resection should be initiated. Cooperation between the otolaryngologist and the pediatrician is also extremely important for effective management of other organ systems as it has been reported that 25% of patients who had TB in the parotid gland had concomitant pulmonary infection [6, 15].

Juvenile Recurrent Parotitis

Juvenile recurrent parotitis (JRP) is characterized as recurrent episodes of inflammation of the parotid gland. Symptoms include jaw swelling, pain, and redness, associated with fever and malaise. Most cases are unilateral; however, when bilateral cases occur, one side is usually dominant [19, 20]. The true incidence of JRP is unknown as most reports are case series. Studies show predominance in males, though the sex distribution is thought to flip if events continue into adulthood [20–22]. The age distribution is biphasic, typically occurring between ages 2 and 6 and again at the start of puberty [20, 21, 23–25]. The natural history is recurrence; however, most authors agree that this is a self-limited disease that resolves sometime after puberty and rarely extends into adulthood [19–21].

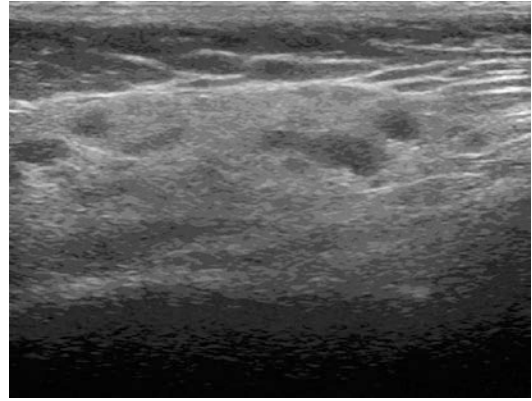


Fig. 12.1 Ultrasound images of “moth-eaten” parotid gland with multiple hypoechoic areas consistent with salivary stasis (Image courtesy of M. Boyd Gillespie)

The diagnosis of juvenile recurrent parotitis is made clinically in patients with a history of recurrence and physical exam findings. More recently, ultrasonographic findings are consistently being used to make the clinical diagnosis [19] (Fig. 12.1). The minimum requirement for diagnosis is two episodes, although most patients are only diagnosed after multiple episodes have occurred [26]. Hackett et al. reported an average of 4.7 episodes with a range between two and nine events [26]. Typically, symptoms last 4 to 7 days for each episode [24]. The interval between attacks varies individually, with episodes occurring every 3–4 months to ten times per year [21, 24]. Treatment is based on the frequency and severity of disease. Early recognition of JRP and treatment of this pathology are of utmost importance to prevent further progression along the inflammatory cascade. Each attack may further tissue destruction and function of the gland. For this reason, active and early intervention when the acute inflammation subsides is prudent.

The link between genetics, immunologic disease, allergy, and sialadenitis is not completely understood. Although early studies have excluded a relationship connecting these factors, bilateral or multiglandular disease, especially in a setting of arthritis or atypical rashes, should warrant autoimmune workup and/or rheumatology referral [22, 23, 27]. Autoimmune disease is

also less likely, in that autoantibodies are usually absent [23, 27]. However, others have supported such an association based on cytologic and pathologic findings of inflammation, vasculitis, tissue destruction, and stenosis [24, 28]. IgA deficiency could predispose to infection, while genetic factors influence the overall immune response [24, 29, 30].

It has been difficult to identify one specific etiology pertaining to JRP. There are case reports that link it to immune deficiency, genetics, and allergy; however, no causality has been proven because in many early, large studies of JRP, these conditions were not found to contribute to this disease [23, 27, 30–32]. Conventional thought had been that an ascending infection was a primary event, while the development of sialectases is a secondary change predisposing to chronic low-grade inflammation with acute exacerbations [21, 23, 27]. Now, the general consensus is that JRP is a multifactorial process that multiple factors, independently or in combination, can result in recurrent inflammation [19, 33].

Clinicians have proposed a specific sequence of events, deemed the “salivary gland inflammatory cycle” that causes a structural change leading to the recurrent sialadenitis. Predisposing factors of the inflammatory cycle include dehydration, infection, congenital ductal abnormalities, and/or autoimmune factors [21, 23, 27]. The cycle starts with decreased salivary flow, leading to inflammation and tissue destruction. This tissue destruction would then cause ductal dysfunction, metaplasia, and increased mucinous secretion yielding mucus, debris (including desquamated cells), and stenosis [19, 21, 22, 33, 34]. Mucus plugs or stenosis would then cause post-obstructive sialectases and ultimately complete the full circle and return to decreased salivary flow [19, 21, 22, 33]. Support of this theory comes from histologic specimens showing dilated ducts (sialectases) with lymphocytic infiltration in the surrounding tissues and epithelium [23, 27]. Additional components that can result from or add to the cycle include the precipitation of proteins and calculus formation, both leading to further obstruction, decreased salivary flow, and inflammation [33].

Sialolithiasis in Children

Stones in children, as in adults, occur most frequently in the submandibular gland. In fact, 80–90% of stones in children are found in the submandibular gland [35–37]. Less than 5% of total cases of sialolithiasis occur in children, so most of the literature on stones pertains to adults [36, 38]. Salivary stones in pediatric cases are smaller, occur distally within the duct, and present with shorter symptom duration [38, 39]. Ultrasound is the diagnostic test of choice to avoid radiation exposure in children. A case could also be made for proceeding directly to surgical intervention in patients with recurrent post-prandial pain and swelling. Sialendoscopy has a greater sensitivity than conventional radiology, ultrasound, and MRI.⁵⁵ Retrospective review of 5-year experience by Martins-Carvalho et al. [20] showed that pre-sialendoscopy US was only successful in predicting pathology in seven of 38 (18%) cases. Of the ten patients with lithiasis found using sialendoscopy, only four had been detected using preoperative ultrasonography.

Clinical Presentation and Diagnosis

The most common presenting symptoms of acute sialadenitis whether due to infection or JRP are pain, fever, and erythema overlying the affected gland(s). Symptoms are usually unilateral; in bilateral cases, symptoms are more prominent on one side [5]. Pain is elicited with salivation, mastication, and/or swallowing. Trismus can be present. The ostium of the duct(s) is erythematous and edematous. Purulence and/or inspissated mucus may be expressed by manual palpation and gentle pressure applied over the salivary gland and duct. In severe cases of infectious sialadenitis, systemic complications can extend regionally into adjacent tissues (cellulitis) or systemically spread to distal sites [5]. Clinical signs vary based on the site of inflammation and an acute or chronic presentation.

Sialadenitis should be differentiated clinically from periodic sialadenosis. Sialadenosis is defined as non-painful, noninflammatory salivary

gland prominence or swelling. It can be unilateral or bilateral. It can be found in pediatric patients with diabetes mellitus, insulin resistance syndrome, and bulimia. Sialadenosis management should focus on diagnosing/treating underlying conditions, ruling out underlying or occult tumors, and avoiding surgical intervention or sialendoscopy.

Reports have also described immune deficiency in association with sialadenitis. Several authors have reported IgA deficiency in patients presenting with recurrent parotitis through serology and immunofluorescent studies [29, 31, 32]. Salivary gland involvement in children with human immunodeficiency virus (HIV) is well recognized. Characteristically, one or both glands are firm, nontender, and chronically enlarged. Xerostomia may also be a presenting symptom. Infiltration of CD8-positive lymphocytes, possibly as a result of HIV, Epstein-Barr virus (EBV), or an interaction between the two, enlarges the gland [40]. The diagnosis of HIV parotitis is usually clinical with typical findings of HIV (multiple parotid cysts).

Management

The treatment of sialadenitis is usually conservative and directed toward its etiology. Acute infections are treated with appropriate antistaphylococcal antibiotics. Viral sialadenitis, or mumps, is managed supportively, as it is a self-limited disease, and no antiviral agent is available for treatment. Sialadenitis in association with autoimmune disease, immune deficiency, and genetic factors is managed conservatively and according to the underlying systemic condition. Chronic sialadenitis and JRP have a multifactorial etiology, and management recommendations have not been uniform [19, 21, 24]. Over the last 20 years, there has been a rising interest in the surgical management of both sialolithiasis and chronic or recurrent acute sialadenitis. Many authors have contributed to the advancements of conventional surgical procedures to nonsurgical and minimally invasive procedures and the development of treatment algorithms [41].

The conservative management of acute sialadenitis consists of analgesics (NSAIDs or systemic steroids), adequate hydration, warm massage, antibiotics (when pus is identified at duct ostium), and sialogogues. The goal of these conservative measures is to provide symptomatic relief and prevent permanent parenchymal damage. Broad antimicrobial therapy is indicated to cover aerobic and anaerobic pathogens [5, 13]. Analgesics are used to provide pain relief. Both have been reported to rapidly decrease swelling and prevent damage to the parenchyma [20, 21, 38]. Rehydration is important as dehydration may exacerbate the inflammatory response [5, 21, 33]. Warm massage and sialogogues are reported to stimulate salivary flow [21, 23]. In cases where conservative management fails to resolve acute symptoms, abscess development should be suspected. CT or ultrasound should be obtained for confirmation and preoperative surgical planning. Abscess formation requires incision and drainage.

Acute infection and inflammation are relative contraindications to surgical intervention. Duct manipulation should not be performed in the setting of acute infection due to concerns about scarring, bleeding, ductal perforation, and exacerbation of the inflammatory process [5, 21]. Thus, medical therapy to decrease swelling, pain, infection, and inflammation should occur prior to surgical intervention.

Recurrent acute sialadenitis of the submandibular gland in children and JRP are far more difficult to manage. Treatment recommendations have ranged from conservative to aggressive and have been not uniformly accepted. This has been, in part, due to its scarcity, uncertain etiology, and natural history. Prevention of sialadenitis by using prophylactic antibiotics has been suggested, but there is little evidence to support this practice [21]. Some authors have suggested expectant management as many patients are known to recover spontaneously [21].

Several techniques have been advocated to control repeated attacks of inflammation. Traditional management involves gland excision, salivary gland duct ligation, blind duct dilation and lavage, and tympanic neurectomy [21, 42]. Complications include nerve damage, asymmetric

scarring, hemorrhage, infection, sialoceles, hematomas, wound infection, and salivary fistula [42]. Duct ligation and dilation/lavage have variable outcomes [21]. Some studies found that sialography alone resulted in beneficial clinical effects [21, 41]. Recently, there has been a paradigm shift in the management of sialadenitis and sialolithiasis toward gland preservation techniques that employ sialendoscopy.

Through the work of Nahlieli et al., Marchal et al., and that of many others, salivary endoscopy has been validated in pediatrics as a safe and efficacious tool for the diagnosis and treatment of salivary gland disorders [20, 25, 26, 33, 36, 38, 43–48]. Shacham et al., Martins-Carvalho et al., and Nahlieli et al. report the largest series of interventional pediatric sialendoscopy [20, 25, 43]. After a single procedure, they describe over 80–90% symptom resolution in 70, 38, and 23 patients, respectively. The other referenced studies describe similar success rates [25, 26, 33, 47, 48].

Direct endoscopic visualization can help identify or confirm a specific pathology. Common findings of chronic sialadenitis include a widened Stenson's duct; white, avascular appearance of the duct; stenosis; mucus plug/debris; and salivary stones within the duct (Figs. 12.1, 12.2, 12.3, 12.4) [20, 43, 48]. Marchal and colleagues reported a 98% success rate at identifying ductal and parenchymal pathology [49]. While avascularity, debris, and salivary stones are readily visualized, stenosis is diagnosed based on narrowing of the duct under endoscopic control and difficulty introducing and mobilizing the sialendoscope [43]. Recently, duct-dilating balloons have been developed, and the authors have been using very small Fogarty balloons to dilate strictures. Sialendoscopy has been reported to have better sensitivity in diagnosing salivary stones in children than conventional radiology, CT, ultrasonography, and MRI [39, 43, 44, 50]. These same authors found smaller stones in the pediatric population, finding those missed on radiologic evaluation to be present on endoscopy.

In addition to diagnosis, interventional sialendoscopy has advanced to address the variety of

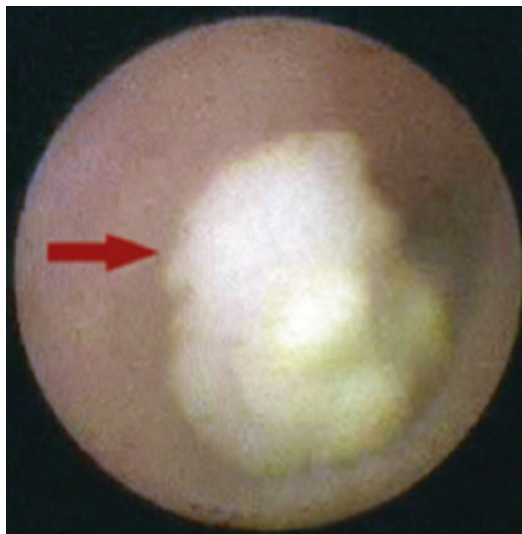


Fig. 12.2 Mucus plug and debris as visualized on diagnostic sialendoscopy

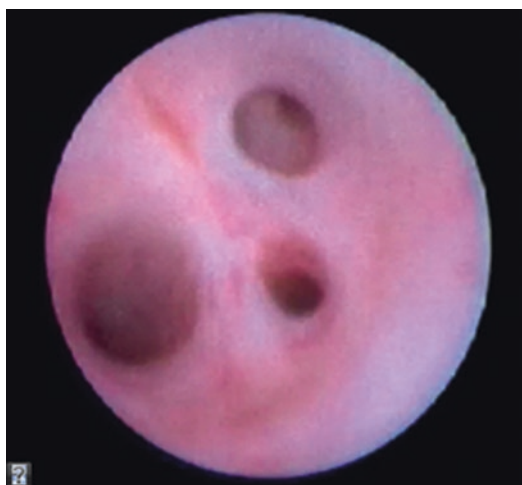

Fig. 12.3 White avascular appearance of the ductal layer without the natural proliferation of blood vessels

factors causing sialadenitis. Inflammatory changes resulting in tissue damage, strictures, and organic debris can successfully be treated with dilation, lavage, and/or corticosteroid application [20, 25, 28, 44, 45]. Dilation of stenosis using the endoscope, lasers, balloon catheters, or high-pressure saline solution has been described [20, 36, 43, 48]. Mucus plugs and other debris are flushed with

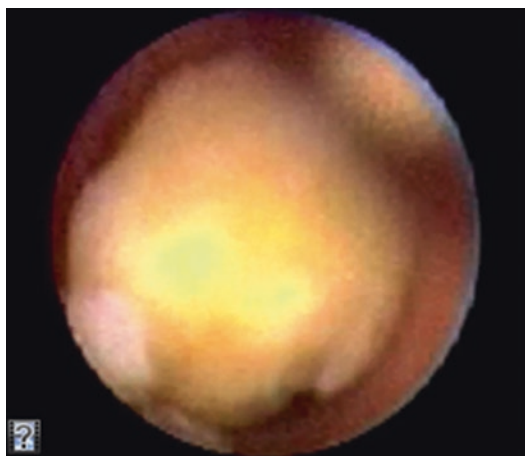


Fig. 12.4 Mobile salivary stone amenable to endoscopic basket extraction

saline irrigation throughout the procedure. Corticosteroid application is an accepted practice though no formal studies have investigated outcomes of the technique [19, 20, 26, 33, 36, 37, 43, 45]. Hydrocortisone, triamcinolone, and prednisolone have all been applied. In theory, topical steroid applications prevent scarring and restenosis and may decrease inflammation in chronic inflammatory sialadenitis, like JRP.

A 2015 systematic review and meta-analysis by Ramakrishna et al. identified seven papers relevant to sialendoscopy in the management of JRP [51]. Evidence was level 3 and 4 but showed success rates for no further episodes ($n = 120$) of 73% by patient and 81% by gland. There were no major complications.

Pediatric sialendoscopy is also applied successfully to obstructive symptoms resulting from sialolithiasis. Though the efficacy of sialendoscopy alone is well reported, combined procedures may be required, with similar or improved success rates [26, 37, 43, 50]. Reports have suggested that retrieval success is dependent on size. For stones in children greater than 2–3 mm (parotid and submandibular gland, respectively), most authors employ additional techniques [49, 52]. Stone fragmentation can be applied with a microdrill or laser through the sialendoscope working channel or lithotripsy prior to extraction

[36, 43, 45]. Other alternatives to complete sialendoscopic extraction for giant (>15 mm), proximal, or intraglandular stones include endoscopy combined with intraoral sialolithotomy [36, 38, 43, 50, 53]. Lastly, excision of the gland is considered for refractory cases [26, 42].

Postoperative stenting is not a uniform practice [37]. It is considered in cases of significant stenosis or injury. When employed, stents are often left in place for 2–4 weeks to allow adequate healing time [37].

Salivary endoscopy is most commonly performed under general anesthesia. However, in cases of inflammatory disease, older children may tolerate an office-based procedure with local anesthesia. Konstantinidis et al. reported seven out of eight children who underwent sialendoscopy and dilation after topical anesthetic and intraductal injection [46]. No major complications were reported. More than half of these children were symptom-free; two experienced one recurrence, and one required repeat sialendoscopy. Older children frequently tolerate office-based steroid injection, and there is some evidence that ductal corticosteroid infusion (DCI) may yield similar results as sialendoscopy in JRP patients [54]. This study was limited by small number of patients (12) and short follow-up (mean 3.8 months), and all procedures were done under general anesthesia.

Complications of sialendoscopy are uncommon and usually minor, resolving without permanent complication [26, 33, 37, 43, 44, 52]. Major complications are duct avulsion and immediate postoperative airway compromise. Minor complications include duct wall perforation, nerve paresthesia, postoperative infection, traumatic ranula, and iatrogenic duct stenosis.

Procedural Approach

One key difference between pediatric and adult sialendoscopy is concern about volume of irrigation. Pediatric patients have less tolerance of swelling, especially in the submandibular region,

before airway compromise becomes a concern. There have been complications of airway compromise [20] due to excessive irrigation, so occasional gland massage and drainage of irrigant are recommended.

Duct lumen caliber in children limits scope size as well. Diagnostic 0.8 mm single port (for irrigation) scopes are occasionally utilized in children but rarely needed in adults. The parotid and submandibular gland duct anatomy is similar in children and adults. The caliber of each duct tends to be about 1 mm smaller in children than adults. As a general rule, the maximum size stone that can be removed in children without fragmentation is 3 mm in the submandibular duct and 2 mm in the parotid duct.

One disadvantage to sialendoscopy in children is the need for general anesthesia. *Konstantinidis I*, et al. reported that they were successful in performing sialendoscopy with local anesthesia in seven of nine pediatric patients treated [46]. Thus, local and or topical anesthesia should be considered in older and or more mature pediatric patients.

Conclusion

Sialadenitis in the pediatric population accounts for up to 10% of all salivary gland disease. Viral parotitis and juvenile recurrent parotitis (JRP) are the two most common etiologies. Many factors contribute to salivary gland disease in children, including viral or bacterial infections, congenital or traumatic duct obstruction (i.e., after lingual frenulotomy), autoimmune disease, and genetic defects. In children, parotid sialadenitis is more common than submandibular sialadenitis. Tumors of the salivary glands are rare in children and rarely present with inflammatory symptoms. Salivary stones are a frequent cause of chronic or recurrent obstructive sialadenitis, though much less common in children than adults. Stones are much more common in the submandibular gland than parotid gland, in both populations.

In the United States, the most common diagnosis related to sialadenitis in children is juvenile recurrent parotitis. Prior to sialendoscopy, treatment for this morbid and painful condition had been challenging. Sialendoscopy is a diagnostic and potentially therapeutic procedure that is minimally invasive, safe, and effective in reducing the proportion of patients experiencing disease recurrence. This procedure is also very helpful in reducing recurrent disease flares and removing obstructive sialoliths in children, thus preserving gland function without the potential morbidity associated with open gland excision.

References

1. Francis CL, Larsen CG. Pediatric sialadenitis. *Otolaryngol Clin N Am*. 2014;47(5):763–8.
2. Schneider H, Koch M, Kunzel J, et al. Juvenile recurrent parotitis: a retrospective comparison of sialendoscopy versus conservative therapy. *Laryngoscope*. 2014;124(2):451–5.
3. Cohen C, White JM, Savage EJ, et al. Vaccine effectiveness estimates, 2004–2005 mumps outbreak, England. *Emerg Infect Dis*. 2007;13(1):12–7.
4. Mumps outbreak on a University Campus—California, 2011. *MMWR Morb Mortal Wkly Rep*. 2012;61(48):986–9.
5. Brook I. Diagnosis and management of parotitis. *Arch Otolaryngol Head Neck Surg*. 1992;118(5):469–71.
6. Errami N, Benjelloun A, et al. Tuberculosis of the parotid gland: histology surprise. *Pan Afr Med J*. 2015;20:343.
7. Bradley PJ. Microbiology and management of sialadenitis. *Curr Infect Dis Rep*. 2002;4(3):217–24.
8. David R, O'Connel EJ. Suppurative parotitis in Children. *Am J Dis Child*. 1970;119:332–5.
9. Preshall KE, Koopmann JR, Coulthard SW. Sialadenitis in children. *Int J Pediatr Otorhinolaryngol*. 1986;11(2):199–203.
10. Boulyana M. Acute neonatal parotitis with late-onset septic shock due to *Streptococcus agalactiae*. *Case Rep Pediatr*. 2014;2014:3.
11. Brook I. Suppurative parotitis caused by anaerobic bacteria in newborns. *Pediatr Infect Dis J*. 2002;21(1):81–2.
12. Brook I. The bacteriology of salivary gland infections. *Oral Maxillofac Surg Clin North Am*. 2009;21(3):269–74.
13. Brook I, Frazier EH, Thompson DH. Aerobic and anaerobic microbiology of acute suppurative parotitis. *Laryngoscope*. 1991;101(2):170–2.

14. Jones HE. Recurrent parotitis in children. *Arch Dis Child.* 1953;28:182–6.
15. Jervis PN, Lee JA, Bull PD. Management of non-tuberculous mycobacterial parotitis in children: the Sheffield otolaryngology experience. *Clin Otolaryngol Allied Sci.* 2001;23(3):243–8.
16. Holmes S, Gleeson MJ, Cawson RA. Mycobacterial disease of the parotid gland. *Oral Surg Oral Med Oral Pathol Oral Radiol Endod.* 2000;90:292–8.
17. Hankins D, Kelly M, Vijayan V. Mycobacterium simiae infection of the parotid gland in an immunocompetent child. *J Pediatric Infect Dis Soc.* 2013;2(4):394–6.
18. O'Connell JE, George MK, Speculand B, Pahor AL. Mycobacterial infection of the parotid gland: an unusual cause of parotid swelling. *J Laryngol Otol.* 1993;21(3):561–4.
19. Katz P, Hartl DM, Guerre A. Treatment of juvenile recurrent parotitis. *Otolaryngol Clin N Am.* 2009;42(6):1087–91.
20. Nahlieli O, Shacham R, Shlesinger M, Eliav E. Juvenile recurrent parotitis: a new method of diagnosis and treatment. *Pediatrics.* 2004;114(1):9–12.
21. Chitre VV, Premchandra DJ. Recurrent parotitis. *Arch Dis Child.* 1997;77(4):359–63.
22. Watkin GT, Hobsley M. Natural history of patients with recurrent parotitis and punctate sialectasis. *Br J Surg.* 1986;73(9):745–8.
23. Ericson S, Zetterlund B, Ohman J. Recurrent parotitis and sialactasis in childhood. Clinical, radiologic, immunologic, bacteriologic, and histologic study. *Ann Otol Rhinol Laryngol.* 1991;100(7):527–35.
24. Leerdam CM, Martin HC, Isaacs D. Recurrent parotitis of childhood. *J Paediatr Child Health.* 2005;41(12):631–4.
25. Shacham R, Droma EB, London D, Bar T, Nahlieli O. Long-term experience with endoscopic diagnosis and treatment of juvenile recurrent parotitis. *J Oral Maxillofac Surg.* 2009;67(1):162–7.
26. Hackett AM, Baranano CF, Reed M, Duvvuri U, Smith RJ, Mehta D. Sialendoscopy for the treatment of pediatric salivary gland disorders. *Arch Otolaryngol Head Neck Surg.* 2012;138(10):912–5.
27. Konno A, Ito E. A study on the pathogenesis of recurrent parotitis in childhood. *Ann Otol Rhinol Laryngol Suppl.* 1979;88(6 Pt 4 Suppl 63):1–20.
28. Shacham R, Puterman MB, Ohana N, Nahlieli O. Endoscopic treatment of salivary glands affected by autoimmune diseases. *J Oral Maxillofac Surg.* 2011;69(2):476–81.
29. Friis B, Karup Pedersen F, Schiødt M, Wiik A, Høj L, Andersen V. Immunological studies in two children with recurrent parotitis. *Acta Paediatr Scand.* 1983;72(2):265–8.
30. Reid E, Douglas F, Crow Y, Hollman A, Gibson J. Autosomal dominant juvenile recurrent parotitis. *J Med Genet.* 1998;35(5):417–9.
31. Fazekas T, Wiesbauer P, Schroth B, Potschger U, Gadner H, Heitger A. Selective IgA deficiency in children with recurrent parotitis of childhood. *Pediatr Infect Dis J.* 2005;24(5):461–2.
32. Shkalim V, Monselise Y, Mosseri R, Finkelstein Y, Garty BZ. Recurrent parotitis in selective IgA deficiency. *Pediatr Allergy Immunol.* 2004;15(3):281–3.
33. Jabbour N, Tibesar R, Lander T, Sidman J. Sialendoscopy in children. *Int J Pediatr Otorhinolaryngol.* 2010;74(4):347–50.
34. Chuangqi Y, Chi Y, Lingyan Z. Sialendoscopic findings in patients with obstructive sialadenitis: long-term experience. *Br J Oral Maxillofac Surg.* 2013;51(4):337–41.
35. Bodner L, Fliss DM. Parotid and submandibular calculi in children. *Int J Pediatr Otorhinolaryngol.* 1995;31(1):35–42.
36. Faure F, Querin S, Dulguero P, Froehlich P, Disant F, Marchal F. Pediatric salivary gland obstructive swelling: sialendoscopic approach. *Laryngoscope.* 2007;117(8):1364–7.
37. Strychowsky JE, Sommer DD, Gupta MK, Cohen N, Nahlieli O. Sialendoscopy for the management of obstructive salivary gland disease: a systematic review and meta-analysis. *Arch Otolaryngol Head Neck Surg.* 2012;138(6):541–7.
38. Nahlieli O, Eliav E, Hasson O, Zagury A, Baruchin AM. Pediatric sialolithiasis. *Oral Surg Oral Med Oral Pathol Oral Radiol Endod.* 2000;90(6):709–12.
39. Chung MK, Jeong HS, Ko MH, et al. Pediatric sialolithiasis: what is different from adult sialolithiasis? *Int J Pediatr Otorhinolaryngol.* 2007;71(5):787–91.
40. Pinto A, De Rossi SS. Salivary gland disease in pediatric HIV patients: an update. *J Dent Child (Chic).* 2004;71(1):33–7.
41. Fritsch MH. Sialendoscopy and lithotripsy: literature review. *Otolaryngol Clin N Am.* 2009;42(6):915–26.
42. Capaccio P, Torretta S, Pignataro L. The role of adenectomy for salivary gland obstructions in the era of sialendoscopy and lithotripsy. *Otolaryngol Clin N Am.* 2009;42(6):1161–71.
43. Martins-Carvalho C, Plouin-Gaudon I, Quenin S, et al. Pediatric sialendoscopy: a 5-year experience at a single institution. *Arch Otolaryngol Head Neck Surg.* 2010;136(1):33–6.
44. Faure F, Froehlich P, Marchal F. Paediatric sialendoscopy. *Curr Opin Otolaryngol Head Neck Surg.* 2008;16(1):60–3.
45. Bruch JM, Setlur J. Pediatric sialendoscopy. *Adv Otorhinolaryngol.* 2012;73:149–52.
46. Konstantinidis I, Chatziavramidis A, Tsakirpoulou E, Malliari H, Constantinidis J. Pediatric sialendoscopy under local anesthesia: limitations and potentials. *Int J Pediatr Otorhinolaryngol.* 2011;75(2):245–9.
47. Capaccio P, Sigismund PE, Luca N, Marchisio P, Pignataro L. Modern management of juvenile recurrent parotitis. *J Laryngol Otol.* 2012;126(12):1254–60.

48. Quenin S, Plouin-Gaudon I, Marchal F, Froehlich P, Disant F, Faure F. Juvenile recurrent parotitis: sialendoscopic approach. *Arch Otolaryngol Head Neck Surg.* 2008;134(7):715–9.
49. Marchal F, Dulguerov P. Sialolithiasis management: the state of the art. *Arch Otolaryngol Head Neck Surg.* 2003;129(9):951–6.
50. Rahmati R, Gillespie MB, Eisele DW. Is sialendoscopy an effective treatment for obstructive salivary gland disease? *Laryngoscope.* 2013;123(8):1828–9.
51. Ramakrishna J, Strychowsky J, Gupta M, Sommer DD. Sialendoscopy for the management of juvenile recurrent parotitis: a systematic review and meta-analysis. *Laryngoscope.* 2015;125(6):1472–9.
52. Walvekar RR, Razfar A, Carrau RL, Schaitkin B. Sialendoscopy and associated complications: a preliminary experience. *Laryngoscope.* 2008;118(5):776–9.
53. Wallace E, Tauzin M, Hagan J, Schaitkin B, Walvekar RR. Management of giant sialoliths: review of the literature and preliminary experience with interventional sialendoscopy. *Laryngoscope.* 2010;120(10):1974–8.
54. Roby BB, Mattingly J, Jensen EL, Gao D, Chan KH. Treatment of juvenile recurrent parotitis of childhood: an analysis of effectiveness. *JAMA Otolaryngol Head Neck Surg.* 2015;141(2):126–9.

Andrew B. Davis and Henry T. Hoffman

Key Points

1. Sialadenosis (sialosis) is a chronic, noninflammatory, nonneoplastic, bilateral, often painless enlargement of the salivary glands, most frequently affecting the parotid glands, with no sex predilection and frequently affecting the third to seventh decade.
2. Approximately 50% of cases are associated with an underlying disease process, most commonly diabetes, alcoholism, cirrhosis, anorexia/bulimia, malnutrition, metabolic syndromes, and medications.
3. The pathogenesis of sialadenosis is unknown, but the current weight of evidence supports the theory that it arises from an autonomic neuropathy.
4. Initial clinical evaluation consists of a thorough history and physical examination to direct further investigation that may include blood testing to narrow the large differential diagnosis characterizing bilateral parotid swelling.
5. Diagnostic imaging is useful in supporting the diagnosis of sialadenosis and includes ultrasound, CT, and sialography.
6. Fine-needle aspiration (FNA) and open biopsy may be useful in selected cases. The histologic finding of acinar enlargement supports the diagnosis of sialadenosis.
7. Management involves addressing the associated medical conditions with the recognition that sialadenosis is not always reversed despite successful treatment of the underlying medical abnormality. Conservative symptomatic management can also be started at the same time, which can include heat application and sialogogues.
8. More invasive management is reserved for refractory cases to treat pain and/or aesthetic concerns, which includes botulinum neurotoxin injection, pilocarpine, steroid insufflation, tympanic neurectomy, and parotidectomy.

Introduction

Sialadenosis (sialosis) is considered a rare condition that was initially described in the early 1900s. It is defined as noninflammatory, nonneoplastic, bilateral, parenchymatous enlargement of the salivary glands [1–8]. Involvement most often affects the parotid gland but may also involve the submandibular gland or other minor salivary glands (Fig. 13.1). Sialadenosis is characterized by chronic swelling that, unlike obstructive sialadenitis, is not closely associated to the stimulus of eating. Sialadenosis originally was considered as a painless disorder, but more recently it has

A.B. Davis, M.D. • H.T. Hoffman, M.D. (✉)
Otolaryngology Department, University of Iowa
Hospitals and Clinics, Iowa City, IA 52242, USA
e-mail: henry-hoffman@uiowa.edu

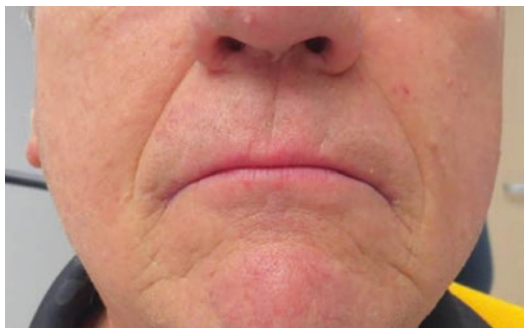

Fig. 13.1 Image of a patient with sialadenosis. This image shows the bilateral parotid enlargement present in sialadenosis [26]

been accepted that pain can be present [4]. Sialadenosis has no sex predilection and typically affects patients between the third and seventh decade [3–8]. Half of all cases of sialadenosis are associated with a recognized endocrine, metabolic, neurogenic, or nutritional disorder [8].

Anatomy

An understanding of sialadenosis and its management requires knowledge of the salivary secretory unit and its autonomic innervation. The secretory unit of the parotid gland consists of an acinus with an intercalated duct that are both surrounded by contractile myoepithelial cells [4]. The intercalated ducts condense progressively from proximal (acinar structures) to distal (Stensen's duct) as they progress from striated and then subsequently to excretory ducts. The main parotid duct, also known as Stensen's duct, has its orifice at the second maxillary molar.

The parotid gland receives equal autonomic innervation from both the sympathetic and parasympathetic systems. The gland receives parasympathetic innervation via the glossopharyngeal nerve which has its preganglionic fibers in the inferior salivary nucleus. These fibers join the glossopharyngeal nerve in which it synapses with the postganglionic cells at the otic ganglion. The postganglionic fibers join with the auriculotemporal branch of mandibular division of the trigeminal nerve. The parasympathetic innervation to the parotid regulates fluid and electrolyte

secretions. The sympathetic innervation to the parotid gland has its preganglionic fibers that originate from the thoracic spine and travel up the sympathetic trunk to synapse at the superior cervical ganglion, in which the postganglionic fibers exit and travel through the external carotid artery plexuses to connect with the parotid gland. The sympathetic innervation is responsible for stimulating production and secretion of secretory granules [5–7, 9].

Pathophysiology

Sialadenosis was first identified nearly a century ago. Despite this extensive history, its diverse association with a wide range of disease processes has not permitted identification of a direct correlation with a single inciting cause. Donath and Seifert [10] presented a morphometric analysis of sialadenosis of the parotid gland in which they found enlargement of acinar cells when compared to controls. Histologically, they identified a granular pattern to the cytoplasm attributed to an increased number of secretory granules. They also noticed degenerative changes of the myoepithelial cells and postganglionic sympathetic nerves.

The above observations led to the hypothesis that sialadenosis arises from an autonomic neuropathy associated with dysfunctional protein secretion and/or synthesis which causes acinar enlargement [1, 4, 10]. This neuropathy of the sympathetic nervous system leads to the buildup of secretory granules seen in the acinar cells and the subsequent acinar enlargement causing the overall hypertrophic glandular structure. This neuropathy can be accounted for by the number of disease processes, such as diabetes and alcoholism, associated with sialadenosis that are known to cause peripheral autonomic neuropathies [5, 7, 11].

A second hypothesis of the pathogenesis of sialadenosis implicates dysfunctional aquaporin channels as a cause for the glandular swelling. Support for this hypothesis came from a patient with central diabetes insipidus treated with exogenous antidiuretic hormone (ADH), who

subsequently developed sialadenosis. ADH is known to upregulate the synthesis of aquaporin channels; therefore, when this patient's parotid biopsy was stained for aquaporin-5, which is found on the apical surface of salivary cells and is involved in saliva production and cell volume regulation, it was found to be upregulated when compared to control. This was confirmed by the same group in a case series of nine patients who had sialadenosis, in which they concluded that aquaporins may play a role in the pathogenesis of sialadenosis [12, 13].

Evaluation

Sialadenosis is characterized by a chronic, bilateral, primarily parotid swelling that cannot be accounted for by inflammatory or neoplastic causes. Although the history and physical examination may lead to sialadenosis as the most likely diagnosis, other causes of salivary swelling may either mimic sialadenosis or coexist with it in a way that usually requires further testing.

Clinical

The etiology of bilateral parotid enlargement includes a large and diverse differential diagnosis. Sialadenosis patients complain of chronic, bilateral parotid swelling occasionally accompanied by concern about aesthetic disfigurement that may be the chief complaint leading to consultation. Xerostomia and pain have also been reported to accompany sialadenosis, although it should be noted these could arise for a number of different reasons [4, 11]. Among the recognized causes of sialadenosis, malnutrition, liver disease (often alcohol related), and diabetes are prominent. The main causes are discussed.

Malnutrition disorders, such as bulimia and anorexia nervosa, were identified as a cause for sialadenosis in 1969 [14]. It has been estimated that 10–66% of all bulimics have sialadenosis [15]. The pathogenesis for sialadenosis resulting from bulimia is uncertain, but some theories have been proposed [15]:

1. Intense, repetitive autonomic stimulation to the gland causing enlargement.
2. Possible humoral connection between the pancreas and the parotid gland.
3. Chronic regurgitation of gastric acid contents is responsible for glandular change.

Regardless of pathogenesis, many bulimics suffer from sialadenosis, which in this patient population is of special concern due to their self-esteem and body image issues. Bulimics tend to have swelling 3–6 days after a binge-purge episode. Another symptom that bulimics experience is tooth enamel erosion and dental caries ascribed to acidic contents of their regurgitation. Interestingly, the degree of enamel erosion correlates with the size of the parotid glands [15].

Alcoholism and alcoholic cirrhosis are well-known causes of sialadenosis, and much of what we know about sialadenosis result from study of these disease processes. Studies have shown that 30–80% of alcoholic cirrhotics and 26–86% of alcoholics have sialadenosis [5, 7, 16]. It is well established that alcoholism is associated with autonomic polyneuropathy. There is controversy regarding an association between sialadenosis and nonalcoholic liver disease. A study of 28 liver transplant patients with sialadenosis showed that 17 had nonalcohol-related liver disease. It has been hypothesized that an underlying nutritional deficit occurring both in alcoholic and in nonalcoholic liver disease is responsible for sialadenosis [16].

The association between diabetes and sialadenosis is well established. The rising epidemic of diabetes would be expected to be accompanied with a parallel increase in the prevalence of sialadenosis. One case series showed that 49% of patients with sialadenosis had diabetes [17]. Diabetes also presents a potential confounder in patient populations with cirrhosis and sialadenosis, since a large portion of cirrhotics have diabetes as well. The liver plays essential roles in glucose and glycogen metabolism, and with liver disease, metabolic derangements can be seen with subsequent hyperglycemia and insulin resistance. This makes it difficult to establish whether cirrhosis or the subsequent diabetes is

the major underlying factor [16]. It is important to note that along with diabetes, the rising epidemics of obesity and subsequent metabolic syndrome are known causes of sialadenosis. A significant, almost linear, correlation has been noted between BMI and parotid size due to fat cell hypertrophy [18].

Sialadenosis has also been reported in association with hypothyroidism, diabetes insipidus, acromegaly, pregnancy, use of medications especially antihypertensives, and exposure to heavy metals. The work-up should start with a comprehensive history and physical examination looking for any underlying cause of bilateral parotid enlargement [19–21]. On physical examination, the parotid enlargement associated with sialadenosis commonly results in obliteration of the groove between the ramus of the mandible and mastoid process causing a trapezoid appearance [17]. Blood testing may be done to rule out other causes of bilateral parotid enlargement when supported by clinical findings to address possible Sjögren's syndrome. Unusual presentation may warrant a more detailed serum analysis to potentially include assessment for borreliosis, toxoplasmosis, syphilis, HIV, and brucellosis. If suspected, testing for specific nutritional deficiencies could be considered to rule out pellagra, beriberi, and kwashiorkor [20].

Radiologic

Radiologic imaging can be an important tool to help narrow the differential diagnosis of bilateral parotid enlargement and support the diagnosis of sialadenosis. Ultrasound, CT, and sialography are the most common imaging modalities when investigating sialadenosis.

Ultrasound of the salivary glands is an effective imaging modality that may be helpful, but usually not definitive, in ruling out other causes of salivary swelling. Ultrasound tends to be the first imaging modality of choice due to its widespread availability and its low cost and is becoming increasingly more common to conduct in-clinic ultrasound examinations, which allows the clinician to have immediate results with less

user-dependent variability. Specifically in sialadenosis, it is important to confirm that the bilateral swelling is not of inflammatory or neoplastic origins. Sonography allows for this, by showing hyperechogenicity of the gland with no focal lesions present. In cases of sialadenosis, it is rare to see the deep lobes of the parotid gland on sonography due to the hyperechogenicity [22].

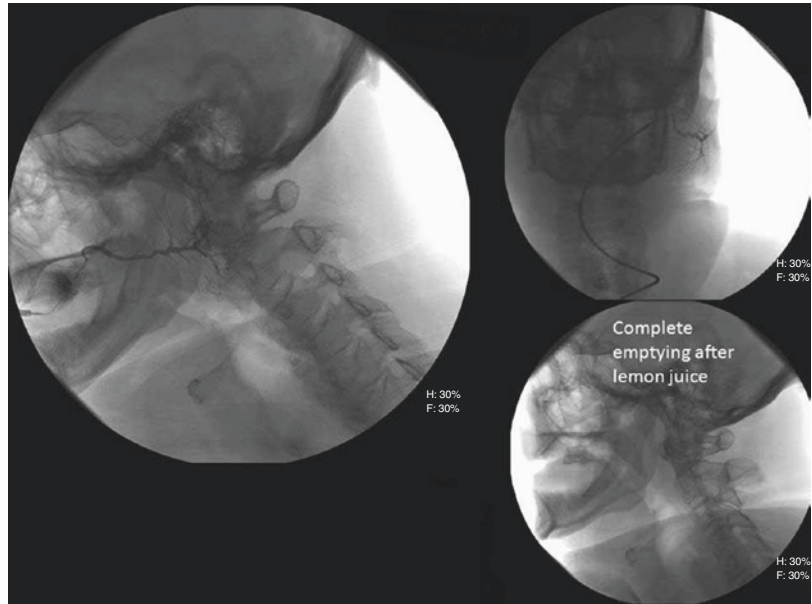
CT is more specific than other modalities and, in some cases, can serve as the only other radiographic imaging needed to confirm the diagnosis of sialadenosis. Initially in sialadenosis, acinar cell hypertrophy occurs, which on CT represents a diffuse glandular enlargement, but it is a similar density to the native parenchyma. As sialadenosis progresses, glandular parenchyma gives way to fatty infiltration, which decreases the glands attenuation, and the fat shows up as soft tissue masses (Fig. 13.2) [7, 23, 24]. This glandular enlargement is observed in the absence of other causes of glandular enlargement such as stone, tumor, or duct obstruction.

The first radiographical depiction of the salivary glands was in 1913 by Arcelin, and the term “sialographie” was coined in 1926 by Jacobovici to describe the radiographical demonstration of

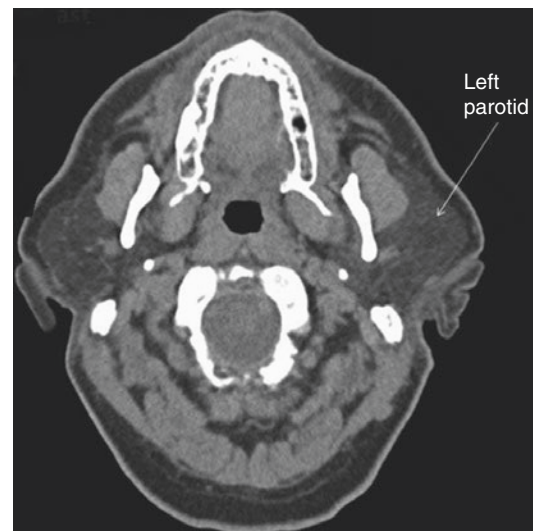

Fig. 13.2 CT scan of a patient with sialadenosis showing characteristic bilateral parotid gland enlargement with fatty infiltration. In this case, the left parotid appears to be slightly larger than the right and also enhancing more as well [26]

Fig. 13.3 Sialography on a patient with sialadenosis. This sialogram shows characteristic findings of a “leafless tree pattern” or of a thin, hairline salivary ductal system secondary to external compression seen in sialadenosis on sialography [26]



the salivary glands and ducts. Sialography is the modality of choice for visualizing ductal anatomy but has had a controversial role in sialadenosis [21]. In the early stages of sialadenosis, there may be little to no changes visualized on sialography due to the lesser degree of glandular swelling. Sialography in the latter stages of sialadenosis can be of important diagnostic utility because of a characteristic appearance of a thin, hairline salivary duct system, secondary to extrinsic pressure of the parenchymal swelling. In cases where the swelling is particularly pronounced, there may be no visualization of the proximal ductal system [24]. This classic sialography finding in sialadenosis is coined as a “leafless tree pattern” (Fig. 13.3) [3]. Contraindications to sialography are sensitivity to iodine-based compounds or presence of acute inflammation [24].

Pathologic

Pathologic analysis is not as frequently used for diagnosis of sialadenosis but in certain cases can be of important diagnostic utility because of its characteristic findings (Fig. 13.4). As described previously, Donath and Seifert were the first to do a morphometric analysis of sialadenosis, and

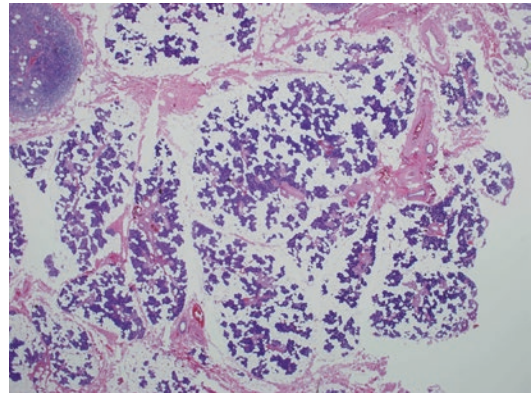


Fig. 13.4 Parotid specimen with sialadenosis. Patient with sialadenosis underwent a parotidectomy and his subsequent parotid specimen slide showing glandular structure with fatty infiltration [26]

they found enlargement of acinar cells when compared to controls, and histologically there was a granular pattern to the cytoplasm, secondary to the increased number of secretory granules [10]. This has been confirmed numerous times by others. FNA of glands with sialadenosis can show acinar enlargement up to 100µm, with average control gland sizes between 30 and 40 µm [2, 5]. It has been determined by one group that a mean acinar diameter of greater than 62 µm is diagnostic of sialadenosis [24]. Donath and Seifert also

showed that there was degeneration of myoepithelial cells in sialadenosis. One study showed a diffuse decrease in alpha-actin staining, a contractile myofilament in myoepithelial cells, when compared to controls, which confirms the degeneration of myoepithelial cells. Also, when glands with sialadenosis were stained for Ki67, a marker of proliferation, there were lower levels when compared to the already low levels of controls, showing that the glandular swelling arises from hypertrophy [4].

Management

Treatment of sialadenosis initially starts with identification and treatment of the underlying disease process causing the sialadenosis, although resolution of the swelling is variable [3, 15]. Concurrently, patients can undergo symptomatic treatment including heat management, massage, and sialogogues. Salivary substitutes can also be used in patients who have sialadenosis and xerostomia. Pilocarpine, which is a non-selective muscarinic agonist with a mild B-adrenergic, has been shown to increase salivary flow in patients with sialadenosis and xerostomia and in some cases resolved the swelling that was present [25].

Surgical management is held for refractory cases when the aesthetic appearance of the glandular swelling is unacceptable. Tympanic neurectomy involves denervating the parotid gland of parasympathetic innervation which causes subsequent glandular atrophy. Patients initially have good results with decreased glandular swelling, but in some cases swelling came back after 3 years, likely secondary to parasympathetic reinnervation [24]. Botulinum neurotoxin injection has been used in cases of parotid swelling/hypertrophy to cause atrophy to the gland, but this procedure has to be repeated periodically to obtain consistent results. Parotidectomy is deemed a last resort, especially in patients with bulimia or anorexia, due to their severe body image issues and the potential of morbidity and poor aesthetic results with the surgery [15].

References

1. Ascoli V, Albedi FM, De Blasiis R, Nardi F. Sialadenosis of the parotid gland: report of four cases diagnosed by fine-needle aspiration cytology. *Diagn Cytopathol*. 1993;9(2):151–5.
2. Batsakis JG. Pathology consultation. Sialadenosis. *Ann Otol Rhinol Laryngol*. 1988;97(1):94–5.
3. Coleman H, Altini M, Nayler S, Richards A. Sialadenosis: a presenting sign in bulimia. *Head Neck*. 1998;20(8):758–62.
4. Ihrler S, Rath C, Zengel P, Kirchner T, Harrison JD, Weiler C. Pathogenesis of sialadenosis: possible role of functionally deficient myoepithelial cells. *Oral Surg Oral Med Oral Pathol Oral Radiol Endod*. 2010;110(2):218–23.
5. Kastin B, Mandel L. Alcoholic sialosis. *N Y State Dent J*. 2000;66(6):22–4.
6. Kim D, Uy C, Mandel L. Sialosis of unknown origin. *N Y State Dent J*. 1998;64(7):38–40.
7. Mandel L, Baurmash H. Parotid enlargement due to alcoholism. *J Am Dent Assoc*. 1971;82(2):369–73.
8. Butt F. Chapter 18. Benign diseases of the salivary glands. In: Lalwani AK, editor. *CURRENT diagnosis & treatment in otolaryngology—head & neck surgery*. 3rd ed. New York: McGraw-Hill; 2012. <http://accessmedicine.mhmedical.com.proxy.lib.uiowa.edu/content.aspx?bookid=386&Sectionid=39944053>. Accessed 24 Feb 2016.
9. Dhillon N. Chapter 1. Anatomy. In: Lalwani AK, editor. *CURRENT diagnosis & treatment in otolaryngology—head & neck surgery*. 3rd ed. New York: McGraw-Hill; 2012. <http://accessmedicine.mhmedical.com.proxy.lib.uiowa.edu/content.aspx?bookid=386&Sectionid=39944032>. Accessed 24 Feb 2016.
10. Donath K, Seifert G. Ultrastructural studies of the parotid glands in sialadenosis. *Virchows Arch A Pathol Anat Histol*. 1975;365(2):119–35.
11. Merlo C, Bohl L, Carda C, Gómez de Ferraris ME, Carranza M. Parotid sialosis: morphometrical analysis of the glandular parenchyme and stroma among diabetic and alcoholic patients. *J Oral Pathol Med*. 2010;39(1):10–5. Epub 2009 Jul 19.
12. Mandic R, Teymoortash A, Kann PH, Werner JA. Sialadenosis of the major salivary glands in a patient with central diabetes insipidus—implications of aquaporin water channels in the pathomechanism of sialadenosis. *Exp Clin Endocrinol Diabetes*. 2005;113(4):205–7.
13. Teymoortash A, Wiegand S, Borkeloh M, et al. Variations in the expression and distribution pattern of AQP5 in acinar cells of patients with sialadenosis. *In Vivo*. 2012;26:951–6.
14. Lavender S. Vomiting and parotid enlargement. *Lancet*. 1969;1:426.
15. Mehler PS, Wallace JA. Sialadenosis in bulimia. A new treatment. *Arch Otolaryngol Head Neck Surg*. 1993;119(7):787–8.

16. Guggenheimer J, Close JM, Eghtesad B. Sialadenosis in patients with advanced liver disease. *Head Neck Pathol.* 2009;3(2):100–5. Epub 2009 Mar 26.
17. Scully C, Bagán JV, Eveson JW, Barnard N, Turner FM. Sialosis: 35 cases of persistent parotid swelling from two countries. *Br J Oral Maxillofac Surg.* 2008;46(6):468–72. Epub 2008 Mar 17.
18. Bozzato A, Burger P, Zenk J, Uter W, Iro H. Salivary gland biometry in female patients with eating disorders. *Eur Arch Otorhinolaryngol.* 2008;265(9):1095–102. Epub 2008 Feb 6.
19. Borsanyi SJ, Blanchard CL. Asymptomatic parotid swelling and isoproterenol. *Laryngoscope.* 1962;72:1777–83.
20. Mauz PS, Mörike K, Kaiserling E, Brosch S. Valproic acid-associated sialadenosis of the parotid and submandibular glands: diagnostic and therapeutic aspects. *Acta Otolaryngol.* 2005;125(4):386–91.
21. Morgan RF, Saunders JR Jr, Hirata RM, Jaques DA. A comparative analysis of the clinical, sialographic, and pathologic findings in parotid disease. *Am Surg.* 1985;51(11):664–7.
22. Gritzmann N, Rettenbacher T, Hollerweger A, Macheiner P, Hübner E. Sonography of the salivary glands. *Eur Radiol.* 2003;13(5):964–75. Epub 2002 Sep 5.
23. Whyte AM, Bowyer FM. Sialosis: diagnosis by computed tomography. *Br J Radiol.* 1987;60(712):400–1.
24. Pape SA, MacLeod RI, McLean NR, Soames JV. Sialadenosis of the salivary glands. *Br J Plast Surg.* 1995;48(6):419–22.
25. Aframian DJ, Helcer M, Livni D, Robinson SD, Markitzu A, Nadler C. Pilocarpine treatment in a mixed cohort of xerostomic patients. *Oral Dis.* 2007;13(1):88–92.
26. Hoffman H (editor). Iowa head and neck protocols. Sialosis or sialadenosis case example of surgical treatment. <https://medicine.uiowa.edu/iowaprotocols/sialosis-or-sialadenosis-case-example-surgical-treatment>. Accessed 29 July 2017.

Part IV

Management of Benign Salivary Masses

Robert L. Witt and Christopher Rassekh

Key Points

1. Extracapsular dissection (ECD) differs markedly from classic surgical approaches to the benign parotid neoplasm because initial facial nerve dissection is not performed.
2. Devastating adverse outcomes of permanent facial nerve dysfunction and recurrence preclude this procedure for the occasional and inexperienced parotid surgeon.
3. Low complication rates for ECD have been reported at high-volume centers.
4. The main advantage to ECD compared to traditional facial nerve dissection parotid procedures is the potential reduction in transient nerve injury, Frey's syndrome, great auricular nerve injury, and sialoceles.
5. Transoral robotic surgery (TORS) approach to the parapharyngeal space should include needle biopsy of the tumor to exclude malignancy and cross-sectional imaging to exclude extension across the stylomandibular tunnel.

6. The parapharyngeal space tumor approach should only be performed by surgeons who are comfortable with the transcervical approaches and who have extensive experience with other modules of TORS.

Introduction

Lower complication rates at selected high-volume parotid centers, performing extracapsular dissection (ECD) including transient facial nerve dysfunction, Frey's syndrome, sialoceles, and numbness compared to traditional parotidectomy, have led to debate regarding the amount of parotid parenchyma to resect around a parotid pleomorphic adenoma (PA). Extracapsular dissection (ECD) differs markedly from classic surgical approaches to the benign parotid neoplasm because initial facial nerve dissection is not performed. Recurrence and permanent facial nerve dysfunction with ECD are comparable to traditional parotidectomy when performed at high-volume centers by experienced surgeons. Devastating adverse outcomes of permanent facial nerve dysfunction and recurrence preclude this procedure for the occasional and inexperienced parotid surgeon.

Extracapsular dissection with facial nerve dissection (ECD-FND) for benign parotid tumors is an alternative gland-preserving approach. Excellent outcomes with ECD-FND results may be more

R.L. Witt, M.D., F.A.C.S. (✉)
Thomas Jefferson University, Philadelphia, PA, USA

University of Delaware, Newark, DE, USA

Head and Neck Multidisciplinary Clinic, Helen
F. Graham Cancer Center, Christiana Care,
4745 Ogletown-Stanton Rd, MAPH #1, Suite 112,
Newark, DE 19713, USA
e-mail: robertlwitt@gmail.com

C. Rassekh, M.D.
University of Pennsylvania, Philadelphia, PA, USA

readily reproducible outside of a few high-volume parotid practices because the facial nerve is dissected and the extracapsular plane for the tumor margin is defined and controlled.

Transoral robotic approaches for parapharyngeal tumors and submandibular tumors offer a minimally invasive alternative to transcervical approaches.

Part 1A: Extracapsular Dissection (ECD)

The main goals in parotid surgery are the removal of the tumor without tumor rupture, complete tumor removal, and avoidance of injury to the facial nerve. The necessary extent of surgical margin around a benign parotid tumor is actively debated particularly for pleomorphic adenoma (PA). As long-term low recurrence rates are now generally the norm for parotid PA, there is an emerging trend toward low-morbidity surgery.

Total parotidectomy (TP) involves the removal of all parotid tissue both medial and lateral to the facial nerve. Complete superficial parotidectomy (SP) removes all parotid tissue lateral to the facial nerve. Partial superficial parotidectomy (PSP) [1–3] initially dissects the trunk of the facial nerve with more limited dissection of the upper or lower branches (depending on the location of the tumor) together with a cuff of 1–2 cm of normal parotid parenchyma surrounding the neoplasm. ECD dissects around the tumor and in contrast to classical surgical approaches to the benign parotid neoplasm does not dissect the facial nerve. ECD involves a careful blunt dissection through the parotid tissue by way of a cruciate incision placed directly over the tumor (Fig. 14.1). The neoplasm is then removed with a 2–3 mm rim of normal parotid parenchyma surrounding the tumor (Fig. 14.2) [4, 5]. ECD can be considered for PA, other parotid adenomas, and Warthin's tumor, but not for malignant tumors. Enucleation, an abandoned procedure, was practiced in the first half of the twentieth century. With enucleation, the capsule of the tumor was incised and the contents removed leaving the capsule in situ.

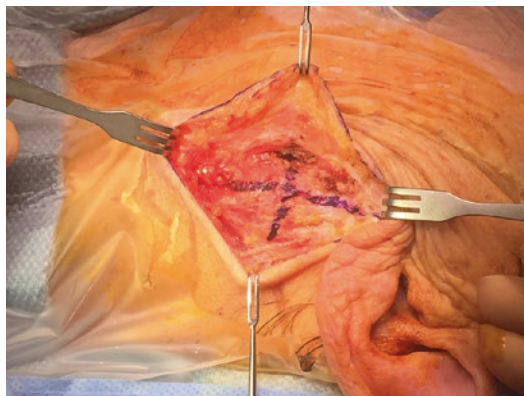


Fig. 14.1 ECD involves a careful blunt dissection through the parotid tissue by way of a cruciate incision placed directly over the tumor

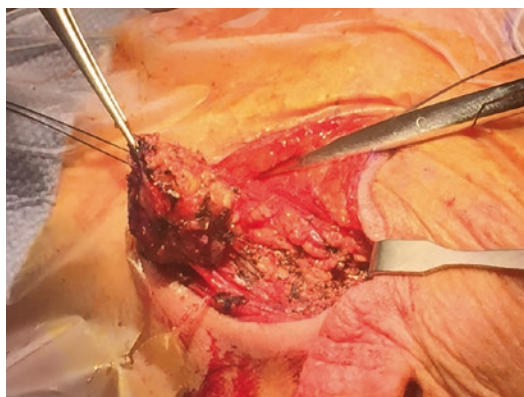


Fig. 14.2 The neoplasm with ECD is removed with a 2–3 mm rim of normal parotid parenchyma surrounding the tumor

Historical Perspective

Enucleation is an intracapsular dissection associated with 20–45% recurrence rates [6]. In the early twentieth century, as an effort to preserve the facial nerve, many cases included an incision through the skin directly over the lesion, enucleating (intracapsular dissection) the tumor contents [7]. McFarland and others [8, 9] reported high rates of recurrence with enucleation, as well as the benign histology of these tumors. Enucleating the tumor content and treating with radium seeds gained popularity as a result of these high recurrence rates [10].

An evolution in antegrade facial nerve dissection evolved [7, 11–14]. Patey and Thackray [15] in 1957 described the histological evaluation of PA and reported pseudopodia projecting through the capsule. It became axiomatic that these PA remnants would be left behind by close dissection around the tumor. SP and TP for PA became standard. Recurrence rates sharply declined.

Surgical technical advances developed including facial nerve monitoring, loop magnification, and instruments capable of providing fine control of hemostasis. Donovan and Conley and others [1, 16] noted parotidectomy with antegrade facial nerve dissection, including TP and SP, generally incorporates partial extracapsular dissection where the tumor abuts the facial nerve or superficial fascia. In an effort to reduce permanent and transient facial nerve paralysis, PSP with facial nerve dissection with a 1–2 cm margin of normal parotid parenchyma evolved [2, 3, 6]. Simultaneously ECD performed without facial nerve dissection in one center reported a 1.5% recurrence rate over 12 years and a 2% rate of facial nerve dysfunction [17]. Although SP and TP are practiced for PA, the two main contemporary operations today are PSP with antegrade facial nerve dissection and ECD without facial nerve dissection.

PA Clinical and Histological Characteristics

Eighty-five percent of PA present in the parotid gland and represent half of all parotid tumors, with the highest incidence in the fourth decade of life [18]. Eighty percent of the parotid parenchyma is lateral to the facial nerve; ninety percent of parotid PA arise in the superficial lobe, and 80% are located in the lower pole.

Parotid PAs are benign epithelial tumors with an incomplete fibrous capsule of varying thickness. Macroscopic protuberances give a lobulated appearance as the tumor grows. Incomplete pseudo-capsule and pseudopodia protruding outside the capsule have been identified as a factor for recurrence [19].

Tumors may be epithelial cell rich (cellular) or stromal rich (myxoid). Tumors are more highly cellular (the epithelial component predominates) in their early stages of development, and the amount of chondromyxoid stroma (the mesenchymal component) increases with the duration of the neoplasm [20]. Hypocellular tumors are easier to rupture inadvertently during surgery, and these tumors are also associated with higher rates of incomplete encapsulation [21, 22]. If the capsule is ruptured during surgery, the incidence of recurrence is 5–8% [1, 23].

An estimated 60–99% of parotid tumors lie on a branch of the facial nerve that is dissected off the tumor surface leaving a focal area of capsule exposed at surgery [1, 16, 24]. After SP or PSP, 25% of PAs are reported to have positive margins where there is focal absence of a capsule [1, 16]; however, the rate of recurrence for these procedures remains low (1–4%) [1].

Histological comparison between PSP and ECD for the amount of normal parotid parenchyma surrounding the total PA specimen after surgery demonstrates 80% versus 21%, respectively ($p < 0.05$) [25]. A smaller room for surgical error is implicit with ECD. Low rates of recurrence with long-term follow-up reported at high-volume centers (1.5–2%) [17, 26] have fueled the discussion on the extent of margin around parotid PA and the role of pseudopodia with modern surgical technique.

ECD Surgical Technique

The tumor for which ECD is suited is one that is well defined, mobile, and approximately 2 cm in diameter or greater and lies in the superficial and inferior aspect of the parotid gland. Minimally invasive parotid surgery including ECD should be preceded by fine needle aspiration cytology (FNAC) and imaging to rule out signs of malignancy including cervical adenopathy and irregular borders. A postoperative 5% risk of malignancy after ECD is reported in a series not using FNAC [27].

The skin incision and the flap size for ECD may be adapted to the size and location of the

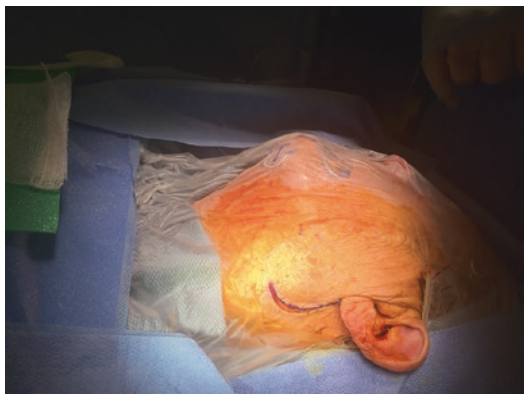

Fig. 14.3 The skin incision and the flap size for ECD may be adapted to the size and location of the tumor and is often more conservative with ECD

tumor and is often more conservative with ECD (Fig. 14.3). The sternocleidomastoid muscle and the great auricular nerve together with the capsule of the parotid gland are exposed. Before the parotid parenchymal fascia is opened, the tumor is palpated to ensure that it is mobile and that there is no suggestion of infiltration and tethering that would suggest malignancy. A cruciate incision is marked over the surface of the parotid mass extending approximately 1 cm peripheral to the tumor margin (Fig. 14.1). Tissue planes appear which direct the line of dissection [28]. The tumor is gradually separated from the underlying parenchyma. A small 1–2 mm rim of glandular tissue is left on the tumor (Fig. 14.2). Facial nerve branches can appear in the surgical field as the glandular tissue is parted. The tumor itself can be rolled from side to side as the dissection proceeds. The tumor can be retracted by finger pressure. Retractors may be applied to the parotid tissue but not the tumor in order to prevent rupture. After the tumor has been released from the surrounding tissue, the edges of the cruciate incision are re-approximated and sutured together [29]. Draining the wound is often not necessary. The use of pressure dressings in the form of modified mastoid dressings is recommended by some but not all surgeons [25]. In appropriate patients and tumors, the ECD operation can be undertaken as a day-case procedure.

Imaging, FNAC, Frozen Section, and Neuromonitoring

Imaging beyond ultrasound is optional for tumors with benign characteristics. Lobulations by ultrasound are predictive of PA. FNAC is optional for SP. FNAC plays an important role in minimal margin surgery including PSP and ECD, helping to exclude malignancy. False negatives (benign FNAC and histopathologic malignancy) range from 4 to 7% [30, 31]. Minimal margin ECD procedures selected because of benign FNAC will encounter an occasional frozen section pathology of malignancy. ECD should be converted to a facial nerve dissection procedure with wide surgical resection in circumstances where the frozen section dictates or clinical signs of malignancy are present including poorly defined surgical planes, enlarged cervical lymph nodes, and tumor infiltration of the facial nerve branches. The surgeon performing ECD must be trained in facial nerve dissection techniques.

Although facial nerve monitoring with traditional nerve dissecting techniques has not improved the functional outcome of the nerve after surgery in all series [32, 33], facial nerve monitoring should be strongly considered for ECD where the facial nerve is not dissected, observed, and controlled.

Risk of Recurrence of PA with ECD

In most series, parotidectomy with facial nerve dissection results in recurrence rates of 0–4% [1]. Recurrences generally occur in the first 10 years, with a mean interval to the first recurrence of 7 years [34]. Recurrent PA is almost always multinodular [35, 36]. Imaging studies (MRI) coupled with clinical examination are more accurate than clinical examination alone. Historically, the chief cause for tumor recurrence was enucleation [1, 34, 37] due to retention of capsular components. Currently the main reason for recurrence is enucleation with incomplete tumor removal often associated with tumor rupture and spillage [38]. Incomplete pseudocapsule and pseudopodia are linked to recurrence.

The overall rate of recurrence during SP is 2.6% in a review of 23 publications with 2366 total patients. When the capsule is ruptured using SP with facial nerve dissection, the rate of recurrence significantly increases to 5% ($p < 0.05$) [1, 22]. Tumor spillage does not lead to inevitable tumor recurrence but increases the risk. A series from a high-volume center reports a greater but statistically nonsignificant difference in capsule rupture comparing ECD and SP (3.4% vs. 1.8% [$p = 0.1$]) [39]. ECD should be converted to parotidectomy with nerve dissection in the event of tumor spillage in an effort to achieve negative margins.

The rate of recurrence for ECD compared to complete SP has been studied in a meta-analysis that demonstrated a similar rate for both these techniques [1]. In a series of 76 patients with PA treated with ECD, followed for a mean of 7.4 years, no recurrences were observed [26]. In a series of 176 cases followed for 52 months, the rate of recurrence comparing ECD and SP was 4.5% vs. 3.6% [39], and in another series of 156 patients followed for a mean of 3 years and 8 months, there were no cases of recurrence [40]. Against this pattern there are worrisome reports of increased rate of recurrence of up to 8% with ECD [41, 42].

Recurrence rates are difficult to gauge as the average time to first recurrence is 7 years; thus patients are lost to follow-up. Furthermore, recurrence of PA is not followed by tumor registries. Although the risk of recurrence with ECD in select high-volume parotid centers does not appear to be greater than traditional nerve dissection techniques, further long-term prospective studies are required to confirm this.

The potential devastation of recurrent disease cannot be underestimated. The facial nerve with associated scar tissue in recurrent PA is more intimately adherent to the tumor, and consequently facial nerve injury occurs in up to 40% of cases [43]. The rate of facial nerve paralysis increases with each revision procedure [44]. One third of patients with recurrent tumors do not achieve tumor-free status [45]. In contrast, since ECD does not formally dissect the nerve, the tissue planes surrounding the nerve are easier to

identify and dissect in the event that subsequent parotidectomy is required due to recurrence.

Permanent Facial Nerve Dysfunction with ECD

Permanent facial nerve dysfunction is reported in 0–4% of cases following facial nerve dissection procedures [46–48]. A meta-analysis showed twice the rate of permanent facial nerve dysfunction with ECD compared with SP [1]. The incidence of injury following ECD is 2% in high-volume centers [29, 40], supporting ECD performed by experienced high-volume surgeons is not necessarily associated with higher risk of permanent facial nerve dysfunction compared to SP. The risk of facial nerve paralysis is of particular concern in tumors not in the parotid tail, but in a more superiorly located pre-tragal tumor, specifically where the delicate orbital branch of the facial nerve is peripherally located in close approximation to PA.

Temporary Facial Nerve Dysfunction

Meta-analysis summary effect for transient facial nerve dysfunction shows a 2.3 times higher incidence with TP compared with SP and 2.0 times higher incidence with SP compared to ECD. The incidence of transient dysfunction averaged 30% for TP, 25% for SP, 18% for PSP, and 11% for ECD [1]. Improved results with ECD compared to SP are reported in high-volume centers with transient facial nerve paralysis rates of 3–6% [29, 40] compared to 16–64% using PSP [1, 2]. ECD offers an advantage over PSP as the facial nerve is not dissected and so the risk of stretch injury and inadvertent pressure effects may be reduced.

Frey's Syndrome

Frey's syndrome is reported in a questionnaire survey as the most common disturbing sequel to patients more than 5 year's post-parotid

surgery for benign disease [49]. Meta-analysis summary effect for Frey's syndrome has been reported as up to ten times more common with SP compared to ECD presumably because less parotid is dissected with ECD and the damaged tissue is sealed into position once the parotid fascia is re-approximated through closing the cruciate incision [50]. The incidence of Frey's syndrome averaged 47% with TP, 17% with SP, 10% with PSP, and 3% with ECD [1]. ECD offers a potential advantage in terms of Frey's syndrome compared to nerve dissection techniques.

Sensory Deficit in the Great Auricular Nerve

Preservation of the posterior branch of the great auricular nerve can reduce, but not eliminate, sensory deficits in up to half of patients [3] undergoing parotidectomy with facial nerve dissection. ECD has been reported to have a rate of sensory deficit of 5–10% [29, 40]. Most ECD procedures do not transect any branches of the great auricular nerve, whereas all antegrade facial nerve dissection procedures including PSP will transect at least the anterior branches. Reduction of sensory deficit is an advantage of ECD but this advantage is dependent on the position of the tumor.

Sialocele

Sialocele and fistula have been reported in 4–5% of cases [29, 51] in a series using ECD with a fistula rate of 2% [27]. Sialocele has been reported as high as 39% in meticulously recorded PSP cases although resolution without treatment occurred in all cases within 4 weeks [52]. Reduction in sialocele is an advantage of ECD. If sialocele does occur, the saliva can be aspirated at intervals and a pressure dressing applied. Alternatively, if left untreated, sialocele will generally resolve without treatment within 1 month [52].

Part 1B. Extracapsular Dissection with Facial Nerve Dissection (ECD-FND)

ECD-FND, as recently reported [53], uses standard surgical landmarks to identify and to antegrade dissect the facial nerve trunk at the onset of the procedure. With ECD-FND, the branches of the facial nerve are dissected up to the anterior extracapsular margin of the tumor, and then the tumor is dissected with a thin 1–2 mm layer of parenchyma and fascia around it (Fig. 14.4). PSP in contrast initially exposes the main facial nerve trunk and peripheral branches of the facial nerve that are dissected anterior as well as posterior to the tumor. There is a 1–2 cm cuff of normal parotid parenchyma around the tumor except where it abuts the facial nerve.

ECD-FND for benign parotid tumors resulted in significantly lower rates of transient facial nerve dysfunction (4% vs. 17%, $p < 0.05$) and sialocele (8% vs. 39%, $p < 0.05$) compared to PSP with facial nerve dissection, without increasing the risk of permanent facial nerve dysfunction or recurrence at 4.5 years of follow-up [53] (Table 14.1). Longer follow-up is necessary to more accurately define the recurrence rate of this technique.

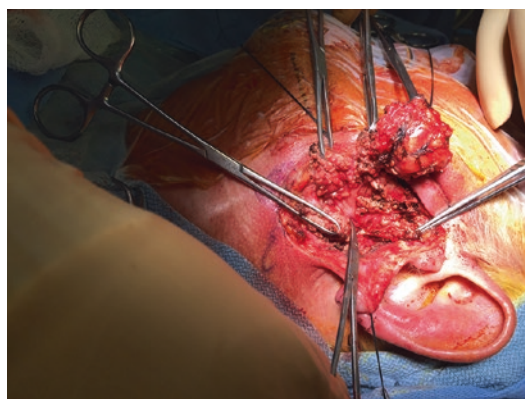


Fig. 14.4 ECD-FND: The branches of the facial nerve are dissected up to the anterior extracapsular margin of the tumor, and then the tumor is dissected with a thin 1–2 mm layer of parenchyma and fascia around it

Table 14.1 ECD or ECD-FND versus SP or PSP

ECD vs. SP or PSP	ECD-FND vs. SP or PSP
Does not dissect the facial nerve	Does dissect the facial nerve
Does not optimize the control of the facial nerve and its relationship to the tumor unlike SP or PSP	Does optimize the control of the facial nerve and its relationship to the tumor like SP or PSP
Less transient facial nerve dysfunction	Less transient facial nerve dysfunction
Less Frey’s syndrome	Less Frey’s syndrome
Less sialocele	Less sialocele
Less numbness	Equivalent numbness
Often no drain placed	Drain usually placed

ECD-FND has a minimal amount of normal parotid parenchyma around the tumor similar to ECD; however, ECD-FND comes with the advantage of dissecting the facial nerve initially with control of the facial nerve and its relationship to the tumor. When employing ECD-FND (versus ECD), the parotid surgeon may reduce risk of permanent facial nerve dysfunction, most importantly for pretragal tumors where the orbital branch of the facial nerve can be injured because the facial nerve is not dissected with ECD. Tumor rupture with ECD can potentially be reduced with ECD-FND because the extracapsular plane of the PA is defined in its relationship to the facial nerve.

Furthermore, without regularly dissecting the facial nerve with ECD, a given surgeon may not maintain this skill set. ECD reduces the exposure for teaching residents to learn facial nerve dissection. Excellent outcomes with ECD-FND results may be more readily reproducible outside of a few high-volume parotid practices where ECD is practiced successfully.

ECD compared to ECD-FND has several advantages. ECD may result in lower rates of peri-auricular numbness. A drain is often not required with ECD. ECD is a lower-magnitude procedure with an easier recovery in the first several post-op days. Also revision surgery after ECD for recurrent parotid PA would be potentially less risky for facial nerve paralysis as the facial nerve is not dissected.

Part 2. Transoral Robotic Surgery (TORS): Parapharyngeal and Paralingual Space Approaches

The prestyloid compartment of the parapharyngeal space can be accessed transorally for parotid gland-preserving removal of salivary gland tumors involving the minor salivary glands and other selected lesions. This approach can be modified slightly to enter the paralingual space for the removal of the submandibular gland or for access to the submandibular gland hilum to remove pathology of this area while preserving the gland.

Prestyloid Parapharyngeal Space Tumors

Traditionally, salivary gland tumors of the parapharyngeal space have been removed using a transcervical or transmandibular approach. The majority of these tumors do not actually involve the parotid, but arise from minor salivary gland rests. Some tumors are in contact with the parotid or involve it minimally on the very deep aspect. Nevertheless, some experienced surgeons advocate the transcervical approach be combined with a parotidectomy because of the proximity of the deep lobe of the parotid gland [54]. The transcervical approach has been described as requiring anterior mobilization/translocation of the submandibular gland, and for simplicity [55], some surgeons remove the submandibular gland as well which is completely normal in these cases. Even for tumors that are not of salivary gland origin that arise in the prestyloid space, these same approaches may apply and result in sacrifice of normal salivary gland tissue. Further, transcervical and parotidectomy approaches put the facial nerve, particularly the lower division of the nerve, at risk in addition to the lingual and hypoglossal nerves. Finally, these approaches have been occasionally associated with first bite syndrome [56], which may be very troublesome to the patient in addition to requiring an external scar. Alternatives include retroauricular/hairline approaches and transoral approaches.

The transoral approach to the parapharyngeal space is not new [57]. In fact, it was popular prior to advanced imaging. With advanced imaging, this approach lost popularity due to the concern for vascular injury [58]. Prestyloid parapharyngeal space tumors are located anteromedial to the carotid artery. Nevertheless, the lack of visualization and control produces anxiety. The TORS approach to the parapharyngeal space involves a modification of the radical tonsillectomy procedure expanding on the advantages of this approach [59–61]. Specifically, utilizing robotic surgery for transoral surgery improves the manual dexterity and visualization of the tumor and the critical anatomy (Figs. 14.5 and 14.6). These advantages allow potentially safer transoral

excision of parapharyngeal space tumors, particularly prestyloid tumors, most of which are benign salivary gland tumors. The original description showed this was feasible [60] however a subsequent report demonstrated that tumor rupture and mucosal dehiscence were potential risks [68]. The approach allows for optimal utilization of a bedside assistant. Nuances in technique have been described elsewhere [61], but the wristed instrumentation and high-definition images allow division of the medial pterygoid muscle to improve access; however, as is done in the transcervical approach, the final delivery of the tumor is done with blunt dissection but under better visualization. Critical to the success of this approach is meticulous dissection to avoid rupture of the

Fig. 14.5 TORS PPS approach. The tumor has been exposed and has a bluish color. The assistant is important for retraction to achieve excellent visualization

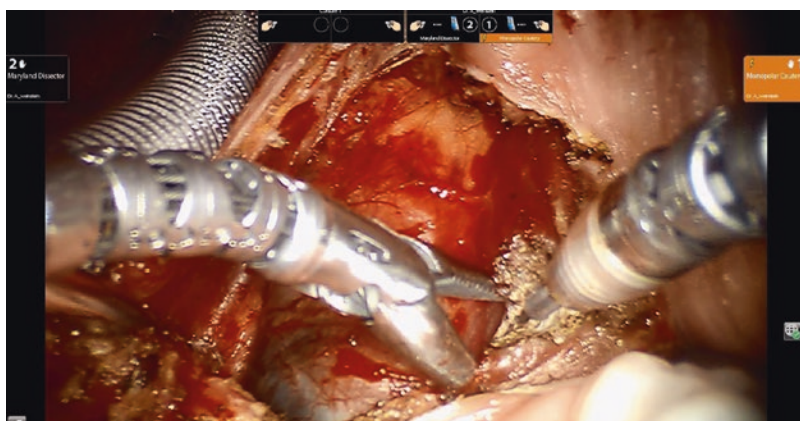
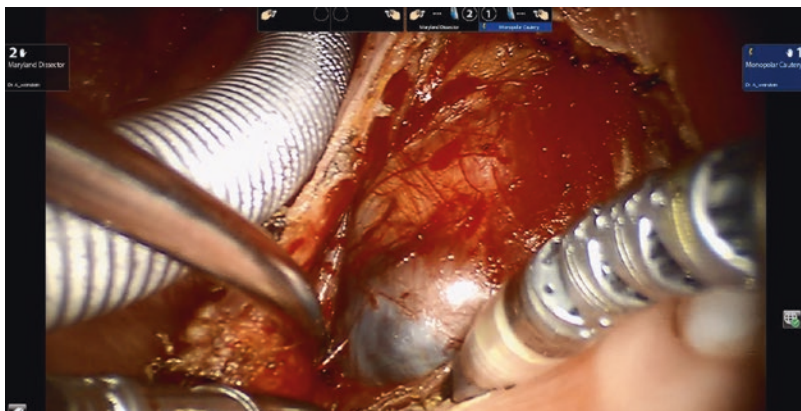


Fig. 14.6 TORS PPS approach. Partial division of the right medial pterygoid muscle is performed by carefully elevating the muscle off the tumor using the Maryland Dissector in the left instrument arm and the spatula tip

monopolar cautery in the right instrument arm. Intermittently, the robotic arms are often removed and finger dissection is used. No sharp dissection is done on the deep aspect of the tumor or without direct visualization

delicate capsule and precise closure/pharyngoplasty to avoid pharyngeal dehiscence. Caution in the approach is required to avoid injury to the lingual nerve near the inferior aspect of the incision.

Prior to performing a transoral (robotic) surgery-assisted removal of tumors in the parapharyngeal space, we advise a needle biopsy of the tumor to exclude malignancy and careful cross-sectional imaging to exclude extension across the stylomandibular tunnel (Fig. 14.7), both of which should be considered contraindications to the procedure. In addition, cross-sectional imaging is critical to evaluate the relationship of the tumor to the carotid artery and the skull base. The tumor should be antero-medial to the carotid and should not involve the skull base. This approach should only be undertaken by surgeons who have extensive experience with other approaches to the prestyloid space. Consent should be obtained for the transcervical approaches in the event that the tumor cannot be removed transorally.

A combined open (transcervical) and transoral approach has been described as an alternative to mandibulotomy for tumors that are deemed too large to remove via a transoral approach alone [62]; this introduces a risk of pharyngocutaneous fistula which would not be a concern with either the transoral or transcervical approach alone. However, with careful closure, it can be used

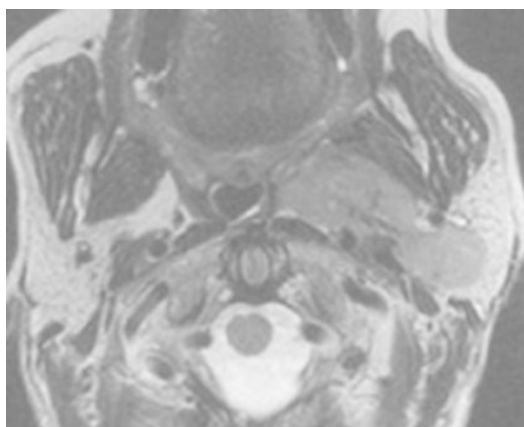


Fig. 14.7 Parapharyngeal tumors that demonstrate passage through the stylomandibular tunnel (as shown on axial CT scan) are not candidates for the transoral robotic approach due to an increased risk to the facial nerve

safely and may minimize the risk of tumor rupture or inadequate visualization of vital neural and vascular structures.

Submandibular Gland Diseases

Submandibular gland excision via a transcervical incision has been the most commonly described treatment for tumors and major inflammatory diseases of the gland, including stones that cannot be removed using traditional approaches. Numerous alternative approaches including retroauricular and transoral strategies have been described [63]. Transoral approaches have not become popular due to the difficulty of the operation prompting interest in using robotic surgery for this minimally invasive way to remove the gland [64]. We have applied TORS for these combined approaches to the paralingual space and submandibular gland [65]. While transoral removal of the submandibular gland has been popularized in Korea where external scars on the neck are very much considered below the standard of care, it has not caught on in the United States and elsewhere because it is a very difficult operation [66]. This originally began as an extension of the TORS parapharyngeal space approach for tumors as in the above section. We have successfully removed the submandibular gland for small and large benign tumors using this modified parapharyngeal space approach. The approach is low parapharyngeal space skeletonizing the lingual nerve and utilizing the duct as a handle for careful dissection. This allows a minimally invasive approach to the gland, avoiding an external scar and virtually eliminating the risk to the mandibular branch of the facial nerve. All the principles of TORS are used to make a challenging operation more safe and feasible. The TORS approach allows greatly enhanced magnified and high-definition visualization of the lingual nerve, facial vessels, and other submandibular structures and facilitates employing the assistant and allows multiple angles of approach to the paralingual space. While removal of hilar stones has been feasible [67], the TORS SMG excision concept also potentially allows a

failed transoral approach for obstructive disease of the gland to be managed without an external approach. Again, careful closure of the incision is imperative to avoid complications. As with the parapharyngeal space resection, the closure is done with 3-0 vicryl horizontal mattress sutures following meticulous hemostasis.

Conclusion

In most traditional facial nerve dissection parotid procedures, the capsule of the parotid tumor is partially exposed when dissecting the tumor off the facial nerve. Parotidectomy with facial nerve dissection optimizes the control of the facial nerve and its relationship to the tumor. Several long-term studies demonstrate that ECD in high-volume centers thus far have not increased the incidence of recurrence compared to SP (0–2%). Permanent injury to one or more branches of the facial nerve is similar with these two techniques (2%) in high-volume centers. The main advantage to ECD compared to traditional facial nerve dissection parotid procedures is the potential reduction in transient nerve injury. Frey's syndrome, great auricular nerve injury, and sialoceles are potentially minimized with ECD. ECD-FND like other traditional facial nerve dissection parotid procedures optimizes the control of the facial nerve and its relationship to the tumor and potentially reduces transient facial nerve dysfunction, Frey's syndrome, and sialoceles without increasing permanent facial nerve paralysis and thus far recurrence. Longer-term studies for ECD and ECD-FND are necessary.

Transoral approaches to the parapharyngeal space and submandibular gland are feasible and can be performed successfully using TORS at experienced centers. The parapharyngeal space tumor approach should only be performed by surgeons who are comfortable with the transcervical approaches and who have extensive experience with other modules of TORS, particularly radical tonsillectomy and lateral oropharyngectomy. Systematic review shows that even in experienced hands, technical nuances and careful application of the TORS approach to the PPS will be impor-

tant as we continue to define the limitations and long-term results of this approach [67].

References

1. Witt R. The significance of the margin in parotid surgery for pleomorphic adenoma. *Laryngoscope*. 2002;112:2141–54.
2. Witt RL. Facial nerve function after partial superficial parotidectomy: an 11-year review (1987–1997). *Otolaryngol Head Neck Surg*. 1999;121:210–3.
3. Witt R. Minimally invasive surgery for parotid pleomorphic adenoma. *Ear Nose Throat J*. 2005;84(5):308–11.
4. Gleave EN. An alternative to superficial parotidectomy: extracapsular dissection. In: Norman JED, McGurk M, editors. *Salivary glands*. St. Louis: Mosby-Wolfe; 1995. p. 165–72.
5. Gleave EN, Whittaker JS, Nicholson A. Salivary tumours—experience over thirty years. *Clin Otolaryngol*. 1979;4:247–57.
6. Yamashita T, Tomoda K, Kumazawa T. The usefulness of partial parotidectomy for benign parotid gland tumors. *Acta Otolaryngol Suppl*. 1993;500:113–6.
7. Sistrunk WE. Tumor of the parotid gland. *Surg Clin N Am*. 1921;1:1515–21.
8. McFarland J. Three hundred mixed tumors of the salivary glands of which 69 recurred. *Surg Gynaecol Obstet*. 1936;63:457–68.
9. Stein I, Geschickter CF. Tumors of the parotid gland. *Arch Surg*. 1934;28:482–526.
10. Smiddy FG. Treatment of mixed parotid tumours. *Br Med J*. 1956;1:322–5.
11. Carwardine T. Excision of the parotid gland with preservation of the facial nerve: its possibility. *Lancet*. 1907;170(4387):892.
12. Adson AW, Ott WP. Preservation of the facial nerve in the radical treatment of parotid tumours. *Arch Surg*. 1923;6:739–46.
13. Bailey H. Parotidectomy: indications and results. *Br Med J*. 1947;1:404–7.
14. Martin H. The operative removal of tumors of the parotid salivary gland. *Surgery*. 1952;31:670–82.
15. Patey DH, Thackray AC. The treatment of parotid tumors in the light of a pathological study of parotidectomy material. *Br Med J*. 1957;45:477–87.
16. Donovan DT, Conley JJ. Capsular significance in parotid tumor surgery: reality and myths of lateral lobectomy. *Laryngoscope*. 1984;94:324–9.
17. McGurk M, Renehan A, Gleave EN, Hancock BD. Clinical significance of the tumour capsule in the treatment of parotid pleomorphic adenomas. *Br J Surg*. 1996;83:1747–9.
18. Everson JW, Cawson R. Salivary gland tumours: a review of 2410 cases with particular reference to histological types, site, age and sex distribution. *J Pathol*. 1985;146:51–8.

19. Henriksson G, Westrin KM, Carlsoo B, Silfversward C. Recurrent primary pleomorphic adenomas of salivary gland origin: intrasurgical rupture, histopathologic features, and pseudopodia. *Cancer*. 1998;82:617–20.
20. Seifert G, Langrock I, Donath K. Pathologic and morphologic subclassification of salivary pleomorphic adenoma. *HNO*. 1976;24:415–26.
21. Naeim F, Forsberg MI, Waisman J, Coulson WF. Mixed tumors of the salivary glands: growth pattern and recurrence. *Arch Pathol Lab Med*. 1976;100:271–5.
22. Stennert E, Guntinas-Lichius O, Klussmann J, Arnold G. Histopathology of pleomorphic adenoma in the parotid gland: a prospective unselected series of 100 cases. *Laryngoscope*. 2001;111:2195–200.
23. Natvig K, Sobery R. Relationship of intraoperative rupture of pleomorphic adenomas to recurrence: an 11–25 year follow-up study. *Head Neck*. 1994;16(3):213–7.
24. Lam KH, Wei WI, Ho HC, Ho CM. Whole organ sectioning of mixed parotid tumors. *Am J Surg*. 1990;160:377–81.
25. Witt R, Iacocca M. Comparing capsule exposure using extracapsular dissection with partial superficial parotidectomy for pleomorphic adenoma. *Am J Otolaryngol*. 2012;33(5):581–4.
26. Iro H, Zenk J, Koch M, Klintworth N. Follow-up of parotid pleomorphic adenomas treated by ECD. *Head Neck*. 2013;35:788–93.
27. Renehan AG, Gleave EN, Slevin NJ, McGurk M. Clinico-pathological and treatment—related factors influencing survival in parotid cancer. *Br J Cancer*. 1999;8018:1296–300.
28. Witt RL, Iro H, McGurk M. The role of extracapsular dissection for benign parotid tumors, current otorhinolaryngology reports. In: Lane AP, Gillespie MB, editors. *Salivary gland disorders*, vol. 2. New York, NY: Springer; 2014. p. 55–63.
29. Klintworth N, Zenk J, Koch M, et al. Postoperative complications after extracapsular dissection of benign parotid lesions with particular reference to facial nerve function. *Laryngoscope*. 2010;120:484–90.
30. Que Hee CG, Perry CF. Fine-needle aspiration cytology of parotid tumours: is it useful? *ANZ J Surg*. 2001;71:345–8.
31. Zbären P, Schär C, Hotz MA, et al. Value of fine-needle aspiration cytology of parotid gland masses. *Laryngoscope*. 2001;111:1989–92.
32. Witt R. Facial nerve monitoring in parotid surgery. Is it the standard of care? *Otolaryngol Head Neck Surg*. 1998;119:468–70.
33. Eisele D, Wang SJ, Orloff LA. Electrophysiologic facial nerve monitoring during parotidectomy. *Head Neck*. 2010;32(3):399–405.
34. Carew JF, Spiro RH, Singh B, Shah JP. Treatment of recurrent pleomorphic adenomas of the parotid gland. *Otolaryngol Head Neck Surg*. 1999;121:539–42.
35. Stennert E, Wittekindt C, Klussmann J, Arnold G, Guntinas-Lichius O. Recurrent pleomorphic adenoma of the parotid gland: a prospective histopathological and immunohistochemical study. *Laryngoscope*. 2004;114:158–63.
36. Glas A, Vermey A, Hooema H, et al. Surgical treatment of recurrent pleomorphic adenoma of the parotid gland: a clinical analysis of 52 patients. *Head Neck*. 2001;23:311–6.
37. Niparko J, Beauchamp M, Krause C, Baker S, Work W. Surgical treatment of recurrent pleomorphic adenoma of the parotid gland. *Arch Otolaryngol Head Neck Surg*. 1986;112:1180–4.
38. Witt RL, Eisele D, Morton R, et al. Etiology and management of recurrent parotid pleomorphic adenoma. *Laryngoscope*. 2015;125(4):888–93.
39. Orabona GD, Bonavolonta P, Iaconetta G, Forte R, Califano L. Surgical management of benign tumors of the parotid: ECD versus superficial parotidectomy—our experience in 232 cases. *J Oral Maxillofac Surg*. 2013;71:410–3.
40. George KS, McGurk M. ECD-minimal resection for benign parotid tumors. *Br J Oral Maxillofac Surg*. 2011;49:451–4.
41. Piekarski J, Nejc D, Szymczak W, et al. Results of ECD of pleomorphic adenoma of parotid gland. *J Oral Maxillofac Surg*. 2004;62:1198–202.
42. Piekarski J. Audience discussion. Treatment of benign parotid tumours. In: Iro H, Klintworth N, Zenk J, editors. *Controversies in the management of salivary gland disease*. Oxford: Oxford University Press; 2012.
43. Hanna D, Dickison W, Richardson G, et al. Management of recurrent salivary gland tumors. *Am J Surg*. 1976;132:453–8.
44. Renehan A, Gleave EN, McGurk M. An analysis of the treatment of 114 patients with recurrent pleomorphic adenomas of the parotid gland. *Am J Surg*. 1996;172:710–4.
45. Myssiorek D, Ruah C, Hybels R. Recurrent pleomorphic adenomas of the parotid gland. *Head Neck*. 1990;12:332–6.
46. Mehle ME, Kraus DH, Wood BG, et al. Facial nerve morbidity following parotid surgery for benign disease: the Cleveland Clinic Foundation experience. *Laryngoscope*. 1993;103:386–8.
47. Laccourreye H, Laccourreye O, Cauchois R, et al. Total conservative parotidectomy for primary benign pleomorphic adenoma of the parotid gland: a 25-year experience with 229 patients. *Laryngoscope*. 1994;104:1487–94.
48. Debets JM, Munting JD. Parotidectomy for parotid tumours: 19-year experience from the Netherlands. *Br J Surg*. 1992;79:1159–61.
49. Baek C, Chung MK, Jeong H. Questionnaire evaluation of sequelae over 5 years after parotidectomy for benign diseases. *J Plast Reconstr Aesthet Surg*. 2009;62:633–8.
50. Witt R, Pribitkin E. How can Frey's syndrome be prevented or treated following parotid surgery. *Laryngoscope*. 2013;123:1573–4.

51. Smith S, Komisar A. Limited parotidectomy: the role of ECD in parotid gland neoplasm. *Laryngoscope*. 2007;117:1163–7.
52. Witt R. The incidence and management of sialoceles post-parotidectomy. *Otolaryngol Head Neck Surg*. 2009;140:871–4.
53. Witt R. Extracapsular dissection with facial nerve dissection for benign parotid tumors. *Otolaryngol Head Neck Surg*. 2016;154(3):572–4. doi:[10.1177/0194599815627818](https://doi.org/10.1177/0194599815627818).
54. Hughes KV 3rd, Olsen KD, McCaffrey TV. Parapharyngeal space neoplasms. *Head Neck*. 1995;17:124–30.
55. Myers EN, Johnson JT. Management of tumors of the parapharyngeal space. In: Myers EN, editor. *Operative otolaryngology head and neck surgery*, vol. 1. 2nd ed. Philadelphia: Saunders Elsevier; 2008. p. 661.
56. Linkov G, Morris LG, Shah JP, et al. First bite syndrome: incidence, risk factors, treatment, and outcomes. *Laryngoscope*. 2012;122:1773–8.
57. New GB. Mixed tumors of the throat, mouth and face. *J Am Med Assoc*. 1920;75:732–73.
58. Work WP. Tumors of the parapharyngeal space. *Trans Pac Coast Otoophthalmol Soc Annu Meet*. 1964;45:79–82.
59. Weinstein GS, O'Malley BW Jr. Transoral robotic surgery: radical tonsillectomy. *Arch Otolaryngol Head Neck Surg*. 2007;133:1220–6.
60. O'Malley BW Jr, Quon H, Leonhardt FD, et al. Transoral robotic surgery for parapharyngeal space tumors. *ORL J Otorhinolaryngol Relat Spec*. 2010;72:332–6.
61. Rassekh CH, Weinstein GS, Loevner LA, O'Malley BW Jr. Transoral robotic surgery for prestyloid parapharyngeal space masses. *Oper Tech Otolaryngol Head Neck Surg*. 2013;24:99–105.
62. Betka J, Chovanec M, Klozar J, Taudy M, Plzak J, Kodetova D, Lisy J. Transoral and combined transoral-transcervical approach in surgery of parapharyngeal tumors. *Eur Arch Otorhinolaryngol*. 2010;267:765–72.
63. Beahm DD, Peleaz L, Nuss DW, Schaitkin B, Sedimayer JC, Rivera-Serrano CM, Zanation AM, Walvekar RR. Surgical approaches to the submandibular gland: a review of the literature. *Int J Surg*. 2009;7:503–9.
64. Prosser JD, Bush CM, Solares CA, Brown JJ. Transoral robotic submandibular gland removal. *J Robot Surg*. 2013;7:87–90.
65. Rassekh CH, Marchal F. Transoral robotic surgery with sialendoscopy for submandibular stones and transoral submandibular gland excision. In: Marchal F, editor. *Sialendoscopy, the hands on book*. Chapter 89. Imprimerie Gutenberg; 2015. p. 212–213.
66. Hong KH, Yang YS. Surgical results of intraroal removal of the submandibular gland. *Otolaryngol Head Neck Surg*. 2008;139:530–4.
67. Razavi C, Pascheles C, Samara G, Marzouk M. Robot-assisted sialolithotomy with sialendoscopy for the management of large submandibular gland stones. *Laryngoscope*. 2016;126:345–51.
68. Chan JY, Tsang RK, Eisele DW, Richmon JD. Transoral robotic surgery of the parapharyngeal space: a case series and systematic review. *Head Neck*. 2015;37:293–8.

Mark F. Marzouk and Susannah Orzell

Key Points

1. Nonneoplastic salivary masses are uncommon. Clinical suspicion, imaging, and sometimes biopsy are keys to reach the correct diagnosis.
2. Most of these conditions can be successfully managed with a gland-sparing approach. Gland excision may be indicated in cases of failure of minimally invasive approaches.
3. Benign lymphoepithelial cysts can be successfully treated with antiretroviral therapy, alcohol sclerotherapy, or radiation. Parotidectomy may be considered when other less invasive options have been exhausted.
4. Management of vascular malformations is far from simple. Multidisciplinary approach and particular expertise are required to manage such conditions.

Introduction

Nonneoplastic masses of the salivary glands comprise a disease category that can be described as swellings which, although mimic tumors, are differentiated by their lack of aberrant growth.

M.F. Marzouk, M.D., F.A.C.S. (✉)
S. Orzell, M.D., M.P.H.
Department of Otolaryngology and Communication
Sciences, SUNY Upstate Medical University,
Syracuse, NY, USA
e-mail: marzouma@upstate.edu

These masses in the salivary gland include, but are not limited to, cystic lesions, mucocoeles, first branchial cleft anomalies, and vascular malformations. Nonneoplastic salivary swelling can include pneumocoeles, intraglandular lymphadenopathy, granulomatous lesions, and masseter hypertrophy. Inflammatory and obstructive pathologies are discussed elsewhere, and we will focus our attention here on pathologies that can mimic neoplastic entities in presentation. In addition, we will also emphasize gland-preserving approaches to treatment.

Differential Diagnosis

True cysts of the parotid gland account for 2–5% of all parotid lesions with the parotid gland being the most common location for salivary cysts [1]. In the pediatric population, Bentz et al. found 86.7% of salivary gland solid or cystic tumors to be vascular proliferations, 59.2% of which were hemangiomas and 27.5% lymphangiomas [2]. In general many of the masses and swellings described present as painless enlargement of the major salivary gland that with progression may result in cosmetic deformity and/or compressive symptoms. With infection and more significant growth, discomfort may prompt a patient to seek medical attention.

Given the rather broad differential diagnosis of salivary gland disease processes as a whole,

imaging modalities and FNA cytology have become more frequently utilized over the last few decades, but thorough history and physical examination remain paramount. Office-based ultrasonography is gaining popularity among otolaryngologists for evaluation of head and neck masses including salivary lesions. It is a noninvasive, radiation-sparing, cost-effective, and easily accessible imaging modality of significant yield. In addition, image-guided FNA can be performed concurrently in the office. Doppler ultrasonography can provide an additional advantage to demonstrate the presence or absence of blood flow. For further imaging details about the relation of the lesion to surrounding structures, computed tomography (CT) and magnetic resonance (MR) imaging are used for pretreatment evaluation of lesion extension. Intravenous contrast is helpful for further definition of cystic structures and evaluating vascularity of various masses. CT and MRI are also useful to differentiate intraglandular from extraglandular masses and deeper structures. Table 15.1 summarizes different MRI findings for various nonneoplastic salivary lesions. Table 15.2 summarizes FNA cytology characteristics for cystic lesions of major salivary glands [3, 4].

Table 15.1 MRI findings for various nonneoplastic salivary gland lesions

Branchial cleft (work type I or type II (lower parotid))	<ul style="list-style-type: none">• Low T1 and high T2 signal and appear as single fluid-filled masses• No thickening, or enhancement, or rim unless infected or recent infection
Cystic hygroma	<ul style="list-style-type: none">• High T2 and low T1 signals are observed• High T1 signal when blood clots are present• Fluid-fluid levels can be observed
Ranula	<ul style="list-style-type: none">• Homogeneous high T2 and low T1 signals. CT has fluid attenuation and the cyst wall is appreciated, may or may not enhance depending on infection
Hemangioma	<ul style="list-style-type: none">• Intermediate T1 and high T2, presence of flow voids; large calcifications “phleboliths” can be present

Table 15.2 FNA findings for various nonneoplastic salivary lesions [5] lymphangioma

Lesion	Cytology
Lymphangioma	<ul style="list-style-type: none">• Aspirate smears are usually hypocellular• Diff-Quik and Papanicolaou-stained smears and cytopsin preparations show occasional red blood cells and mature-appearing lymphocytes• Rare clusters of benign-appearing salivary gland epithelium
Warthin’s tumor	<ul style="list-style-type: none">• Oncocytic epithelium
Branchial cleft cysts	<ul style="list-style-type: none">• Squamous epithelial cells
Chronic sialadenitis	<ul style="list-style-type: none">• Reactive salivary gland epithelium and squamous metaplasia
Lymphoepithelial lesions	<ul style="list-style-type: none">• Polymorphous lymphoid population
Cystic low-grade mucoepidermoid carcinoma	<ul style="list-style-type: none">• Acellular mucoid material and rare atypical epithelial cells
Pleomorphic adenoma	<ul style="list-style-type: none">• Stromal-myoepithelial-epithelial components

Benign Lymphoepithelial Cysts (BLEC)

This disease entity is common in both adults and children who are HIV positive. It can be the earliest presenting sign of the disease. It was first described in 1895 by Hildebradt and its HIV link was described in 1985 by Ryan et al. [6] Lymphoepithelial cysts can also affect HIV negative patients who suffer from Sjogren’s syndrome, myoepithelial sialadenitis, or Mikulicz’s disease [7].

The exact pathogenesis remains unclear, but theories described include mechanical obstruction of the duct by lymphoid hyperplasia and cystic enlargement of the intraparotid lymph nodes after trapping glandular epithelium [7]. Male to female incidence is 1:1, and the disease presents as a soft, painless, usually bilateral swelling of the parotid gland. Ultrasonography shows multiple hypoechoic lesions with variable sizes and smooth margins. Internal septations sometimes can be seen. CT and MRI show the cystic lesions inside the gland and very frequently detect cervical lymphadenopathy that is

HIV related. Diagnosis is often confirmed via fine needle aspiration (FNA) which has a characteristic mix of glandular epithelium, foamy macrophages, and lymphocytes. FNA is also helpful to rule out malignancy or malignant transformation (which is rare) in cases of rapid change in size or character.

Management. The main complaint of a BLEC patient is usually the cosmetic appearance of the face. Bearing in mind the natural history of this disease, we will emphasize the gland preserving approach to this condition.

Antiretroviral therapy (ART) is highly effective in eradicating cysts without further intervention. For patients who are not compliant with ART, gland-preserving options include observation, with repeat biopsy if concerning changes ensue, sclerotherapy, and radiation therapy. Other modalities for treatment are enucleation, superficial parotidectomy, and total parotidectomy. Sclerotherapy using multiple agents, e.g. (doxycycline, alcohol, morrhuate sodium), offers a minimally invasive and effective treatment modality with minimal side effects. Meyer et al. published results regarding 95% ethanol as a sclerosing agent injected with a butterfly needle. Cyst contents are aspirated, and the lumen is then reinjected with ethanol to 20% of its original volume. This is then reaspirated after 10 min until no cysts are palpable. This method was attempted on 11 patients of whom none were receiving ART. There were no reported complications, three patients required a second injection with ethanol, and 10 of 11 patients were pleased with cosmetic outcome [8]. Repeated aspiration is largely unsuccessful due to rapid recurrence. Radiation therapy was shown to achieve complete resolution in 55% of patients using 24 Gy and only 35% using 18 Gy. However, radiation treatment carries a risk of painful xerostomia and secondary malignancy and may limit the treatment options in cases of malignancy arising within the radiation field in the future [9]. Enucleation is largely discouraged due to high rate of recurrence. Superficial parotidectomy carries traditional surgical risks of facial nerve injury, Frey's syndrome, etc. and potential to transmit the disease to the surgical team.

Dermoid Cyst

Dermoid cysts are benign cysts that rarely occur in the parotid gland. It has been described in a case report as occurring within the submandibular gland recently [10]. Histologically, dermoid cysts are derived from ectoderm and mesoderm. Seven percent of all dermoid cysts occur in the head and neck. Nonspecific radiologic findings make this entity difficult to correctly diagnose preoperatively, and often a diagnosis is made from surgical pathology. Pathologically, the cyst is lined by stratified squamous epithelium with variable amounts of pilosebaceous units and sweat glands supported by a fibrous connective tissue wall. They usually present as an asymptomatic, mobile, non-tender mass with or without fluctuance, unless it creates cosmetic deformity or compressive effects. Rare cases of malignant transformation in the oral cavity have been reported at a transformation rate of 5%. Epidermoid cysts of the parotid gland have been reported, nearly half of which occur after otologic surgery. Treatment of these masses entails wide local excision [11, 12].

Hydatid Cyst

Parotid hydatid cysts are exceedingly rare and restricted to endemic geographic areas (S. America, Middle East, Mediterranean countries, Australia). It is a parasitic infection caused by a larval-stage cestode tapeworm called *Echinococcus granulosus*. Humans are incidental intermediates in the biologic cycle in the *Taenia* echinococcosis through ingesting food contaminated with eggs from a definitive host. The most vulnerable organs are the liver and lungs. When cysts are present in the parotid, it usually presents as a soft swelling of the parotid region that is slowly growing. There have been cases reported with associated facial palsy. Given the wide differential diagnosis of parotid cysts, one has to consider the geographic region when suspecting this diagnosis [13]. Submandibular hydatid cysts have been reported in the salivary duct and can resemble the appearance of a stone

(calcification within a cyst, which is evidence of necrosis of the parasite). Sialendoscopy can clearly rule out the presence of stone by visualization of a patent duct.

Serological confirmation utilizes enzyme linked immunoabsorbant assays (ELISA), agglutination, skin prick tests, and immunoelectrophoresis, of which immunoelectrophoresis is the most specific. Although these tests are frequently performed when echinococcosis is suspected and certainly can be used to aid diagnosis, their utility is greater in monitoring treatment and recovery from disease. Diagnosis is confirmed on histopathology or cytology [13]. Once this diagnosis is made, the physician should look for cysts in other places when found in head and neck (liver and lungs). Cysts have also been found in the maxillary sinus and pterygopalatine fossae [14].

CT shows a well-defined, cystic, hypodense lesion. The most pathognomonic finding on imaging is the presence of daughter cysts within a larger cyst. Hydatid sands, which are accumulations of protoscolices and brood capsules, are also consistent of echinococcosis. These sands settle in the most dependent parts of the cyst, and it can be advantageous to use ultrasound to demonstrate the sands “falling.”

Management. Medical treatment with benzimidazole group of drugs is necessary in disseminated cases and poor surgical candidates. It is also recommended for the perioperative period. Surgical excision entails careful, complete excision and is curative. Incidental rupture during surgery may cause a life-threatening anaphylactic reaction. Thorough wound irrigation should also be performed with formalin or peroxide and hypochlorite after excision to inactivate protoscolices and thereby decrease the chance of seeding to surrounding tissue during excision. Blood count and transaminases must be checked routinely after surgery. Sclerotherapy has also been used in the treatment of hydatid cysts. The PAIR (percutaneous aspiration, infusion of scolical agents (95% ethanol or hypertonic saline), reaspiration) procedure has been a promising alternative to excision that preserves the remainder of the salivary gland. In a 2011 Cochrane review, PAIR of hepatic hydatid cysts had similar cure

rates but significantly fewer complications compared to surgery [15].

Mucocoele/Ranula

Mucocoele means “mucous-filled cyst.” This is a condition that commonly occurs in the minor salivary glands (73%) as a result of trauma. A mucocoele of the floor of the mouth is called a ranula. Ranulas are a rare, acquired, or congenital form of mucocoele that originates from the sublingual gland (ducts of Rivinus). Mucocoeles can also originate from the submandibular gland [16]. They commonly present in the second decade of life and have a slight female gender predilection [17]. Ranula is classified as oral, i.e., limited to the floor of the mouth, or cervical (plunging) when it herniates through a dehiscence in the mylohyoid muscle into the neck space. The most common location for mucocoele is in the lower lip.

The pathophysiology of mucocoeles is believed to start with ductal obstruction, ductal stenosis, or trauma. The resulting mucous extravasation into surrounding tissues invokes an inflammatory response and macrophage accumulation. Eventually that inflammation seals the leak, resulting in a lack of epithelial lining of the pseudocysts [18]. On the other hand, mucous retention cysts are true cysts that are lined with epithelium and caused by ductal obstruction or inflammation.

Ranulas present as painless, bluish soft masses at the floor of mouth. Very large ranulas may affect speech and swallowing and may result in airway obstruction. Mucocoeles of minor salivary glands enlarge over short periods of time, may fluctuate in size, and may eventually rupture into the oral cavity. Mucocoeles are more common in patients who bite their lips.

Ultrasonographic pictures of ranula reveal a hypoechoic mass that may have echoes within them and may sometimes be septated. CT and MRI characteristically show a cystic lesion with a “tail sign” which delineates the communication between the sublingual and submandibular space where the lesion herniates through the posterior

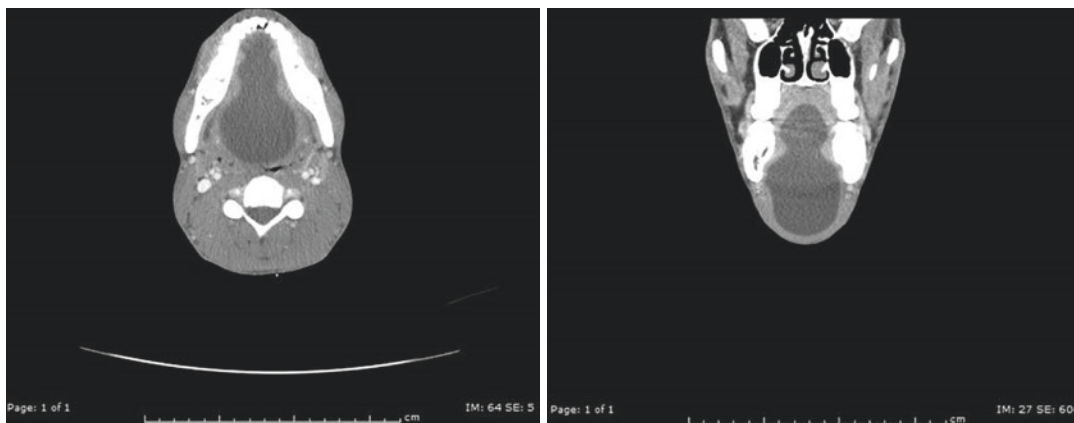


Fig. 15.1 Axial and coronal CT view of a patient with plunging ranula

edge of the mylohyoid (Fig. 15.1). FNA reveals high amylase levels.

Management. Observation is reasonable as spontaneous resolution of ranula and mucocoele has been reported [19]. Topical steroid (clobetasol 0.05%) has been suggested for superficial mucocoeles with gamma linoleic acid; however the lesions tend to recur when medication is stopped [20, 21].

Sclerotherapy using OK-432 for plunging ranula was shown to achieve complete resolution in 33.3% of patients, 19% showed near total shrinkage, 19% with marked shrinkage, 14.3% with partial shrinkage, and 14.3% with recurrence after resolution. Fever and swelling were associated with treatment [22]. Woo et al. reported 50% recurrence rate of ranula after sclerotherapy with OK-432 [23].

Surgical treatments include marsupialization, ranula excision, and sublingual gland excision (Fig. 15.2). Amaral et al. reported on 11 patients with mucocoele and ranula that were treated with micro-marsupialization followed by indium-gallium-arsenide-phosphorous (InGaAsP) diode laser, at 100 mW. There was no evidence of recurrence at 11 months, but significant reduction in post-procedure pain was noted [24]. Some authors reported the use of carbon dioxide laser with low recurrence rate [25]. Complete surgical excision is recommended for superficial mucocoeles. Sigismund et al. studied the recurrence rates after different

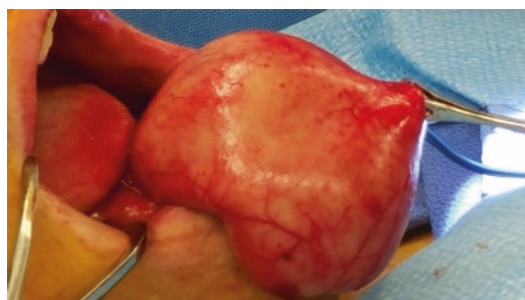

Fig. 15.2 Transoral excision of a large plunging ranula from a 22-year-old male

surgical excision techniques on 65 subjects with ranula. Recurrence rates were 3.6% after sublingual gland excision, 9.1% with partial sublingual gland excision, 13% with marsupialization, and 36.7% with ranula excision [26].

First Branchial Cleft Anomalies

First branchial cleft anomalies are congenital lesions that arise as a result of persistence of vestigial remnants of a branchial cleft or cyst. They usually present during infancy and childhood, but later presentations are not uncommon. They result from incomplete closure of ectodermal portions of the first branchial cleft. Work [27] further characterized first branchial cleft anomalies as either type I or type II. Type I branchial cleft anomalies are ectoderm derived

and thus are a squamous-lined tract or cyst without mesodermal cartilage or adnexal elements. Type II branchial cleft anomalies are ectoderm and mesoderm derived and therefore are comprised of cartilage and adnexal elements and have a squamous lining. Both types of first cleft cysts tend to occur inferior to the ear and superior to the neck, and both may involve the parotid gland. Their course varies slightly in that type I cysts are located anteromedial to the external auditory canal and lateral to the facial nerve, whereas type II cysts have a variable intimate relationships to the facial nerve and may occur along a tract from the anterior superior sternocleidomastoid border to concha or external auditory canal. Studies have demonstrated that type II cysts most often occur superficial to the facial nerve; however, it is important to consider that this relationship will be atypical in a significant number of patients [28]. First branchial cleft anomalies comprise <8% of all branchial cleft defects and can present as a cyst with no skin or mucosal communication, a sinus, or a fistula. The latter is the most common.

Patients commonly present with recurrent pre- or postauricular swelling with or without discharge from the EAC. Recurrence after history of incision and drainage in the same location should raise suspicion. The presence of a cyst projecting toward the bony-cartilaginous junction of EAC is a characteristic feature. Branchial cleft cysts can turn into abscess usually after URI due to lymphoid tissue located below the epithelium. Spontaneous rupture of abscess may occur resulting in a draining sinus to the skin [29]. Branchial cleft cysts may also occur as part of a syndrome, such as Treacher Collins, Goldenhar, and branchio-oto-renal syndromes. Additionally there may be a family history of branchial cleft anomalies [30].

These lesions appear as fluid-filled cystic structure on ultrasound with a well-defined, smooth rim. CT and MRI confirm the presence of a homogeneous fluid-filled cavity and can be used to characterize the relationship of the cyst to surrounding structures as well as determine if any communications exist. MRI also typically demonstrates low T1 and high T2 signals. CT fistulography is also

potentially helpful in determining the exact course of the anomaly, if applicable [31].

Management. Complete surgical excision is the only treatment for branchial cleft fistulae. Meticulous removal of the entire tract is a key to minimizing the chances of recurrence which varies between 3% in primary cases to 20% in revision cases [32].

Type I first branchial cleft anomalies usually need simple excision without facial nerve or parotid dissection. However, surgical treatment of type II anomalies depends on the nature of the intimate association of the lesion with the facial nerve and parotid gland. These anomalies often require superficial parotidectomy with facial nerve dissection and preservation [33].

Sclerotherapy with OK-432 has had promising results in small case series. Despite the reported response rate of 58%, the remaining subjects were able to undergo traditional surgical excision without difficulty, indicating that this therapy may be a good initial treatment option that will not affect surgical treatment if needed. Reported side effects of sclerosing therapy were mild and included fever and local pain [34].

Vascular Malformations

Nearly half of all vascular malformations occur in the head and neck region. The parotid gland harbors 85.1% of salivary gland vascular malformations. Reported incidence of parotid vascular anomalies is somewhere between 0.5 and 1.5% of all parotid tumors with lesions being more common in females than males [35, 36]. Vascular malformations are classified into capillary, venous, lymphatic, arteriovenous malformations, and mixed malformations. As opposed to hemangiomas, these malformations are present at birth (but might not be detected) and do not proliferate or regress. Rapid expansion can be seen after infection, trauma, and around puberty [37]. The mechanism of expansion is through hypertrophy rather than hyperplasia. Overall management strategy should involve a multidisciplinary team approach for the best outcome. Most parotid tumors present as painless masses within the

gland. Few present with facial deformity [2]. Occasionally, pain or skin changes can be present. Enlargement of a facial lesion upon clinching the teeth or tilting the neck toward the side of the lesion is known as the “turkey wattle sign” [38]. This sign is characteristic of a vascular malformation or hemangioma [39]. FNA of these lesions is discouraged, given their vascularity [40]. Imaging presentation, natural history, and management are specific to the malformation subtype; we will discuss them individually.

Lymphatic Malformations

Lymphatic malformations (LMs) are benign congenital malformation of the lymphatic system. They can develop throughout the body, but have a special predilection to the head and neck region, particularly the posterior triangle. LMs are multiloculated and can range in size between 1 and 20 cm. They usually involve surrounding tissues and rarely are limited to a salivary gland. LMs have equal sex distribution. Very few adult onset cases were reported in the parotid. LMs usually present as a painless mass that is soft and compressible. During infections which classically follow URI, the lesion becomes erythematous and enlarged. LM can infiltrate and absorb surrounding bone (Gorham-Stout syndrome) [5].

Involved cystic spaces may communicate with each other, and the spaces may have thick or thin walls. Often, they can mimic lipomas or branchial cleft cysts. The fluid in LM is usually watery, serous, clear, or straw colored. Microscopically, LMs are characterized by a cyst lined with a flattened endothelial layer with a fibrous cyst wall that can contain lymphoid aggregates. US shows septated hypoechoic lesions which can have infection or hemorrhage. Regression is extremely unusual. Based on its response to sclerotherapy, lymphatic malformations can be classified as macrocystic, microcystic, or mixed. Macrocystic lesions are most responsive to OK-432 sclerotherapy. Imaging findings have been described in Table 15.1. Figures 15.3, 15.4, and 15.5 show MRI images of vascular malformations.

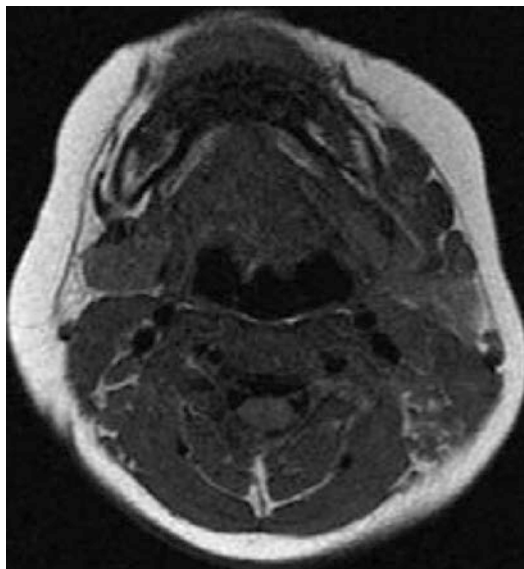


Fig. 15.3 Axial T1 non-contrast MRI image of left parotid lymphatic malformation

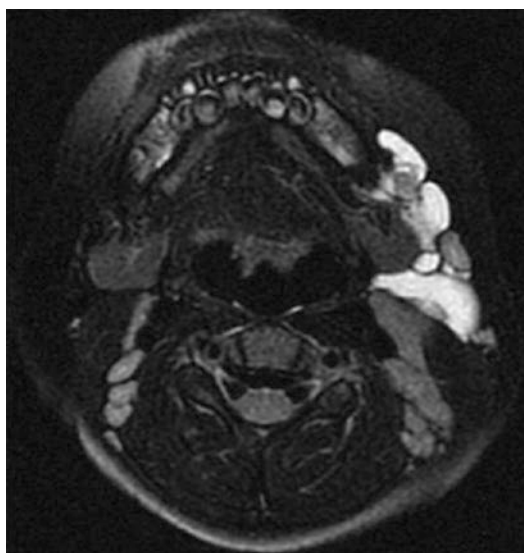
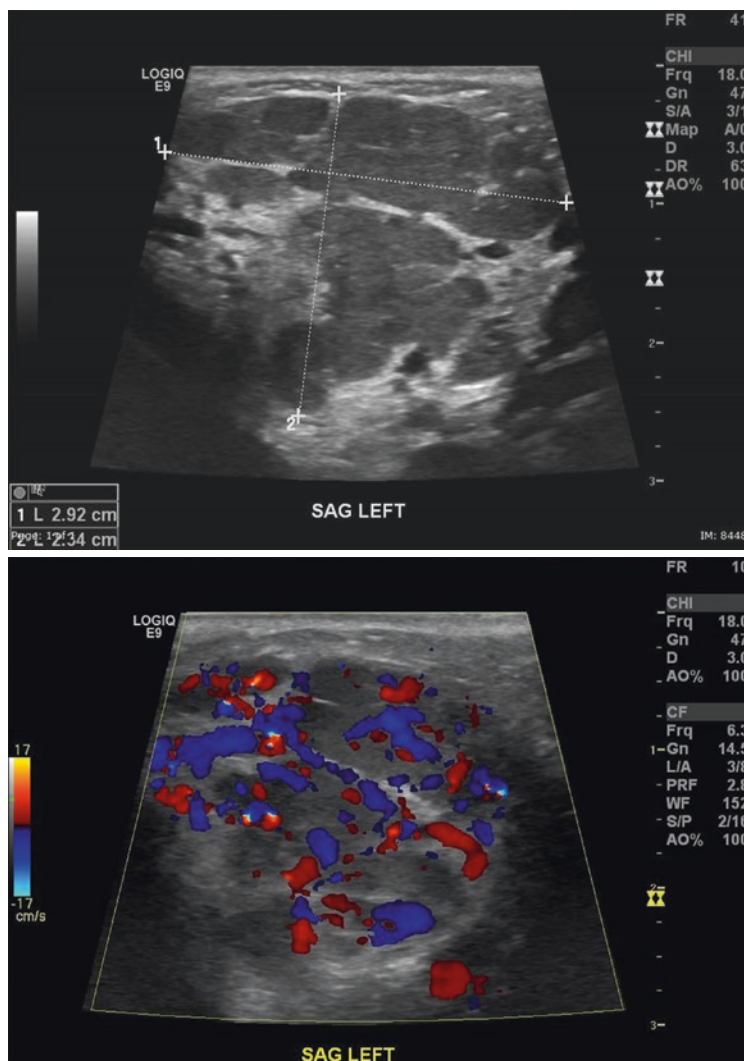


Fig. 15.4 Axial T2 contrast MRI image of left parotid lymphatic malformation

Management. Surgical resection is the treatment of choice, but can be difficult due to diffuse infiltration of surrounding tissue [41]. The recurrence rate is 10–15% within 1 year of excision [42]. Surgical options include enucleation, superficial parotidectomy, and total parotidectomy. Complications of surgical intervention include

Fig. 15.5 US image of a left parotid hemangioma. Color Doppler highlights the vascularity of the lesion



facial nerve injury, seroma, hematoma, wound infection, Frey's syndrome, recurrence, great auricular nerve injury, and sialocele.

Sclerotherapy can be effective for macrocystic lesions. Sclerosing agents include bleomycin, OK-432, triamcinolone, ethanol, and fibrin sealant. OK-432 is lyophilized incubation mixture of group A streptococcus of human origin. Its mechanism of action is via initiating a local inflammatory response and scar formation within the lesion thus obliterating the cysts. Adverse reactions are usually minor (low-grade fever, vomiting, skin discoloration, failure). It can be an adjunct to surgery. Radiotherapy has largely fallen out of favor due to the risk of malignant transformation [34].

Venous Malformation

Venous malformation is the most common form of vascular malformations. They are formed of dilated veins and believed to be due to congenital disruption of normal vein development and absent vasomotor autonomic control. This leads to progressive venous dilatation and enlargement of the lesion.

Diagnosis is based on clinical presentation, exam, and imaging. VM can present with pain, which can be chronic due to venous stasis, local intravascular coagulation (LIC), and thrombosis or acute with sudden expansion of the lesion in

cases of acute thrombosis. Characteristically, VMs expand significantly during the Valsalva maneuver or placing the affected site below the level of the heart. Bluish hue of the skin can be observed in large VMs, and phleboliths may be felt by palpation of the lesion [43]. Phleboliths and thrombus formation can occur as a result of changes in flow dynamics within a lesion. On imaging phleboliths mimic stones as these are calcified in appearance and radiopaque on X-ray and CT. Differentiation is important given treatment for these entities are vastly different (Table 15.3) [44].

Management. Observation is a reasonable option for asymptomatic lesions. If the lesion is rapidly enlarging or causing pain, treatment options include Nd-YAG laser which can be used as a single modality treatment for superficial lesions or as an adjunct modality prior to surgery. Interstitial laser therapy can be used for deep venous malformations that are not good candidates for surgery or sclerotherapy. This technique involves introducing a laser fiber through a 14-gauge needle. Pulse mode, settings 20–30 W with 1–1.5 s pulse duration or 10–15 W for 10 s. The laser fiber should be kept at 0.5 cm away from important neurovascular structures. Direction of the fiber can be guided by the transillumination of the fiber light or US guidance. Informed consent should entail explaining the risk of nerve injury with the patient [45].

With regard to surgical management, small lesions (2–4 cm) can be cured by wide local excision. For large lesions that put the facial

nerve at risk, surgery with preoperative sclerotherapy provides the best option. Such difficult surgery requires special surgical expertise. Sclerotherapy alone for such lesions has more risk for nerve injury than surgery by an experienced surgeon. Pre-op sclerotherapy can significantly minimize blood loss. Both Nd-YAG laser and sclerotherapy can be used intraoperatively as well [44].

Percutaneous sclerotherapy with ethanol has shown promising results of VM [46]. Commonly ethanol or sodium tetradecyl sulfate is suitable for lesions that need a significantly morbid access (deep parotid lobe or masseter muscle lesions) for surgical excision. Localized pain and swelling as a result of thrombosis are to be expected. IV hydration is important to minimize the risk of hemoglobinuria. Risks include nerve injury, skin ulcers, muscle stiffness, and deep venous thrombosis. Medical therapy in the form of low molecular weight heparin or aspirin 81 mg can be used to improve pain and swelling from thrombosis or LIC [42].

Arteriovenous and Mixed Malformations

AV malformations are acquired lesions with a feeding artery, dilated capillary bed (nidus), and draining veins [37]. The presentation is similar to other vascular malformation. Bruit can be auscultated over the lesion. Complete surgical excision of the nidus, preferably early, is the ultimate way to cure the lesion. Embolization can be helpful if

Table 15.3 List of differences between phleboliths and sialoliths

	Phleboliths	Sialoliths
Clinically	The appearance of dilated veins is more consistent with a vascular malformation	Hx of recurrent swelling of the salivary gland especially postprandial
Location	More likely to occur within the parotid gland	Usually more common in Wharton’s duct
X-ray	Circular opacities with laminated morphology which can have a radiolucent or radiopaque center	Uniformly opaque
CT image	Multiple round punctate calcified densities and hypodensities within the gland	Stones are usually single
Sialography	(Extraluminal) outside the ductal system with swelling related to venous congestion	(Intraluminal) obstructive in nature to salivary flow
Diagnostic	MRI may be able to distinguish the large vessels of vascular malformation and US Doppler can demonstrate increased blood flow	Diagnostic sialoendoscopy can reveal a stone vs. phlebolith by directly examining the gland ductal system

the preoperative setting to minimize blood loss. Anything left after surgery will usually result in recurrence [46].

Mixed malformations are composed of different vascular components. The most common type is veno-lymphatic. The presentation is similar to all vascular malformations, and the treatment is determined by the vascular components present. This typically involves surgical excision or by laser therapy [46].

Masseter Hypertrophy

Benign masseter muscle hypertrophy is uncommon. The exact etiology is unclear, but a number of factors have been blamed for it including emotional stress, chronic bruxism, masseteric hyperfunction, minor trauma, and medication induced (e.g., clenbuterol and anabolic steroids). Localized scleroderma, facial hemiatrophy, and genetic predisposition have also been associated with it [47, 48]. The usual presentation is soft swelling near the angle of the mandible which can be cosmetically disfiguring. Computed tomographic (CT) scan, magnetic resonance imaging (MRI) scan, or both are considered the gold standard in confirming a clinical suspicion. Other diagnostic testing includes morphometric analysis, ultrasound measurement, electromyographic measurement, and muscle biopsy (Fig. 15.6).

Management. Multiple options are available with varying degrees of success. They range from simple pharmacotherapy to more invasive surgical reduction. Injection of botulinum toxin type A into the masseter muscle is generally considered a highly successful, less invasive modality and has been advocated for cosmetic sculpting of the lower face with good patient satisfaction [49, 50], despite the lack of high-level evidence [51]. Pharmacotherapy includes anxiolytics, muscle relaxants, and antidepressants. Dental restorations and occlusal adjustments aim to correct premature contacts and malocclusions and prevent para-functional habits with orthotic appliances. Radiofrequency volumetric reduction can be utilized in the management as well (Fig. 15.7). Surgical options

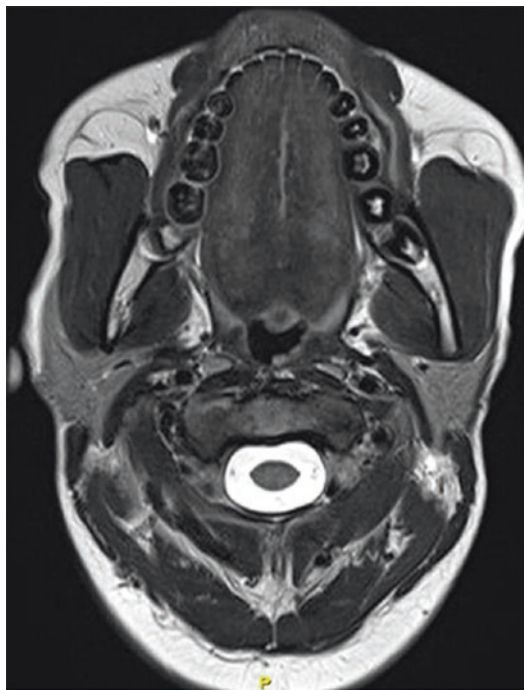


Fig. 15.6 T2-weighted MRI showing bilateral masseter hypertrophy

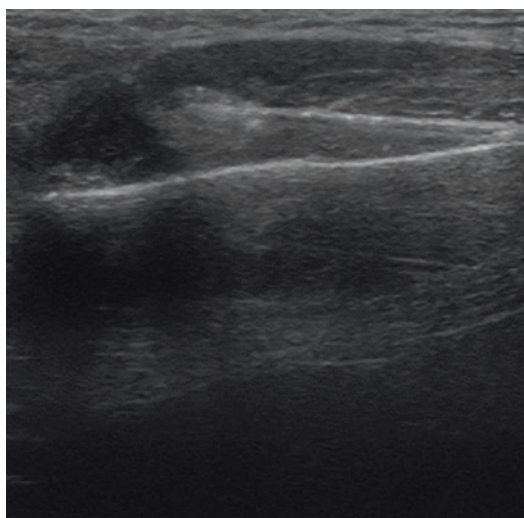


Fig. 15.7 Ultrasound image of masseter RFA. The top line is the RFA probe and the lower line delineates the mandible

include intraoral and extraoral surgical reduction of masseter size, removal of mandibular angle, neurectomy of the masseteric nerve, and resection of the buccal fat pad.

Pneumoparotid

Pneumoparotid is a term that describes bilateral, occasionally, unilateral enlargement of the parotid gland due to air retention within the gland. Its etiology is related to insufflation with pressure. It is seen with woodwind and brass instrument players due to increased air pressure sustained within the oral cavity during instrument playing. The weakness of buccinator muscle may be a predisposing factor. It also has been reported with sleep apnea devices [52]. Rarely, it can cause rupture in the glandular structure resulting in subcutaneous emphysema. It can be confused with acute parotitis or parotid abscess. Diagnosis is typically clinical but US can be helpful to rule out other entities. CT can detect subQ emphysema in surrounding facial structures and rule out abscess.

Management. It is a self-limiting condition. Management is usually conservative, i.e., observation, warm compresses, NSAIDs for pain, and avoidance of trigger. Cheek compressors can be helpful in preventing recurrences. Various surgical treatments have been suggested for chronic and recurrent pneumoparotid: transposition of the parotid duct to the oropharynx or extirpation of the gland. Parotidectomy is indicated only after multiple episodes of infection as this may indicate an irreversible symptomatic problem [53].

Necrotizing Sialometaplasia

Necrotizing sialometaplasia is a rare minor salivary gland disease characterized by a destructive reactive inflammatory process of the salivary gland. It is usually found in hard palate's minor salivary glands with only 7.8–10.1% of necrotizing sialometaplasia found in parotid glands [54]. The disease can affect different age groups with no gender predilection, although when it comes to the major salivary glands, the disease seems to affect females more than males [55]. The exact etiology is believed to be due to an insufficient blood supply with resulting ischemia and necrosis.

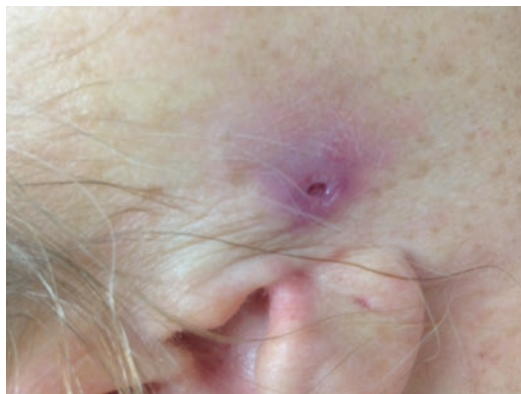

Fig. 15.8 Middle-age female presented with an ulcer extending into the right parotid gland. Biopsy was performed to rule out cancer or skin/parotid and showed sialometaplasia. Healed with steroid injection

The most common cause of necrotizing sialometaplasia of the hard palate is trauma during oral surgery procedures, while those in the parotid are blamed on iatrogenic injury during parotid surgery. Local radiation therapy, cocaine use, smoking, and pressure from local space-occupying lesions have also been suggested causes. It presents as a painless mass of the salivary gland with history suggestive of recurrence after surgery for a different primary pathology. There is no evidence of lymphadenopathy or facial nerve involvement. Diagnosis is confirmed histologically [56].

The awareness of this condition is critical as it is often confused for malignant neoplasm. An experienced surgeon and pathologist are keys to prevent unnecessary surgical intervention for this self-limiting disease. The differential diagnosis of necrotizing sialometaplasia includes mucoepidermoid carcinoma and squamous cell carcinoma (Fig. 15.8).

Microscopic diagnostic criteria include [1] lobular necrosis of salivary tissue [2] a time variable prominence of granulation tissue and acute and chronic inflammation, [3] squamous metaplasia conforming to a duct and/or acinar outlines, and [4] maintenance of the salivary lobular morphology. Complete resolution of hard palate typically occurs without any intervention usually within 3–12 weeks [54].

Granulomatous/Inflammatory Processes

Immunoglobulin G4-Related Salivary Disease (IgG4-RD)

IgG4-RD is a syndrome of unknown etiology; it can be a part of a systemic group of disorders affecting the pancreas, thyroid (Riedel's thyroiditis and a subset of Hashimoto's thyroiditis), peritoneum, and kidney [57, 58].

The hallmark of IgG4-RD is IgG4-positive plasma cells and small lymphocyte infiltration, which may be accompanied by fibrosis, obliterative phlebitis, and, in the majority of patients, elevated serum levels of IgG4 which helps in making the diagnosis although it is not diagnostic. Patients often present with unilateral or bilateral parotid or submandibular gland swelling. Lymphadenopathy and symptoms of asthma or allergy may be present. Good initial therapeutic response to glucocorticoids is very characteristic at a prednisone dose of 40 mg/day, which is then tapered to discontinuation over a 2-month period. Rituximab may be given to steroid nonresponders. Spontaneous remission has been reported. Relapse is described as an inflammatory reaction that can cause significant organ damage. Risk of malignancy exists (salivary duct carcinoma).

Sarcoidosis

Parotid gland involvement occurs in 6% of patients with sarcoidosis. It is commonly bilateral (73%), with higher incidence in middle-age females. Heerfordt's syndrome is described as bilateral parotid swelling, intrathoracic and peripheral lymphadenopathy, uveitis, lacrimal gland enlargement, and skin disease. Treatment is usually glucocorticoids [59].

Other granulomatous diseases that can affect salivary glands include tuberculosis, cat-scratch disease, syphilis, leprosy, actinomycosis, and rhinoscleroma. The treatment of these condi-

tions is geared toward treating the underlying condition rather than the localized salivary gland swelling.

References

1. Rice D. Non-inflammatory, non-neoplastic disorders of the salivary glands. *Otolaryngol Clin North Am.* 1999;32(5):835–42.
2. Bentz B, et al. Masses of the salivary gland region in children. *Arch Otolaryngol Head Neck Surg.* 2000;125:1435–9.
3. Shah G. MR imaging of salivary glands. *Neuroimaging Clin N Am.* 2004;14:777–808.
4. Inohara H, et al. The role of fine-needle aspiration cytology and magnetic resonance imaging in the management of parotid mass lesions. *Acta Otolaryngol.* 2008;128:1152–8.
5. Henke A, et al. Fine-needle aspiration cytology of lymphangioma of the parotid gland in an adult. *Diagn Cytopathol.* 2001;24(2):126–8.
6. Meer S, Dulabh S. Cystic lymphoid hyperplasia: an orofacial lesion strongly associated with HIV and AIDS. *Histopathology.* 2013;62:1067–74.
7. Varnholt H. Salivary gland lymphoepithelial cysts. *Ear Nose Throat Pathol.* 2007;86(5):265.
8. Meyer E, et al. Alcohol sclerotherapy of human immune deficiency virus related parotid lymphoepithelial cysts. *J Laryngol Otol.* 2009;123:422–5.
9. Mourad WF, et al. 25-year follow-up of HIV-positive patients with benign lymphoepithelial cysts of the parotid glands: a retrospective review. *Anticancer Res.* 2013;33(11):4927–32.
10. Ozmen Akgul A, et al. A rare case of dermoid cyst originating from the submandibular gland. *Internet J Radiol.* 2016;10(1):2.
11. Yigit N, et al. Dermoid cyst of the parotid gland: report of a rare entity with literature review. *Head Neck Pathol.* 2015;9:286–92.
12. Island S, Hoffman G. Parotid dermoid cyst: a rare entity. *J Laryngol Otol.* 2009;123(2):e7.
13. Darabi M, et al. Hydatid cyst of the parotid gland. *Oral Maxillofac Surg.* 2009;13:33–5.
14. Georgopoulos S, et al. Hydatid cyst in the duct of the submandibular gland. *Int J Oral Maxillofac Surg.* 2007;36:177–9.
15. Nasseri-Moghaddam S, Abrishami A, Taefi A, Malekzadeh R. Percutaneous needle aspiration injection, and re-aspiration with or without benzimidazole coverage for uncomplicated hepatic hydatid cysts. *Cochrane Database Syst Rev.* 2011;CD003623.
16. Atrduino PG, et al. Non-neoplastic salivary gland diseases. *Minerva Somatol.* 2006;55(5):249–70.
17. Zhao YF, Jia Y, XM C, WF Z. Clinical review of 580 ranulas. *Oral Surg Oral Med Oral Pathol Oral Radiol Endod.* 2004;98(3):1079–2104.

18. Bhaskar SN, Bolden TE, Weinmann JP. Pathogenesis and management of mucocoeles. *J Dent Res.* 1956;35:863–74.
19. Pandit RT, Park AH. Management of pediatric ranula. *Otolaryngol Head Neck Surg.* 2002;127(1):115–8.
20. McCaul JA, Lamey PJ. Multiple oral mucocoeles treated with gamma-linolenic acid: report of a case. *Br J Oral Maxillofac Surg.* 1994;32(6):392–3.
21. Luiz AC, Hiraki KR, Lemos CA Jr, Hirota SK, Migliari DA. Treatment of painful and recurrent oral mucocoeles with a high-potency topical corticosteroid: a case report. *J Oral Maxillofac Surg.* 2008;66(8):1737–9.
22. Rho MH, et al. OK-432 Sclerotherapy of plunging Ranula in 21 patients: it can be a substitute for surgery. *Am J Neuroradiol.* 2006;27(5):1090–5.
23. Woo H-J, Chi DH. Management of oral ranula. *Otolaryngol Head Neck Surg.* 2012;147(2 suppl):P166.
24. Amaral MBF, et al. Low level laser effect after micro-marsupialization technique in treating ranulas and mucocoeles: a case series report. *Lasers Med Sci.* 2012;27(6):1251–5.
25. Lai JB, Poon CY. Treatment of ranula using carbon dioxide laser—case series report. *Int J Oral Maxillofac Surg.* 2009;38(10):1107–11.
26. Sigismund PE, Bozzato A, Schumann M, Koch M, Iro H, Zenk J. Management of Ranula: 9 years' clinical experience in pediatric and adult patients. *J Oral Maxillofac Surg.* 2013;71(3):538–44.
27. Work WP. Newer concepts of first branchial cleft defects. *Laryngoscope.* 1972;82(9):1581–93.
28. D'souza AR, Uppal HS, De R, Zeitoun H. Updating concepts of first branchial cleft defects: a literature review. *Int J Pediatr Otorhinolaryngol.* 2002;62(2):103–9.
29. Zaifullah S, et al. Diagnosis and treatment of branchial cleft anomalies in UKMMC: a 10-year retrospective study. *Eur Arch Otorhinolaryngol.* 2013;270:1501–6.
30. Anand TS, Anand CS, Chaurasia BD. Seven cases of branchial cyst and sinuses in four generations. *Hum Hered.* 1979;29(4):213–6.
31. Zhipeng S, et al. Multidetector computerized tomographic fistulography in the evaluation of congenital branchial cleft fistulae and sinuses. *Oral Surg Oral Med Oral Pathol Oral Radiol.* 2012;113(5):688–94.
32. Ankur G, et al. First Branchial cleft cyst (type II). *Ear Nose Throat J.* 2009;88(11):1194–5.
33. Prabhu V, et al. First branchial arch fistula: diagnostic dilemma and improvised surgical management. *Am J Otolaryngol.* 2011;32:617–9.
34. Kim MG, Kim SG, Lee JH, Eun YG, Yeo SG. The therapeutic effect of OK-432 (picibanil) sclerotherapy for benign neck cysts. *Laryngoscope.* 2008;118(12):2177–81.
35. Achachea M, et al. Management of vascular malformations of the parotid area. *Eur Ann Otorhinolaryngol Head Neck Dis.* 2013;130:55–60.
36. Beahrs OH, Woolner LB, Carveth SW, et al. Surgical management of parotid lesions. Review of seven hundred sixty cases. *Arch Surg.* 1960;80:890–904.
37. Waner M, Suen JY. Management of congenital vascular lesions of the head and neck. *Oncology (Williston Park)* 1995;9(10):989–994, 997; discussion 998.
38. WR S, Kolhe PS, Smith FW, Murray GI. The 'turkey wattle' sign revisited: diagnosing parotid vascular malformations in the adult. *Br J Plast Surg.* 1997;50(1):43–6.
39. Koltsidopoulos P, Skoulakis C. Intramuscular hemangioma with turkey wattle sign. *CMAJ.* 2015;187(4):277.
40. Altman KW, Marchant FE, Ochs RH. Parotid cavernous hemangioma in an adult. *Ear Nose Throat J.* 1998;77(2):122–4.
41. Toufik B, Said A. Large cystic lymphangioma of the parotid gland in the adult. *Egyptian J Ear Nose Throat Allied Sci.* 2004;15(3):259–61.
42. Tsui S-C, Huang J-L. Parotid lymphangioma. A case report. *Int J Pediatr Otorhinolaryngol.* 1996;34:273–8.
43. Richter G, Braswell L. Management of venous malformation. *Facial Plast Surg.* 2012;28(6):603–10.
44. Yu-xiong S, et al. Sialoliths or Phleboliths? *Laryngoscope.* 2009;119:1344–7.
45. Brietzke S, et al. Nd:YAG interstitial laser therapy for pediatric arteriovenous malformations. *Operat Tech Otolaryngol.* 2001;12(4):239–44.
46. Orlando J, et al. Ethanol sclerotherapy of head and neck venous malformations. *Einstein (São Paulo).* 2014;12(2):181–6.
47. Kim HJ, Jeon BS, Lee KW. Hemimasticatory spasm associated with localized scleroderma and facial hemiatrophy. *Arch Neurol.* 2000;57(4):576–80.
48. Skoura C, et al. Masseteric hypertrophy associated with administration of anabolic steroids and unilateral mastication: a case report. *Oral Surg Oral Med Oral Pathol Oral Radiol Endod.* 2001;92(5):515–8.
49. Aydil B, et al. The use of botulinum toxin type a in masseter muscle hypertrophy: long-term effects and lasting improvement. *Kulak Burun Bogaz Ihtis Derg.* 2012;22(5):249–53.
50. Klein FH. Lower facial remodeling with botulinum toxin type a for the treatment of masseter hypertrophy. *An Bras Dermatol.* 2014;89(6):878–84.
51. Fedorowicz Z. Botulinum toxin for masseter hypertrophy. *Cochrane Database Syst Rev.* 2013; CD007510.
52. Cabello M, et al. Pneumoparotid associated with a mandibular advancement device for obstructive sleep apnea. *Sleep Med.* 2015;16(8):1011–3.
53. Ramón L, et al. Pneumoparotid: a case report and review of the literature. *J Oral Maxillofac Surg.* 2008;66:362–5.
54. Brannon RB, Fowler CB, Hartman KS. Necrotizing sialometaplasia. A clinicopathologic study of sixty-nine cases and review of the literature. *Oral Surg Oral Med Oral Pathol.* 1991;72:317–25.

55. Batsakis JG, Manning JT. Necrotizing sialometaplasia of major salivary glands. *J Laryngol Otol.* 1987;101:962–6.
56. Kim YH, et al. A case of necrotizing sialometaplasia involving bilateral parotid glands. *Am J Otolaryngol.* 2013;34(2):163–5.
57. Stone JH, Zen Y, Deshpande V. IgG4-related disease. *N Engl J Med.* 2012;366(6):539–51.
58. <http://www.uptodate.com/contents/overview-of-igg4-related-disease>
59. James DG, Sharma OP. Parotid gland sarcoidosis. *Sarcoidosis Vasc Diffuse Lung Dis.* 2000;17(1):27–32.

Part V

Management of Salivary Medical Conditions

Mihir K. Bhayani and Stephen Y. Lai

Key Points

1. Xerostomia is the subjective complaint of dry mouth that may or may not be associated with salivary gland hypofunction.
2. Patients with xerostomia can experience a wide range of symptoms that can have significant impact on quality of life.
3. The cause of xerostomia is multifactorial, and thorough evaluation must be completed to identify the source.
4. Treatment focuses on symptom improvement via salivary gland stimulation and/or substitution to prevent significant oral morbidity. Multiple treatment options are available and are reviewed in this chapter.

Introduction

Xerostomia is defined as the subjective sensation of dry mouth. This is a frequent chief complaint by many patients seen in an otolaryngology office. Salivary gland hypofunction, on the other hand, is the objective identification of reduced salivary flow in the oral cavity. Although xerostomia is frequently seen in patients with impaired salivary flow, it can also be diagnosed in patients with normal saliva production. A reduction in salivary flow by as little as 30% can create enough disruption in quality of life for many patients to complain of xerostomia [1]. The effect of perceived or actual absence of saliva has significant sequelae related to the patient's oral health and quality of life.

Saliva has multiple functions involved in the maintenance of adequate oral hygiene. It buffers the oral mucosa and, in conjunction with the release of lysozyme and glycoprotein, acts as a first line of defense against oral flora [2]. The moisture can lubricate dry foods to facilitate mastication and propulsion of the oral bolus. It also can cool hot foods while providing a medium for dissolved foods to stimulate the taste buds. Amylase within saliva begins the digestive process in the oral cavity. Salivary phosphates and calcium act to mineralize teeth and protect them from caries [3]. Therefore, the loss of salivary function can cause taste disturbance, dysphagia, oral fungal infections, and dental caries.

M.K. Bhayani, M.D.
Division of Otolaryngology, NorthShore University
HealthSystem/Pritzker School of Medicine University
of Chicago, Evanston, IL, USA

S.Y. Lai, M.D. Ph.D. (✉)
Department of Head and Neck Surgery, University of
Texas MD Anderson Cancer Center, Houston,
TX, USA

Department of Molecular and Cellular Oncology,
University of Texas MD Anderson Cancer Center,
Houston, TX, USA
e-mail: SYLai@mdanderson.org

The paired major salivary glands (parotid, submandibular, and sublingual glands) account for 90% of salivary production, with the remaining 10% coming from the minor salivary glands [4]. An average healthy individual will generate 1–1.5 L of saliva per day [5]. The basal rate of salivary flow is approximately 0.3–0.4 mL/min, with about 65% of the production from the submandibular glands. Stimulated salivary flow is 1.5–2.0 mL/min with the parotid glands providing 50% of the output [5, 6]. Salivary secretion is controlled by autonomic input from both sympathetic and parasympathetic nerves. The parasympathetic stimulation increases water and electrolyte secretion, while sympathetic stimuli lead to secretion of protective proteins, such as immunoglobulins and enzymes [7]. Salivary flow also has a circadian pattern with low flow periods occurring during sleep and peak flow during stimulated periods. Seasonal variation can be seen with salivary flow being lowest in the summer months and peak flow rates during the winter [5].

Understanding the function and origin of the saliva can help practitioners identify the causes of xerostomia, impaired salivary function, and its effect on the patient. The net result is to provide preventative measures and symptom relief. Toward that end, this chapter describes the epidemiology, etiology, diagnostic workup, and treatment options in patients with xerostomia and salivary gland hypofunction.

Epidemiology

The prevalence of xerostomia in the United States ranges from 10 to 40% [8]. Population studies from Europe have placed the prevalence of xerostomia as high as 65% [9]. Women and the elderly are more likely to be affected by xerostomia. 99% of patients in one survey who had >1 chronic medical condition complained of dry mouth. Younger patients are more likely to have xerostomia as a result of systemic disease or a high BMI, while patients greater than the age of 50 have xerostomia as a result of medication usage [10, 11].

Table 16.1 Medical conditions associated with xerostomia

Condition	Example
Treatment related	Radiation therapy, medications
Systemic	Sjogren’s, rheumatoid arthritis
Infection	HIV, hepatitis C
Anatomic	Mouth breathing, dehydration
Psychogenic	Mood disorder

Etiology

There are several causes of xerostomia that have salivary and non-salivary origins. Table 16.1 lists the most common medical conditions associated with xerostomia. Although the use of xerogenic medications is the most common reason for xerostomia in the elderly, age-related salivary acinar fibrosis and fat replacement have also been noted in this vulnerable population [12–15]. In addition, mood disorders, such as anxiety and depression, are frequently associated with dry mouth and poor oral health [16, 17]. Dehydration can lead to significant salivary gland hypofunction, regardless of age [18]. Anatomic alterations that lead to mouth breathing can also cause oral dryness. Other than these factors, we have highlighted major causes of xerostomia in the following categories described below:

Treatment Side Effects

Medication-induced xerostomia is the most common cause in patients older than 50 [10]. While many medications (>400) create the sensation of dry mouth, only a few medications reduce salivary flow [11]. Anticholinergic drugs such as tricyclic antidepressants can result in hyposalivation and xerostomia. Antihypertensives that are α -adrenergic antagonist can cause hyposalivation [19]. Table 16.2 lists other common medication classes involved in xerostomia.

Radiation therapy (RT) to the head and neck can have a significant effect on the salivary gland parenchyma and function with as little as 10 Gy causing a 30% decline in salivary flow [22, 23]. In one survey of 39 long-term survivors of head

Table 16.2 Medications commonly associated with xerostomia

Drug category	Example
Antidepressants	Amitriptyline, citalopram, fluoxetine
Antipsychotics	Risperidone, diazepam
Antiparkinson	Benzatropine
Antihypertensives	Methyldopa, clonidine
Diuretics	Furosemide, thiazides
Decongestants	Pseudoephedrine
Urological	Oxybutynin, tamsulosin
Gastrointestinal agents	Hyoscine, dicyclomine
Antihistamine	Cetirizine, fexofenadine

Source: Villa [20], Visvanathan [21]

and neck cancer (HNC) after treatment with primary radiation alone, almost two thirds of these patients complained of xerostomia [24].

Radioactive iodine (RI) treatment for thyroid cancer is a previously underappreciated cause of xerostomia. In a small series of 26 patients, 85% of patients seeking treatment for RI-induced sialadenitis, defined as swelling and pain in the affected glands, also complained of xerostomia [25]. Radioiodine exerts its effects on the salivary parenchyma by replacement of chloride in the $\text{Na}^+/\text{K}^+/\text{Cl}^-$ symporter [26]. Symptoms are dependent on cumulative dose and treatments.

Systemic Disease

Diabetes, chronic graft vs. host disease, hemodialysis, and hypertension are common systemic diseases in which patients also complain of dry mouth. In studies of diabetes, 54% of patients complain of xerostomia, and measurements of salivary flow were found to be significantly diminished compared to healthy controls [27, 28]. Many patients with rheumatologic disorders present with xerostomia. Rheumatoid arthritis, systemic lupus erythematosus, primary biliary cirrhosis, sarcoidosis, and Wegener's granulomatosis are all known to cause xerostomia [4, 29]. However, the xerostomia seen in these disorders may be related to the overlapping presence of Sjogren's disease (SD) [30, 31]. SD is the most common

Table 16.3 Diagnostic criteria for Sjogren's disease^a from AECG [34]

Inclusion criteria
I. Ocular symptoms (dry eyes requiring tear substitutes)
II. Oral symptoms (dry mouth, swollen salivary glands)
III. Ocular signs (Schirmer's test)
IV. Minor salivary gland biopsy (focal lymphocytic sialadenitis)
V. Salivary gland testing (sialometry, sialography)
VI. Presence of elevated serum autoantibodies (anti-Ro/SSA or anti-La/SSB)

^aTo diagnose Sjogren's disease: (1) presence of any four of the six criteria with a positive minor salivary biopsy or serology; (2) presence of three of the four objective criteria (III–VI)

rheumatologic disorder causing xerostomia. This disease affects an estimated four million people, and women comprise 90% of those affected [32]. It is characterized by a lymphoplasmacytic infiltration of exocrine glands, specifically the salivary and lacrimal glands. Therefore, common manifestations of this disease include dry mouth and dry eyes, otherwise known as the sicca complex [33]. Other symptoms of this disease include sialadenitis, peripheral neuropathy, polyarthritis, cystitis, and pulmonary fibrosis. The diagnosis of this disease is based on fulfilling criteria from the joint American-European Consensus Group (AECG) summarized in Table 16.3 [34]. Diagnostic workup for this disease is detailed later in this chapter.

Infection

Human immunodeficiency virus (HIV), hepatitis C, and mumps are known viral illness that can cause xerostomia. HIV, in particular, can create a clinical picture similar to SD in what is known as diffuse infiltrative lymphocytosis syndrome (DILS). This process is characterized by a T-cell infiltration of the salivary glands [35]. Hepatitis C has also been found to function in a similar fashion, and small clinical series have identified the presence of the virus in salivary tissues [36–38].

Diagnosis

The diagnostic workup of a patient who complains of oral dryness starts with a basic history and physical.

History

Timing of dryness, taste perception, dysphagia, tolerance to dry foods, change in tolerance to acidic or spicy foods, hydration status, oral burning or pain, and dental health need to be assessed. Chronic nasal symptoms and sleep patterns are covered as well. Medication usage, change in medication dosages, and social stressors should also be addressed at this time.

Several questionnaires have been developed and validated for the evaluation of xerostomia. An eight-item xerostomia questionnaire (XQ) based on a Likert scale from 0 to 10 has been used in the assessment of patients with dry mouth and validated in multiple studies of patients with previous irradiation for head and neck cancer (Table 16.4) [39–43]. In addition, the XQ has been translated into multiple languages with reproducible results [40, 41].

Table 16.4 Xerostomia questionnaire (XQ)

Rate the difficulty you experience in speaking due to dryness of your mouth and tongue (Easy → extremely difficult)
Rate the difficulty you experience in chewing food due to dryness (easy → extremely difficult)
Rate the difficulty you experience in swallowing food due to dryness (easy → extremely difficult)
Rate the dryness your mouth feels when eating a meal (no dryness → extreme dryness)
Rate the dryness in your mouth while not eating or chewing (no dryness → extreme dryness)
Rate the frequency of sipping liquids to aid in the swallowing of food (none required → extremely frequent)
Rate the frequency of sleeping problems due to dryness (none → extremely frequent)
Rate the frequency of fluid intake required for oral comfort when not eating (none required → extremely frequent)

Adapted from Pai [39]

Physical Exam

The physical findings for a patient with xerostomia and salivary gland hypofunction starts with evaluation of skin turgor, which can be decreased as a result of severe dehydration. The oral examination of patients will show cracked and peeling lips, glassy appearance of the oral mucosa, fissured tongue, and loss of papillae on the tongue. The tongue and oral mucosa may have ulcerations or leukoplakic lesions. Lack of pooling of saliva in the floor of mouth is a common finding. The parotid and submandibular papillae may be effaced, and massage of those glands will produce a thick, mucoid, or gelatinous quality of saliva to no saliva being expressed, which are indicative of impaired function. Dental caries and gingival recession are also common findings.

Diagnostic Tests

Initial diagnostic testing of patients with oral dryness can start with laboratory studies. Complete blood count, erythrocyte sedimentation rate, liver function tests, and autoimmune panels that contain anti-SSA (Sjogren’s syndrome-related A/anti-Ro antigen) and anti-SSB (Sjogren’s syndrome-related B/anti-La antigen) antibodies are critical first tests. The presence of sicca symptoms and abnormal SSA/B serology is diagnostic of SD, but the antibodies are only present in 50% of cases [44].

Minor salivary gland biopsy is a useful test for diagnosis of SD. It can be performed easily in the office with minimal morbidity. An incision is made in the labial mucosa, and at least four salivary lobules should be removed. A standard 4-point grading system is used to stratify the results. Those patients with grade 3 or 4 biopsies have a positive test [33, 45].

Objective measurement of salivary flow involves collection of both unstimulated whole saliva (UWS) and stimulated whole saliva (SWS). Saliva collection can occur by multiple techniques [46]. For directed measurement of the parotid glands, the duct can be cannulated and saliva collected using a Lashley cup situated on

the buccal mucosa. The submandibular gland salivary flow can be collected with direct collection of the floor of mouth; however, one must be cautious with interpretation of the amount collected, as the collected saliva will also contain output from the sublingual gland [47]. One method for general salivary collection is to allow pooling of saliva for 5 min with head tilted slightly forward and collecting the UWS in a graduated cylinder. SWS is assessed by rinsing with 20 mL of citric acid solution or chewing an unflavored gum for 1 min, followed by a 5-min collection period [25, 46]. UWS below 0.12–0.16 mL/min and a SWS flow rate below 0.5 mL/min are considered indicative of hyposalivation [46].

Treatment

The treatment of xerostomia focuses on reducing patient symptoms with the possibility of increasing salivary flow. Initial management should focus on control of the underlying cause. For symptom control, hydration, discontinuation or reduction of xerogenic medications, and increased humidity indoors may be effective initial steps. However, many patients require the use of salivary substitutes or stimulants that are detailed below. We also will review preventative measures for patients at risk of developing xerostomia that may slow its progression.

Saliva Substitutes

The purpose of salivary substitutes is to mimic the environment of normal oral mucosa. These agents are typically topical therapies that lubricate the oral cavity for the purposes of symptom alleviation. Most contain a viscous product composed of carboxymethylcellulose, hydroxyethylcellulose, xylitol, or sorbitol formulated as a lozenge, chewing gum, oil, gel, rinse, or spray. A recent Cochrane review identified 36 randomized trials comparing specific treatments of dry mouth due to any cause [48]. These trials included 39 different topical agents, either as a single agent or combination therapy, and com-

pared them to either a placebo (12 of the 36 trials) or another active intervention (24 of the 36 trials). Fifteen of these trials used objective measures of saliva flow, and the other trials used various combinations of quality of life scores and xerostomia inventory. The results of these trials were mixed due to the significant variability among individuals and the transient symptom relief from applying a topical therapy. Therefore, patients and physicians should be aware of all of the agents available for use with treatments tailored to their particular situation and preference.

Saliva Stimulants

Pilocarpine and cevimeline are Food and Drug Administration-approved medications for treatment of xerostomia in post-RT and SD patients. They act as parasympathomimetics and are agonists for muscarinic receptors that can stimulate salivary flow. Pilocarpine is a nonselective muscarinic agonist. Cevimeline has specific affinity M1 and M3 muscarinic receptors that are located in glandular tissues and not M2 receptors that are seen in cardiac tissues [49]. Dosing is three to four times per day and can be tailored to patient symptom relief and tolerance. Side effects are common and dose dependent. These effects include sweating, urinary frequency, headache, dizziness, blurry vision, and nausea. A Cochrane review of the effects of pilocarpine found between 47 and 51% response rate for three trials that were completed in 1990s [50]. More recent evaluations of cevimeline found improvement in UWS but found no improvement in subjective descriptions of xerostomia [23, 49]. Bethanechol is a nonselective muscarinic agonist that is approved for use in patients with urinary retention but is also effective in treatment of xerostomia. Two recent trials using bethanechol have demonstrated subjective xerostomia relief, with only 38% of patients in the treatment group in one trial complaining of xerostomia at the RT vs. 72% of patients in the placebo group. Both trials showed improvement in UWS after RT for head and neck cancer [51, 52].

Other Interventions

Interventions that do not use saliva substitution or saliva stimulants have also been studied. Acupuncture has been found to alleviate xerostomia symptoms in post-RT patients based on questionnaire responses, but objective studies have not been performed to assess effect on stimulated salivary flow [53, 54]. Electrostimulation has come with subjective success in treatment of SD, but study of salivary flow showed no measurable difference [32, 55].

Salivary endoscopy (sialendoscopy) has been recently introduced into clinical practice as a minimally invasive method to alleviate sialadenitis. Mucosal appearance of the duct is similar to one seen in patients with chronic sialadenitis (Fig. 16.1). It has shown some benefit in UWS, and 76% of patients reported a subjective improvement in xerostomia symptoms in a small series of patients with RI-induced sialadenitis [25]. Of note, a greater benefit related to improvement of obstructive sialadenitis and its associated symptoms was noted in this series following sialendoscopy. Thus, practitioners must carefully consider the benefit to patients when considering sialendoscopy when xerostomia is the sole salivary-related symptom.

Medications aimed at reducing RT-induced xerostomia have been largely unsuccessful. A recent meta-analysis evaluating the radioprotective drug amifostine did not find a statistically significant benefit [56]. Fortunately, preventative measures aimed at reducing xerostomia after RT have been revolutionized by the use of intensity-modulated radiation therapy (IMRT) [57], which can reduce the dose delivered to the salivary glands. Efforts at sparing the parotid glands in treatment planning using 3D conformal techniques have also been successful in preventing xerostomia without compromising tumor control [58]. In addition, the introduction of proton-based radiation therapy as a treatment option in HNC has the potential to significantly reduce xerostomia. Proton therapy releases its energy at a more defined depth with less collateral spread [59]. A feasibility study in 10 HNC patients treated with proton therapy has shown an improvement in objective salivary flow by 17% compared to IMRT [60]. A larger randomized trial at a single institution comparing 50 patients receiving proton therapy to 100 patients receiving IMRT demonstrated patient reported grade 2 or higher xerostomia was 62% less in the proton therapy group compared to the IMRT group ($p < 0.05$) [61]. The results of these studies show significant

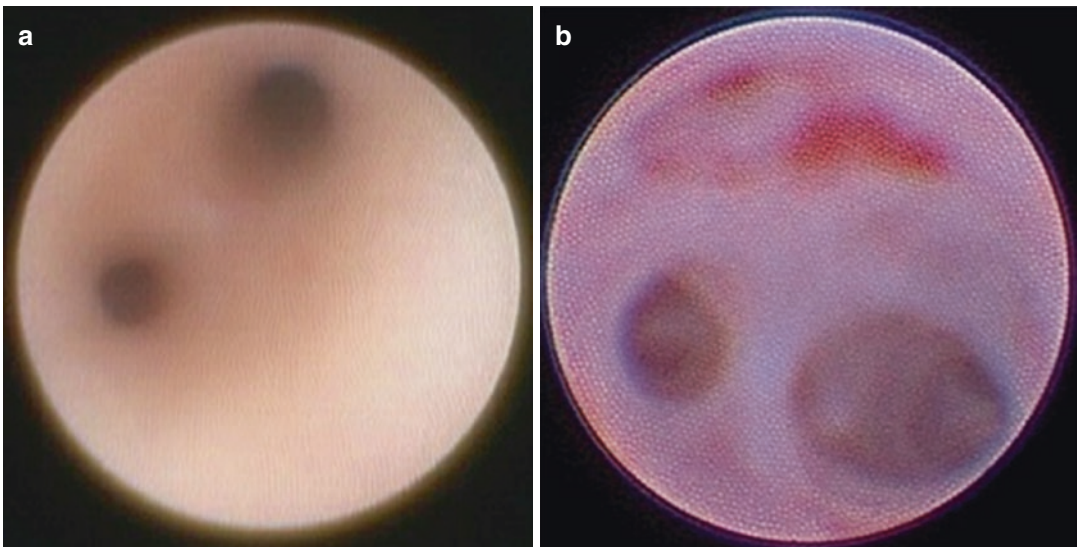


Fig. 16.1 Endoscopic appearance of normal (a) and inflamed (b) parotid duct. Image in b is of a patient with complaint of xerostomia with no complaints of pain or swelling of the gland

promise toward the use of proton therapy in HNC in an effort to reduce salivary-related morbidity.

Conclusions

Xerostomia and salivary gland hypofunction are related disorders that can have significant impact on a patient's quality of life. Recognition of underlying causes of xerostomia or salivary gland hypofunction is critical in determining effective treatment. Many treatments are available to patients, and therapy should be tailored to patient-specific response and preference. Close follow-up with these patients within a multidisciplinary practice that includes dentistry is needed to prevent oral complications of xerostomia.

References

1. Dawes C, Odum O. Salivary status in patients treated for head and neck cancer. *J Can Dent Assoc.* 2004;70(6):397–400.
2. Amerongen AV, Veerman EC. Saliva—the defender of the oral cavity. *Oral Dis.* 2002;8(1):12–22.
3. Plemons JM, Al-Hashimi I, Marek CL. American Dental Association Council on Scientific Affairs. Managing xerostomia and salivary gland hypofunction: executive summary of a report from the American Dental Association Council on Scientific Affairs. *J Am Dent Assoc.* 2014;145(8):867–73.
4. Napenas JJ, Brennan MT, Fox PC. Diagnosis and treatment of xerostomia (dry mouth). *Odontology.* 2009;97(2):76–83.
5. Humphrey SP, Williamson RT. A review of saliva: normal composition, flow, and function. *J Prosthet Dent.* 2001;85(2):162–9.
6. Villa A, Connell CL, Abati S. Diagnosis and management of xerostomia and hyposalivation. *Ther Clin Risk Manag.* 2015;11:45–51.
7. Ekstrom J. Neuropeptides and secretion. *J Dent Res.* 1987;66(2):524–30.
8. Billings RJ, Proskin HM, Moss ME. Xerostomia and associated factors in a community-dwelling adult population. *Community Dent Oral Epidemiol.* 1996;24(5):312–6.
9. Orellana MF, Lagraverre MO, Boychuk DG, Major PW, Flores-Mir C. Prevalence of xerostomia in population-based samples: a systematic review. *J Public Health Dent.* 2006;66(2):152–8.
10. Flink H, Bergdahl M, Tegelberg A, Rosenblad A, Lagerlof F. Prevalence of hyposalivation in relation to general health, body mass index and remaining teeth in different age groups of adults. *Community Dent Oral Epidemiol.* 2008;36(6):523–31.
11. Liu B, Dion MR, Jurasic MM, Gibson G, Jones JA. Xerostomia and salivary hypofunction in vulnerable elders: prevalence and etiology. *Oral Surg Oral Med Oral Pathol Oral Radiol.* 2012;114(1):52–60.
12. Scott J, Bodner L, Baum BJ. Assessment of age-related changes in the submandibular and sublingual salivary glands of the rat using stereological analysis. *Arch Oral Biol.* 1986;31(1):69–71.
13. Locker D. Xerostomia in older adults: a longitudinal study. *Gerodontology.* 1995;12(1):18–25.
14. Gupta A, Epstein JB, Sroussi H. Hyposalivation in elderly patients. *J Can Dent Assoc.* 2006;72(9):841–6.
15. Navazesh M. Salivary gland hypofunction in elderly patients. *J Calif Dent Assoc.* 1994;22(3):62–8.
16. Kisely S, Baghaie H, Lalloo R, Siskind D, Johnson NW. A systematic review and meta-analysis of the association between poor oral health and severe mental illness. *Psychosom Med.* 2015;77(1):83–92.
17. Wey MC, Loh S, Doss JG, Abu Bakar AK, Kisely S. The oral health of people with chronic schizophrenia: a neglected public health burden. *Aust N Z J Psychiatry.* 2015;50:685–94.
18. Fischer D, Ship JA. The effect of dehydration on parotid salivary gland function. *Spec Care Dentist.* 1997;17(2):58–64.
19. Croog SH, Levine S, Testa MA, et al. The effects of antihypertensive therapy on the quality of life. *N Engl J Med.* 1986;314(26):1657–64.
20. Villa A, Wolff A, Aframian D, et al. World workshop on oral medicine VI: a systematic review of medication-induced salivary gland dysfunction: prevalence, diagnosis, and treatment. *Clin Oral Investig.* 2015;19(7):1563–80.
21. Visvanathan V, Nix P. Managing the patient presenting with xerostomia: a review. *Int J Clin Pract.* 2010;64(3):404–7.
22. Eisbruch A, Ship JA, Kim HM, Ten Haken RK. Partial irradiation of the parotid gland. *Semin Radiat Oncol.* 2001;11(3):234–9.
23. Chambers MS, Posner M, Jones CU, et al. Cevimeline for the treatment of postirradiation xerostomia in patients with head and neck cancer. *Int J Radiat Oncol Biol Phys.* 2007;68(4):1102–9.
24. Wijers OB, Levendag PC, Braaksma MM, Boonzaaijer M, Visch LL, Schmitz PI. Patients with head and neck cancer cured by radiation therapy: a survey of the dry mouth syndrome in long-term survivors. *Head Neck.* 2002;24(8):737–47.
25. Bhayani MK, Acharya V, Kongkiatkamon S, et al. Sialendoscopy for patients with radioiodine-induced Sialadenitis and Xerostomia. *Thyroid.* 2015;25(7):834–8.
26. Van Nostrand D. Sialoadenitis secondary to (1)(3)(1) I therapy for well-differentiated thyroid cancer. *Oral Dis.* 2011;17(2):154–61.
27. Sandberg GE, Wikblad KF. Oral dryness and peripheral neuropathy in subjects with type 2 diabetes. *J Diabetes Complications.* 2003;17(4):192–8.
28. Chavez EM, Taylor GW, Borrell LN, Ship JA. Salivary function and glycemic control in older persons with

- diabetes. *Oral Surg Oral Med Oral Pathol Oral Radiol Endod.* 2000;89(3):305–11.
29. Carey EJ, Ali AH, Lindor KD. Primary biliary cirrhosis. *Lancet.* 2015;386(10003):1565–75.
 30. Guellec D, Cornec-Le Gall E, Groh M, et al. ANCA-associated vasculitis in patients with primary Sjogren's syndrome: detailed analysis of 7 new cases and systematic literature review. *Autoimmun Rev.* 2015;14(8):742–50.
 31. Iaccarino L, Gatto M, Bettio S, et al. Overlap connective tissue disease syndromes. *Autoimmun Rev.* 2013;12(3):363–73.
 32. Furness S, Bryan G, McMillan R, Worthington HV. Interventions for the management of dry mouth: non-pharmacological interventions. *Cochrane Database Syst Rev.* 2013;8:CD009603.
 33. Bamba R, Sweiss NJ, Langerman AJ, Taxy JB, Blair EA. The minor salivary gland biopsy as a diagnostic tool for Sjogren syndrome. *Laryngoscope.* 2009;119(10):1922–6.
 34. Rasmussen A, Ice JA, Li H, et al. Comparison of the American-European Consensus Group Sjogren's syndrome classification criteria to newly proposed American College of Rheumatology criteria in a large, carefully characterised sicca cohort. *Ann Rheum Dis.* 2014;73(1):31–8.
 35. Ghrenassia E, Martis N, Boyer J, Burel-Vandenbos F, Mekinian A, Coppo P. The diffuse infiltrative lymphocytosis syndrome (DILS). A comprehensive review. *J Autoimmun.* 2015;59:19–25.
 36. Verbaan H, Carlson J, Eriksson S, et al. Extrahepatic manifestations of chronic hepatitis C infection and the interrelationship between primary Sjogren's syndrome and hepatitis C in Swedish patients. *J Intern Med.* 1999;245(2):127–32.
 37. Khonsari RH, Maylin S, Nicol P, et al. Sicca syndrome and dementia in a patient with hepatitis C infection: a case report with unusual bifocal extrahepatic manifestations. *J Maxillofac Oral Surg.* 2015;14(Suppl 1):388–92.
 38. Toussirot E, Le Huede G, Mougin C, Balblanc JC, Bettinger D, Wendling D. Presence of hepatitis C virus RNA in the salivary glands of patients with Sjogren's syndrome and hepatitis C virus infection. *J Rheumatol.* 2002;29(11):2382–5.
 39. Pai S, Ghezzi EM, Ship JA. Development of a Visual Analogue Scale questionnaire for subjective assessment of salivary dysfunction. *Oral Surg Oral Med Oral Pathol Oral Radiol Endod.* 2001;91(3):311–6.
 40. Pellegrino F, Groff E, Bastiani L, Fattori B, Sotti G. Assessment of radiation-induced xerostomia: validation of the Italian version of the xerostomia questionnaire in head and neck cancer patients. *Support Care Cancer.* 2015;23(4):925–32.
 41. Lin SC, Jen YM, Chang YC, Lin CC. Assessment of xerostomia and its impact on quality of life in head and neck cancer patients undergoing radiotherapy, and validation of the Taiwanese version of the xerostomia questionnaire. *J Pain Symptom Manage.* 2008;36(2):141–8.
 42. Jabbari S, Kim HM, Feng M, et al. Matched case-control study of quality of life and xerostomia after intensity-modulated radiotherapy or standard radiotherapy for head-and-neck cancer: initial report. *Int J Radiat Oncol Biol Phys.* 2005;63(3):725–31.
 43. Eisbruch A, Kim HM, Terrell JE, Marsh LH, Dawson LA, Ship JA. Xerostomia and its predictors following parotid-sparing irradiation of head-and-neck cancer. *Int J Radiat Oncol Biol Phys.* 2001;50(3):695–704.
 44. Carubbi F, Alunno A, Cipriani P, et al. Is minor salivary gland biopsy more than a diagnostic tool in primary Sjogren's syndrome? Association between clinical, histopathological, and molecular features: a retrospective study. *Semin Arthritis Rheum.* 2014;44(3):314–24.
 45. Langerman AJ, Blair EA, Sweiss NJ, Taxy JB. Utility of lip biopsy in the diagnosis and treatment of Sjogren's syndrome. *Laryngoscope.* 2007;117(6):1004–8.
 46. Navazesh M, Kumar SK. University of Southern California School of D. Measuring salivary flow: challenges and opportunities. *J Am Dent Assoc.* 2008;139(Suppl 3):S5–40S.
 47. Cheng SC, Wu VW, Kwong DL, Ying MT. Assessment of post-radiotherapy salivary glands. *Br J Radiol.* 2011;84(1001):393–402.
 48. Furness S, Worthington HV, Bryan G, Birchenough S, McMillan R. Interventions for the management of dry mouth: topical therapies. *Cochrane Database Syst Rev.* 2011;12:CD008934.
 49. Witsell DL, Stinnett S, Chambers MS. Effectiveness of cevimeline to improve oral health in patients with post-radiation xerostomia. *Head Neck.* 2012;34(8):1136–42.
 50. Davies AN, Thompson J. Parasympathomimetic drugs for the treatment of salivary gland dysfunction due to radiotherapy. *Cochrane Database Syst Rev.* 2015;10:CD003782.
 51. Jham BC, Teixeira IV, Aboud CG, Carvalho AL, Coelho Mde M, Freire AR. A randomized phase III prospective trial of bethanechol to prevent radiotherapy-induced salivary gland damage in patients with head and neck cancer. *Oral Oncol.* 2007;43(2):137–42.
 52. Jaguar GC, Lima EN, Kowalski LP, et al. Double blind randomized prospective trial of bethanechol in the prevention of radiation-induced salivary gland dysfunction in head and neck cancer patients. *Radiother Oncol.* 2015;115(2):253–6.
 53. Pfister DG, Cassileth BR, Deng GE, et al. Acupuncture for pain and dysfunction after neck dissection: results of a randomized controlled trial. *J Clin Oncol.* 2010;28(15):2565–70.
 54. Johnstone PA, Niemtzow RC, Riffenburgh RH. Acupuncture for xerostomia: clinical update. *Cancer.* 2002;94(4):1151–6.
 55. Talal N, Quinn JH, Daniels TE. The clinical effects of electrostimulation on salivary function of Sjogren's syndrome patients. A placebo controlled study. *Rheumatol Int.* 1992;12(2):43–5.
 56. Gu J, Zhu S, Li X, Wu H, Li Y, Hua F. Effect of amifostine in head and neck cancer patients treated with

- radiotherapy: a systematic review and meta-analysis based on randomized controlled trials. *PLoS One*. 2014;9(5):e95968.
57. Vergeer MR, Doornaert PA, Rietveld DH, Leemans CR, Slotman BJ, Langendijk JA. Intensity-modulated radiotherapy reduces radiation-induced morbidity and improves health-related quality of life: results of a nonrandomized prospective study using a standardized follow-up program. *Int J Radiat Oncol Biol Phys*. 2009;74(1):1–8.
58. Dirix P, Nuyts S, Van den Bogaert W. Radiation-induced xerostomia in patients with head and neck cancer: a literature review. *Cancer*. 2006;107(11):2525–34.
59. Henriques de Figueiredo B, Gregoire V. How to minimize morbidity in radiotherapy of pharyngolaryngeal tumors? *Curr Opin Otolaryngol Head Neck Surg*. 2016;24(2):163–9.
60. van Dijk LV, Steenbakkers RJ, ten Haken B, et al. Robust intensity modulated proton therapy (IMPT) increases estimated clinical benefit in head and neck cancer patients. *PLoS One*. 2016;11(3):e0152477.
61. Blanchard P, Garden AS, Gunn GB, et al. Intensity-modulated proton beam therapy (IMPT) versus intensity-modulated photon therapy (IMRT) for patients with oropharynx cancer—a case matched analysis. *Radiother Oncol*. 2016;120(1):48–55.

Key Points

1. Sialorrhea is a common condition affecting both children and adults with neuromuscular disorders including cerebral palsy, Parkinson's disease, amyotrophic lateral sclerosis, and other neurodegenerative disorders.
2. Sialorrhea is a highly distressing problem that can lead to significant psychological, social, and medical issues.
3. A multidisciplinary approach involving speech therapy, neurology, otolaryngology, and others is advisable to help with the complex decision-making process.
4. In most cases, noninvasive therapeutic modalities such as physiotherapy and systemic medication should be explored prior to more invasive therapies such as the injection of botulinum toxin and surgery.
5. There is no consensus as to the best surgical procedure to treat sialorrhea. Procedure selection should be guided by patient characteristics including severity of drooling, presence of aspiration, and overall medical condition. It is imperative to give patients and their families clear expectations of treatment.

Introduction

Sialorrhea, or drooling, is a debilitating problem defined as the involuntary flow of saliva beyond the lip margin. The term is often used synonymously with ptyalism and hypersalivation, which more accurately describe rare instances of increased saliva production. Sialorrhea is rare in these conditions, as individuals with otherwise normal swallowing and oral continence care are able to manage the increased salivary volume. In this context, the presence of pathologic sialorrhea generally implies a neuromuscular or anatomical abnormality, with subsequent oral motor dysfunction, diminished oral sensation, or impaired swallowing [1].

Normal salivation produces approximately 1.5 L of saliva each day, most of which comes from three pairs of major salivary glands: parotid, submandibular, and sublingual. Production of saliva differs based on activity. The submandibular glands are responsible for roughly 70% of the total volume as well as the majority of saliva produced during unstimulated times. Although the parotid glands are the largest of the major salivary glands, they contribute only 25% of the overall saliva volume. During times of stimulation, such as eating and chewing, however, the parotid glands are responsible for nearly 70% of saliva production. The remaining 5% is divided between the sublingual glands and the minor salivary glands scattered throughout the oral cavity

K. Withrow, M.D. (✉) • T. Chung, M.D.
Department of Otolaryngology—Head and Neck
Surgery, University of Alabama—Birmingham,
563 BDB, 1530 3rd Ave S, Birmingham,
AL 35294-0012, USA
e-mail: kwithrow@uab.edu; tchung@uabmc.edu

and is less influenced by autonomic innervation [2]. It is crucial to have an understanding of salivary anatomy and physiology when managing sialorrhea, particularly when considering the ideal surgical treatment.

Epidemiology

While there is no data regarding the prevalence of sialorrhea in the general population, such data has been reported for certain high-risk populations. In adults, the most common cause is Parkinson's disease, whereas pediatric sialorrhea is most commonly associated with cerebral palsy. In both groups, the prevalence of sialorrhea is as high as 50% [3, 4].

Drooling is a normal phenomenon in infants and toddlers and is only considered pathologic when it persists after the age of 4 [5]. It can result in significant social, psychological, and medical consequences. Such patients are often ostracized and stigmatized, which can lead to depression and social isolation. People are generally reluctant to interact with drooling individuals. Successful treatment of severe drooling has been shown to improve social interaction in children with cerebral palsy [6]. In addition, the care of drooling patients is often labor intensive, necessitating the changing of clothes multiple times per day, bib changes an average of 7 times per day, and up to 25 loads of laundry each week [7]. While the presence of excess saliva in the oral cavity can impair communication on its own, drooling can damage communication aids and electronics such as tablets and computers, thus further hampering adjunctive measures of engagement for drooling patients [7]. Medical complications include skin excoriation and breakdown, yeast infections, aspiration, pneumonia, and feeding impairment.

While the following causes of increased salivary production do not typically result in true sialorrhea, they are diagnoses that should be considered during evaluation. Parasympathomimetic drugs as pilocarpine or bethanechol, which act as acetylcholine receptor agonists at the neuroglandular junction, can lead to an increase in saliva

production. This can also occur in patients taking certain atypical antipsychotic, particularly clozapine. Sialorrhea gravidarum is the term used to describe the increase in saliva production seen during pregnancy. This condition occurs more frequently when pregnancy is complicated by hyperemesis gravidarum. Unlike the abovementioned causes of hypersalivation, frank drooling is a hallmark of poisoning by organophosphate insecticides, which irreversibly block acetylcholinesterase [8].

Patient Evaluation

Despite the existence of multiple methods for assessing the severity of drooling and the efficacy of treatments, a standardized means does not exist. Both objective and subjective measures have been proposed, each with their own advantages and limitations.

Objective measures generally involve measuring the actual volume of drool or directly observing the number of drooling episodes in a given time frame. Ekedahl reported on the use of radio-labeled isotopes measured in drooled saliva [9]. Various collection devices have also been employed, including suction bags and a cuplike device held against the chin by straps attached to orthodontic headgear [10]. Other approaches have included weighing bibs and absorbent cotton dental rolls. All of these methods are cumbersome, labor intensive, and prone to imprecision as leakage, and incomplete collection occurs frequently [11].

Reddihough et al. proposed a semiquantitative observational method known as the drooling quotient (DQ) [12, 13]. In his modification of the original DQ published by Rapp in 1988, direct monitoring for the presence or absence of drooling every 15 s over a 10-min period is performed on two separate occasions. The results of the two sessions are then averaged and expressed as the percentage of observed drooling episodes out of a total of 40. Although a truncated version of the DQ has been shown to be an equally reliable measure of drooling severity, it remains time-consuming and not possible with every patient

[14]. Additionally, drooling severity is known to vary with different daily life situations [11], which raises concerns as to whether the findings over a short period of time are an accurate representation of disease severity.

Questionnaire-based, subjective measures of sialorrhea attempt to describe the impact of drooling and the effects of subsequent treatment on the patient and their caregivers. Because the ultimate goal of treatment is to provide a quality of life benefit to the patient and his or her family, a 1990 consortium on the management of drooling concluded that objective quantification of drooling was not necessary to establish treatment effectiveness [15]. While most sialorrhea research relies heavily on such subjective measures, there is still no consensus as to which scale should be employed.

The most commonly used subjective scales are the Drooling Frequency and Severity Scale (DFSS, Table 17.1) [16, 17] and the Teacher's Drooling Scale (TDS, Table 17.2) [18]. Recently, a strong association was found when comparing the subjective DFSS and the objective DQ, which suggests that the DFSS can reliably be used for clinical guidance instead of more time-consuming DQ [19].

Table 17.1 The Drooling Frequency and Severity Scale (DFSS)

<i>Drooling severity</i>	<i>Grade</i>
Dry (never drools)	1
Mild (only lips wet)	2
Moderate (lips and chin wet)	3
Tremendous (clothes wet)	4
Profuse (hands, clothes, and objects wet)	5
<i>Drooling frequency</i>	<i>Grade</i>
Never drools	1
Occasionally (not every day)	2
Frequently (part of every day)	3
Constant (always wet)	4

Table 17.2 The Teacher's Drooling Scale

Grade	Symptom severity
1	No drooling
2	Infrequent drooling, small amounts
3	Occasional drooling, intermittent all day
4	Frequent drooling but not profuse
5	Constant drooling, always wet

Treatment

A multidisciplinary approach involving speech therapy, occupational therapy, neurology, dentistry, and otolaryngology is often required to treat this vexing clinical problem. The underlying issues are frequently chronic and occasionally progressive. As saliva has multiple physiologic properties, there exists a fine line between adequately controlling sialorrhea and inducing xerostomia and its detrimental effects such as increased dental caries and worsened dysphagia. For these reasons, treatment should be tailored to each patient depending on the severity of the condition, the ability to take oral nutrition, and patient preference. Often a stepwise approach beginning with the least invasive treatment option is prudent.

Physiotherapy and Neuromuscular Reeducation

Oral motor therapy, which is typically performed by speech therapy, targets the musculature that generates suction and improves anterior oral seal and lip closure [20]. Behavior modification techniques can increase sensory awareness and voluntary swallowing. These approaches are time-consuming, associated with a significant relapse rate, and therefore only suited for highly motivated, cooperative patients [21].

Systemic Pharmacotherapy

Anticholinergic drugs are the medication of choice among systemic therapies for sialorrhea. The use of such medicines does not correct the underlying neuromuscular issues that lead to the condition, but rather aims to reduce the overall volume of saliva to manageable levels. Common medications used in the treatment of sialorrhea include atropine, scopolamine (hyoscine), and glycopyrrolate. Unfortunately, several adverse effects including irritability, hyperactivity, xerostomia, urinary retention, and constipation limit the use of these medications.

Atropine can be administered sublingually and has been shown to be effective in reducing drooling in several patient populations, including Parkinson's disease and clozapine-induced sialorrhea [22, 23].

Scopolamine is most often delivered transdermally and is typically used to treat motion sickness. The use of this medication in the treatment of drooling leverages the drug's most common side effect, dry mouth.

Glycopyrrolate, a synthetic muscarinic receptor antagonist, is perhaps the most commonly used systemic drug to treat sialorrhea. One benefit of this drug over other anticholinergic drugs is that it works primarily at peripheral receptors. It does not cross the blood-brain barrier and thus has relatively few central effects [24]. The primary adverse effects were dry mouth (9–41%), constipation (9–39%), and behavioral changes (18–36%) [25]. The first double-blind, placebo-controlled prospective trial to investigate glycopyrrolate in neurologically impaired children was done by Mier et al. in 2000 [26]. In this study, 69% of patients experienced adverse effects related to the drug, 21% of which withdrew from the study. Statistically significant improvement in drooling was noted in all patients that completed the study, an effect that was dose dependent. In 2010, an oral solution was FDA approved for the treatment of sialorrhea in neurologically impaired children ages 3–16 [27].

Botulinum Toxin

Botulinum toxin (BoNT) is a potent neurotoxin produced by the bacterium *Clostridium botulinum*. By inhibiting the synaptic release of acetylcholine from preganglionic neurons into the synaptic cleft, cholinergic parasympathetic input to the salivary glands can be effectively blocked. Based on the current data, the injection of botulinum toxin into the salivary glands is generally considered the most effective pharmacologic means to treat sialorrhea [28, 29].

The first report of the clinical benefit of BoNT for the treatment of drooling was in patients with amyotrophic lateral sclerosis [30]. Since that time, many studies, including 14 randomized

controlled trials, have investigated BoNT type A and BoNT type B in adult and pediatric populations [31]. Roughly half of all studies utilized ultrasound guidance during injections, while the remainder relied on anatomical landmarks alone (Fig. 17.1). All studies have confirmed the efficacy of BoNT for the treatment of sialorrhea, with reported rates of response ranging from 40 to 100% [31]. A review of roughly 1200 injections utilizing botulinum toxin A found that approximately 10% of patients did not respond, regardless of dosage [32].

The duration of treatment effect ranges from 2 to 36 weeks [33, 34]. Petracca et al. observed that age was an independent predictor of duration of effect, with older age being significantly associated with longer duration of benefit. A similar association has been reported in the pediatric population [35]. Given the temporary nature of the treatment and the need for repeat injections, it is also important to note that treatment efficacy does not appear to diminish over time. In a review of 65 patients treated with repeat BoNT injections over the course of 8 years, failure was seen in only 11% [31].

Currently, there is no consensus on the optimal type of BoNT, the dose and dilution, the number of sites injected per gland, or the need for ultrasound guidance (Fig. 17.1). There is, however, strong evidence to support the effectiveness of onabotulinumtoxinA (BOTOX®; Allergan, Inc.), abobotulinumtoxinA (Dysport®; Ipsen Biopharm Ltd.), and rimabotulinumtoxinB

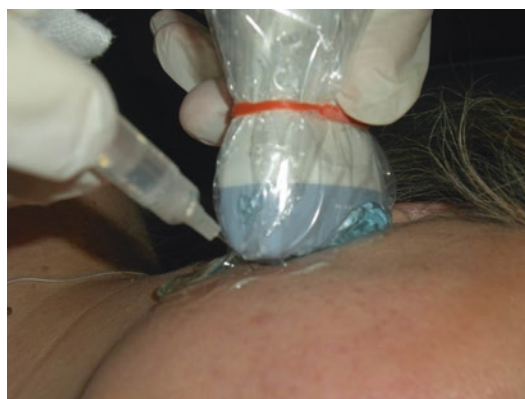

Fig. 17.1 Ultrasound can be used to guide injection of botulinum toxin into the salivary glands (Image courtesy of M. Boyd Gillespie)

(Myobloc®; Solstice Neurosciences, Inc.) in the treatment of sialorrhea. While incobotulinumtoxinA (Xeomin®; Merz Pharma GmbH & Co. KGaA) is likely effective as well, no blinded studies have been performed to date. Despite the submandibular gland being the primary producer of saliva at rest, there is increasing evidence that control of sialorrhea is significantly better when both the submandibular and parotid glands are injected [33].

Surgical Interventions

Surgery is indicated for the treatment of sialorrhea when the condition is severe, conservative measures have failed, or the patient desires a more permanent solution. Despite the availability of effective therapies such as the injection of BoNT, up to 70% of patients suffering from severe drooling are referred for surgical treatment [33]. Many different procedures have been advocated, and all generally involve a combination of gland removal, duct ligation, or duct relocation to address the submandibular glands alone or with the parotid glands.

At present, there is considerable debate about the most effective surgical procedure to treat sialorrhea. A meta-analysis of the surgical management of drooling by Reed et al. in 2009 reviewed 50 articles and found an overall subjective success rate of 81.6%. Bilateral relocation of the submandibular duct was the most commonly studied procedure, accounting for 36% of all studies, and had an average subjective success of 84.4%. This was done in conjunction with excision of the sublingual glands in another 14% of studies reviewed. On the other hand, only four studies evaluated four-duct ligation, which had the lowest average success at 64.1% [36].

Bilateral Submandibular Gland Excision with Parotid Duct Ligation or Relocation

The first surgery for the treatment of drooling was bilateral parotid duct relocation (B-PDR) [37]. As this resulted in limited success, it was

later combined with bilateral resection of the submandibular glands (B-SMGE) [38]. This approach has been the focus of at least ten studies and has been associated with an 88% subjective success rate [36]. Almost equally studied is B-SMGE in conjunction with bilateral parotid duct ligation (B-PDL). Although technically easier to perform, it is still associated with 85% subjective success [36]. A notable study by Faggella and Osborn highlighted the fact that both sides do not have to be treated with the same technique. They evaluated the outcomes of B-SMGE in combination with either B-PDR, B-PDL, or right PDL and left PDL and concluded that the results of the combination procedure were preferable to treating both parotid ducts with relocation or ligation. This was due to the fact that they saw more complications in the B-PDR group and significantly thicker saliva with xerostomia in the B-PDL group [39].

It is important to note that relocation of the parotid duct can result in significant postoperative complications including edema of the cheek, pain, and dysphagia [40]. Wilkie also reported parotid ductal stenosis or cyst formation in 20% of patients [38]. On the other hand, ligation of the parotid duct can be associated with swelling of the parotid gland as well as pain, though no study has specifically assessed the severity of these complications. Lastly, complications that can be seen with submandibular gland excision include a cervical scar, marginal mandibular nerve weakness (18%), lingual nerve paresthesia (4%), and hemorrhage (1%) [41].

Bilateral Submandibular Duct Relocation

Relocation of the submandibular ducts to the tonsillar fossae was first described by Ekedahl in 1974 [42]. In the original study, 99 mTc isotope salivary gland uptake scanning confirmed that function was maintained after duct relocation. Currently bilateral submandibular duct relocation with or without resection of the sublingual gland accounts for nearly half of all studies on the surgical treatment of drooling and has a reported 71–85% subjective success rate. It is important to

note that relocation of the submandibular duct to the oropharynx is contraindicated in patients who experience posterior and anterior drooling. Such patients often have severe dysphagia, placing them at higher risk for aspiration and subsequent pneumonia. With respect to the sublingual gland, Crysdale advocated concurrent removal due to a relatively high incidence of ranula formation when it is left in place [43]. More recent studies that have adopted this practice report no occurrences of ranula formation [44–46]. Advocates of this technique report that it is well tolerated, preserves saliva for physiologic functions, and is not associated with painful gland-like duct ligations.

Four-Duct Ligation

The objective of any procedure that utilizes duct ligation is to induce salivary atrophy secondary to iatrogenic obstruction. The first study of four-duct ligation was done by Klem and Mair in 1999, in which they achieved a 100% success rate in five patients treated with the technique [47]. They concluded it was quick, effective, simple to perform, and associated with minimal morbidity (Fig. 17.2). The technique was developed in an effort to avoid complications seen with existing procedures. Four subsequent studies with a total of 100 patients reported widely varying success rates ranging from 31 to 93% [48–51].

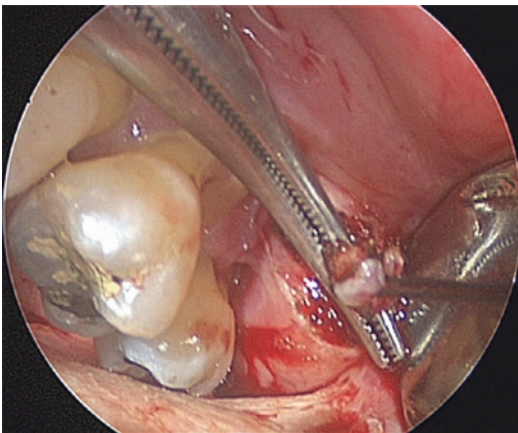


Fig. 17.2 Parotid duct ligation (Image courtesy of M. Boyd Gillespie)

Symptomatic facial swelling is reported in approximately 30% of patients [51]. Shirley et al. reported that 25% of patient families indicated they would not undergo the procedure again if given the chance. The reasons given were excessive postoperative pain and the need to undergo additional surgery to treat a ranula and chronic submandibular sialadenitis [48]. It is notable that none of the studies specifically quantify the pain and swelling that occurs with this procedure—a specific concern of opponents of this procedure. Furthermore, four-duct ligation has only been evaluated in neurologically impaired children, many of whom are nonverbal or minimally verbal, and may not be able to adequately report any discomfort they experience.

Neurectomy

Salivary production can be decreased through the interruption of the parasympathetic and sympathetic innervation of the parotid and submandibular glands. This can be accomplished by sectioning Jacobson's nerve and the chorda tympani via a transcanal tympanotomy approach. Success rates as high as 80% have been reported when bilateral sectioning of both the tympanic plexus (Jacobson's nerve) and the chorda tympani is performed. Results are significantly less favorable when only the chorda tympani nerves are sectioned, as this fails to address salivary production by the parotid glands [52]. Additionally, some authors report significant difference in results when a diligent search was conducted in order to ensure all branches of the tympanic plexus were severed [53]. Loss of taste in the anterior two thirds of the tongue is unavoidable, [54] and other potential complications include xerostomia, hearing loss, tympanic membrane perforation, and recurrence of drooling secondary to nerve regeneration. Due to these risks as well as controversial long-term results, [55] tympanic neurectomy is infrequently performed for sialorrhea.

A recent anatomic study looked at the feasibility of transoral submandibular ganglion neurectomy for the treatment of sialorrhea [56].

The authors reported that the ganglion was safely and reliably sectioned in 20 cadaver glands, without reports of injury to the lingual nerve or submandibular ganglion. While only a feasibility study, this technique demonstrates the continued evolution in the management of sialorrhea.

Radiation Therapy

Radiation therapy delivered to the salivary glands has been used to treat sialorrhea effectively. Doses ranging from 4 to 48 Gy have been reported with varying results. Perhaps the lowest dose reported to be effective was a single fraction of 7 Gy [57, 58]. Most other studies, however, report better outcomes with higher doses. Bourry et al. reported 78.6% success with doses above 16 Gy compares with 33% with doses below 16 Gy [59]. 20 Gy delivered in 4–5 fractions resulted in significant improvement of sialorrhea at the end of a 6-month follow-up period [60, 61]. Caution is advised when considering the use of ionizing radiation for the treatment of nonmalignant, particularly in younger patients with prolonged expected survival. Risks include inducing malignancy, delayed growth, mucositis, xerostomia, dental decay, and osteoradionecrosis [57]. Radiation therapy should be avoided in the pediatric population.

References

- Erasmus CE, Van Hulst K, Rotteveel LJ, et al. Drooling in cerebral palsy: hypersalivation or dysfunctional oral motor control? *Dev Med Child Neurol*. 2009;51:454–9.
- Holsinger FC, Bui DT. Anatomy, function, and evaluation of the salivary glands. In: Myers EN, Ferris RL, editors. *Salivary gland disorders*. Berlin: Springer; 2007. p. 1–16.
- Volonte MA, Porta M, Comi G. Clinical assessment of dysphagia in early phases of Parkinson's disease. *Neurol Sci*. 2002;23(Suppl 2):S121–2.
- Tahmassebi JF, Curzon MEJ. The cause of drooling in children with cerebral palsy—hypersalivation or swallowing defect? *Int J Paediatr Dent*. 2003;13:106–11.
- Hamdy S, Aziz Q, Rothwell JC, Hobson A, Barlow J, Thompson DG. Cranial nerve modulation of human cortical swallowing motor pathways. *Am J Physiol*. 1997;272:G802–8.
- van der Burg JJ, Jongerius PH, van Limbeek J, van Hulst K, Rotteveel JJ. Social interaction and self-esteem of children with cerebral palsy after treatment for severe drooling. *Eur J Pediatr*. 2006;165:37–41.
- Van der Burg JJ, Jongerius PH, Van Hulst K, Van Limbeek J, Rotteveel JJ. Drooling in children with cerebral palsy: effect of salivary flow reduction on daily life and care. *Dev Med Child Neurol*. 2006;48:103–7.
- Miranda-Rius J, Brunet-Llobet L, Lahor-Soler E, Farré M. Salivary secretory disorders, inducing drugs, and clinical management. *Int J Med Sci*. 2015;12:811–24.
- Ekedahl C, Hallen O. Quantitative measurement of drooling. *Acta Otolaryngol*. 1973;75:464–9.
- Sochaniwskyj AE. Drool quantification: noninvasive technique. *Arch Phys Med Rehabil*. 1982;63:605–7.
- Reid SM, Johnson HM, Reddihough DS. The drooling impact scale: a measure of the impact of drooling in children with developmental disabilities. *Dev Med Child Neurol*. 2010;52:e23–8.
- Reddihough D, Johnson H, Ferguson E. The role of a saliva control clinic in the management of drooling. *J Paediatr Child Health*. 1992;28:395–7.
- Rapp D. Management of drooling. *Dev Med Child Neurol*. 1988;30:128–9.
- van Hulst K, Lindeboom R, van der Burg J, Jongerius P. Accurate assessment of drooling severity with the 5-minute drooling quotient in children with developmental disabilities. *Dev Med Child Neurol*. 2012;54:1121–6.
- Blasco PA. Management of drooling: 10 years after the consortium on drooling, 1990. *Dev Med Child Neurol*. 2002;44:778–81.
- Thomas-Stonell N, Greenberg J. Three treatment approaches and clinical factors in the reduction of drooling. *Dysphagia*. 1988;3:73–8.
- Heine RG, Catto-Smith AG, Reddihough DS. Effect of antireflux medication on salivary drooling in children with cerebral palsy. *Dev Med Child Neurol*. 1996;38:1030–6.
- Camp-Bruno JA, Winsberg BG, Green-Parsons AR, Abrams JP. Efficacy of benztropine therapy for drooling. *Dev Med Child Neurol*. 1989;31:309–19.
- Rashnoo P, Daniel SJ. Drooling quantification: correlation of different techniques. *Int J Pediatr Otorhinolaryngol*. 2015;79:1201–5.
- Harris MM, Dignam PF. A non-surgical method of reducing drooling in cerebral-palsied children. *Dev Med Child Neurol*. 1980;22:293–9.
- Arvedson JC, Brodsky L. *Pediatric swallowing and feeding*. San Diego: Singular Publishing Group; 1993.
- Hyson HC, Johnson AM, Jog MS. Sublingual atropine for sialorrhea secondary to parkinsonism: a pilot study. *Mov Disord*. 2002;17:1318–20.
- Comley C, Galletly C, Ash D. Use of atropine eye drops for clozapine induced hypersalivation. *Aust N Z J Psychiatry*. 2000;34:1033–4.
- Mirakhor RK, Dundee JW. Comparison of the effects of atropine and glycopyrrolate on various end-organs. *J R Soc Med*. 1980;73:727–30.

25. Eiland LS. Glycopyrrolate for chronic drooling in children. *Clin Ther*. 2012;34:735–42.
26. Mier RJ, Bachrach SJ, Lakin RC, Barker T, Childs J, Moran M. Treatment of sialorrhea with glycopyrrolate: a double-blind, dose-ranging study. *Arch Pediatr Adolesc Med*. 2000;154:1214–8.
27. Zeller RS, Lee HM, Cavanaugh PF, Davidson J. Randomized phase III evaluation of the efficacy and safety of a novel glycopyrrolate oral solution for the management of chronic severe drooling in children with cerebral palsy or other neurologic conditions. *Ther Clin Risk Manag*. 2012;8:15–23.
28. Lim M, Mace A, Nouraei SA, Sandhu G. Botulinum toxin in the management of sialorrhoea: a systematic review. *Clin Otolaryngol*. 2006;31:267–72.
29. Lakraj AA, Moghimi N, Jabbari B. Sialorrhea: anatomy, pathophysiology and treatment with emphasis on the role of botulinum toxins. *Toxins*. 2013;5:1010–31.
30. Bushara KO. Sialorrhea in amyotrophic lateral sclerosis: a hypothesis of a new treatment—botulinum toxin a injections of the parotid glands. *Med Hypotheses*. 1997;48:337–9.
31. Petracca M, Guidubaldi A, Ricciardi L, et al. Botulinum toxin a and B in sialorrhea: long-term data and literature overview. *Toxicon*. 2015;107:129–40.
32. Daniel SJ. Multidisciplinary management of sialorrhea in children. *Laryngoscope*. 2012;122(Suppl 4):S67–8.
33. Suskind DL, Tilton A. Clinical study of botulinum—a toxin in the treatment of sialorrhea in children with cerebral palsy. *Laryngoscope*. 2002;112:73–81.
34. Jeung IS, Lee S, Kim HS, Yeo CK. Effect of botulinum toxin a injection into the salivary glands for sialorrhea in children with neurologic disorders. *Ann Rehabil Med*. 2012;36:340–6.
35. Khan WU, Campisi P, Nadarajah S, et al. Botulinum toxin a for treatment of sialorrhea in children: an effective, minimally invasive approach. *Arch Otolaryngol Head Neck Surg*. 2011;137:339–44.
36. Reed J, Mans CK, Brietzke SE. Surgical management of drooling: a meta-analysis. *Arch Otolaryngol Head Neck Surg*. 2009;135:924–31.
37. Wilkie TF. The problem of drooling in cerebral palsy: a surgical approach. *Can J Surg*. 1967;10:60–7.
38. Wilkie TF, Brody GS. The surgical treatment of drooling. A ten-year review. *Plast Reconstr Surg*. 1977;59:791–7.
39. Faggella RM, Jr., Osborn JM. Surgical correction of drool: a comparison of three groups of patients. *Plast Reconstr Surg*. 1983; 72:478–483.
40. Becmeur F, Schneider A, Flaum V, Klipfel C, Pierrel C, Lacreuse I. Which surgery for drooling in patients with cerebral palsy? *J Pediatr Surg*. 2013;48:2171–4.
41. De M, Adair R, Golchin K, Cinnamon MJ. Outcomes of submandibular duct relocation: a 15-year experience. *J Laryngol Otol*. 2003;117:821–3.
42. Ekedahl C. Surgical treatment of drooling. *Acta Otolaryngol*. 1974;77:215–20.
43. Crysdale WS, White A. Submandibular duct relocation for drooling: a 10-year experience with 194 patients. *Otolaryngol Head Neck Surg*. 1989;101:87–92.
44. Greensmith AL, Johnstone BR, Reid SM, Hazard CJ, Johnson HM, Reddihough DS. Prospective analysis of the outcome of surgical management of drooling in the pediatric population: a 10-year experience. *Plast Reconstr Surg*. 2005;116:1233–42.
45. McAloney N, Kerauwa CJ, Stassen LF. Management of drooling by transposition of the submandibular ducts and excision of the sublingual glands. *J Ir Dent Assoc*. 2005;51:126–31.
46. Hornibrook J, Cochrane N. Contemporary surgical management of severe sialorrhea in children. *ISRN Pediatr*. 2012;2012:364875.
47. Klem C, Mair EA. Four-duct ligation: a simple and effective treatment for chronic aspiration from sialorrhea. *Arch Otolaryngol Head Neck Surg*. 1999;125:796–800.
48. Shirley WP, Hill JS, Woolley AL, Wiatrak BJ. Success and complications of four-duct ligation for sialorrhea. *Int J Pediatr Otorhinolaryngol*. 2003;67:1–6.
49. Martin TJ, Conley SF. Long-term efficacy of intraoral surgery for sialorrhea. *Otolaryngol Head Neck Surg*. 2007;137:54–8.
50. Chanu NP, Sahni JK, Aneja S, Naglot S. Four-duct ligation in children with drooling. *Am J Otolaryngol*. 2012;33:604–7.
51. Khan WU, Islam A, Fu A, et al. Four-duct ligation for the treatment of Sialorrhea in children. *JAMA Otolaryngol Head Neck Surg*. 2016;
52. Grewal DS, Hiranandani NL, Rangwalla ZA, Sheode JH. Transtympanic neurectomies for control of drooling. *Auris Nasus Larynx*. 1984;11:109–14.
53. Mullins WM, Gross CW, Moore JM. Long-term follow-up of tympanic neurectomy for sialorrhea. *Laryngoscope*. 1979;89:1219–23.
54. Grant R, Miller S, Simpson D, Lamey PJ, Bone I. The effect of chorda tympani section on ipsilateral and contralateral salivary secretion and taste in man. *J Neurol Neurosurg Psychiatry*. 1989;52:1058–62.
55. Parisier SC, Blitzler A, Binder WJ, Friedman WF, Marovitz WF. Tympanic neurectomy and chorda tympanectomy for the control of drooling. *Arch Otolaryngol*. 1978;104:273–7.
56. Spock T, Hoffman HT, Joshi AS. Transoral submandibular ganglion neurectomy: an anatomical feasibility study. *Ann Otol Rhinol Laryngol*. 2015;124:341–4.
57. Borg M, Hirst F. The role of radiation therapy in the management of sialorrhea. *Int J Radiat Oncol Biol Phys*. 1998;41:1113–9.
58. Neppelberg E, Haugen DF, Thorsen L, Tysnes OB. Radiotherapy reduces sialorrhea in amyotrophic lateral sclerosis. *Eur J Neurol*. 2007;14:1373–7.
59. Bourry N, Guy N, Achard JL, Verrelle P, Clavelou P, Lapeyre M. Salivary glands radiotherapy to reduce sialorrhea in amyotrophic lateral sclerosis: dose and energy. *Cancer Radiother*. 2013;17:191–5.
60. Guy N, Bourry N, Dallel R, et al. Comparison of radiotherapy types in the treatment of sialorrhea in amyotrophic lateral sclerosis. *J Palliat Med*. 2011;14:391–5.
61. Assouline A, Levy A, Abdelnour-Mallet M, et al. Radiation therapy for hypersalivation: a prospective study in 50 amyotrophic lateral sclerosis patients. *Int J Radiat Oncol Biol Phys*. 2014;88:589–95.

Benjamin C. Tweel and Ricardo Carrau

Key Points

1. Frey syndrome is characterized by facial sweating, flushing, warmth, and pain provoked by eating.
2. Aberrant regeneration of injured parasympathetic fibers of the auriculotemporal nerve is the generally accepted mechanism of action for this phenomenon.
3. Frey syndrome most commonly presents as a sequela of parotidectomy and can be seen in the vast majority of postsurgical patients unless preventative surgical management is employed.
4. Surgical prevention and treatment involves creating a tissue barrier, autologous or exogenous, between the remaining parotid gland and the overlying skin flap.
5. Dermal injection of botulinum toxin is currently the standard medical therapy and has been shown to have near-universal success with a limited side effect profile.

B.C. Tweel, M.D.

Department of Otolaryngology—Head and Neck Surgery, Icahn School of Medicine at Mount Sinai, Annenberg 10th Floor, One Gustave L. Levy Place, Box 1189, New York, NY 10029-3136, USA
e-mail: benjamin.tweel@mountsinai.org

R. Carrau, M.D. (✉)

Department of Otolaryngology—Head and Neck Surgery, Wexner Medical Center at The Ohio State University, 320 West 10th Avenue, Starling-Loving Hall, B221, Columbus, OH 43210-1282, USA
e-mail: ricardo.carrau@osumc.edu

Introduction

History. Frey syndrome, also known as gustatory sweating or auriculotemporal syndrome, is an uncommon condition, but a common sequela of parotidectomy. The syndrome is characterized by sweating, skin flushing, warmth, and pain associated with eating. The generally accepted pathophysiology involves regeneration of parasympathetic nerve fibers following trauma, most commonly surgical.

Lucja Frey, for whom the syndrome is named, published a manuscript in 1923 describing the case of a Polish soldier who developed gustatory sweating and flushing after suffering a bullet wound to the parotid [1, 2]. Frey identified the auriculotemporal nerve as the mediator of the phenomenon, and for this reason, the eponym bears her name [2, 3]. Tragically, as an Eastern European Jewish physician, she was killed in the Holocaust [4]. Frey's description of these symptoms was not the first, however. A 1757 manuscript by Duphenix describes a patient with trauma to the parotid region, who may have later developed facial sweating associated with eating; however, controversy surrounds this case, as it has been argued that it in fact represented a salivary fistula [3, 5]. Baillarger, in 1853, offered a description of two patients who had undergone drainage of parotid abscesses and later developed gustatory sweating [6].

Prevalence. The societal prevalence of Frey syndrome is low, but among those having

undergone parotidectomy, the entity is common. There is controversy surrounding the true postoperative prevalence, with published rates ranging from 2 to 100% of patients having undergone parotidectomy [7–9]. Many of the reported rates, relying on subjective reporting, likely underestimate the true prevalence, as evidenced by the discrepancy between subjective and objective measures. Dulguerov et al. noted a subjective prevalence of 40–50% of post-parotidectomy patients after surgery, whereas objective tests were positive in around 80% [9]. Doubtless, many patients whose symptoms are mild or spatially limited fail to report gustatory sweating.

Compounding the challenge of assessing the true prevalence of Frey syndrome, symptoms may appear only after a substantial delay from the time of surgery. Symptoms typically appear within months of surgery, but a delay of several years is not uncommon [10], and gustatory sweating has been reported up to 14 years after surgery [11]. A study with a follow-up of fewer than several years will therefore understate the true postoperative prevalence.

It has been argued that, with such a high postoperative prevalence, Frey syndrome may be considered an expected consequence of parotidectomy, rather than a complication, albeit with a widely variable severity and quality of life impact [12]. Regardless, all reasonable efforts should be taken to minimize the impact of this phenomenon.

Anatomy and Mechanism

Anatomy. Secretomotor signals to the parotid gland are initiated in the inferior salivatory nucleus and are carried along the glossopharyngeal nerve (CN IX) (Fig. 18.1). These fibers traverse the middle ear as Jacobson's nerve, before reentering the temporal bone as the lesser superficial petrosal nerve. The lesser superficial petrosal nerve travels through the foramen ovale and synapses in the otic ganglion. From there, post-ganglionic parasympathetic secretomotor fibers travel with the auriculotemporal nerve, a branch of the mandibular division of the trigeminal nerve (V3), to innervate the parotid gland [13].

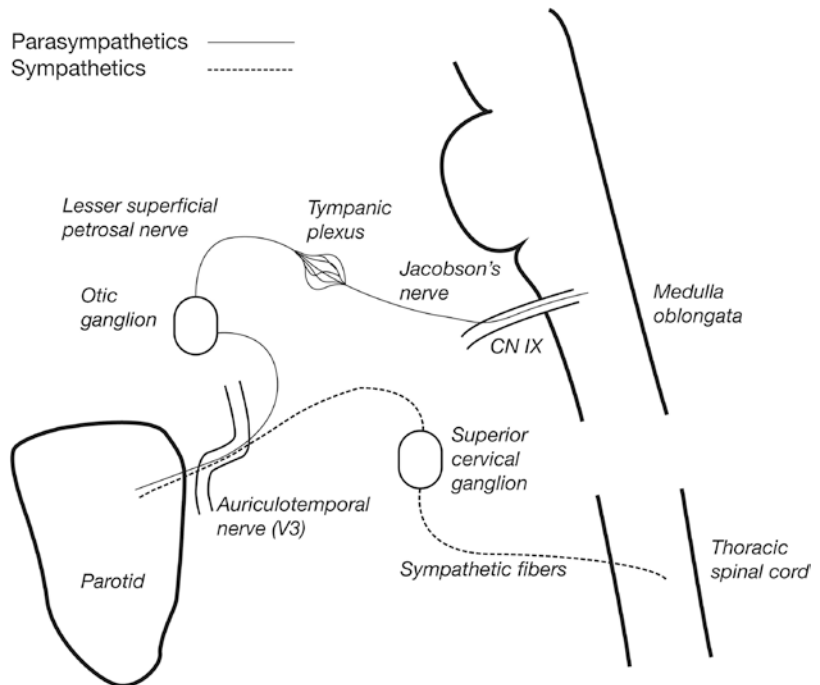


Fig. 18.1 Schematic of course of sympathetic and parasympathetic nerves involved in the development of Frey syndrome

Postganglionic sympathetic fibers depart from the superior cervical ganglion and eventually travel along the auriculotemporal nerve. These fibers control intraparotid vasoconstriction. Importantly, for the purposes of this discussion, these fibers also control vasoconstriction of the sweat glands in the skin overlying the parotid, which are mediated by acetylcholine release [13, 14].

Mechanism. Aberrant regeneration of transected postganglionic parasympathetic fibers in the auriculotemporal nerve is the generally accepted mechanism behind the development of Frey syndrome. As these transected fibers regenerate, they encounter the postsynaptic receptors in the sweat glands and vessel walls. As both sympathetic and parasympathetic fibers utilize the neurotransmitter acetylcholine at this synapse, parasympathetic signals result in a sympathetic response [13, 15]. Interestingly, acetylcholine may act directly on sweat glands, even without neural input [16]. The gustatory stimulus, which ordinarily stimulates salivary secretion, now initiates sweating and flushing. As the auriculotemporal nerve carries both fibers, and as the disruption of this nerve leads to this syndrome, the condition is also known as auriculotemporal syndrome.

A recent paper by Toure suggests the great auricular nerve as an alternative neural mediator for Frey syndrome, based on a series of anatomic dissections [17]. The nerve was discovered to have a substantial intraparotid component and frequently showed connections to the facial nerve or the auriculotemporal nerve. Other publications, however, have failed to find similar anatomic relationships between the great auricular nerve and the parotid gland [18]. In any case, the observation of gustatory sweating in distant locations such as the upper chest demonstrates that other nerves are capable of mediating this phenomenon.

Etiology

Localized trauma, typically surgery, in the periparotid region is responsible for nearly all cases of Frey syndrome. Parotidectomy is by far the single most common cause. Various publications

cite rates ranging from 2 to 100% in the postparotidectomy population [6–9], and it may be better thought of as an expected sequela of surgery instead of a complication. Aside from parotidectomy, a number of other surgeries have also been associated with the development of Frey syndrome. The first cases of gustatory sweating to enter the literature, prior the establishment of Frey's eponym, were associated with drainage of parotid abscesses, or other local traumas [3, 6]. Submandibular gland resection has been associated with gustatory sweating in the submandibular distribution [19, 20]. In addition, Frey syndrome has been reported after neck dissection [21], although this is a rare occurrence. Likewise, a case of gustatory sweating and flushing was reported following resection of a cervical lymphatic malformation [20]. Temporomandibular joint dislocation, mandibular condyle fractures, surgical approaches to the temporomandibular joint, and open and closed repair of condylar and subcondylar mandible fractures also pose a risk of development of this syndrome [22–26].

In the pediatric population, Frey syndrome may be mistaken for food allergy, which is understandable given the temporal association between food and symptom onset [27–31]. It has been posited that the underlying cause of Frey syndrome in these children is forceps delivery, although cases have been reported in children with no history of forceps delivery or other birth trauma [31–33]. In the remaining cases, the underlying pathophysiology has not been determined. In many cases, however, sweating is not associated, which suggests an entity that is different from the classical Frey syndrome [30].

Patients with severe diabetic neuropathy have been known to develop gustatory sweating [34, 35]. In one series, gustatory sweating was noted in six diabetic patients, all of whom had severe neuropathic symptoms elsewhere [34]. Shortly after eating, sweating was noted to occur in the face, neck, and upper chest. This was noted to correspond to the distribution of the superior cervical ganglion. The mechanism is therefore presumed to be severe neuropathy of the sympathetic fibers arising from the superior cervical ganglion [34].

Testing

Testing for Frey syndrome is generally reserved for investigational purposes, although providing quantitative measures of improvement may also be clinically useful. In the clinical setting, patient self-reporting may be the only necessary investigational method, as symptoms that are not noticed by patients need not be treated. A system for grading the severity of symptoms has been proposed [36], but this is not in wide usage.

The most widely employed test is Minor's starch-iodine test [37]. Classically, an iodine solution is applied to the skin and allowed to dry, following which powdered starch is placed over the area in question. A gustatory stimulus is given, and sweating is identified by the appearance of blue staining (Fig. 18.2). Single-step modifications that require the application of only a single layer of iodinated starch [38] or iodine-sublimated paper [9] have also been developed.

Minor's starch-iodine test is generally a qualitative assessment; however, it can also give topographic information. This has been proven useful in assessing the effect of topical treatments by measuring the stained area before and after intervention [39]. Furthermore, it may be useful for mapping the area of sweating for preoperative planning in a salvage setting [40].

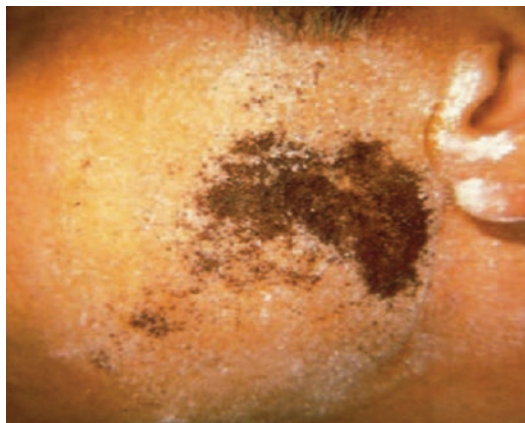


Fig. 18.2 Mapping of facial region of Frey syndrome using Minor's starch-iodine test (image courtesy of M. Boyd Gillespie)

A number of other publications have proposed alternative methods of quantifying the extent of Frey syndrome. Galvanic skin response, also known as sympathetic skin response, is a quantitative measure of the electrical conductivity of skin [41–43]. It has been employed in measuring hyperhidrosis as well as measuring the degree of neuropathy [42].

An alternative quantitative measure is infrared thermography, or medical thermography [44]. This technique measures changes in skin temperature in the area of interest and can be compared to the non-affected side. Temperature responses show a biphasic curve, with an initial warming due to flushing and vasodilation followed by cooling due to sweating [44]. Thermography has been shown to correlate with subjective symptoms, as well as to Minor's starch-iodine test [45].

A simple blotting paper technique has also been proposed [9]. In this test, blotting paper is placed over the affected area while the patient eats. The paper is weighed before and after placement to quantify the absorption of sweat.

Surgical Prevention and Treatment

A vast array of literature has attempted to define surgical techniques to prevent Frey syndrome as a sequela of parotidectomy. Surgical techniques rely on the idea of creating a barrier so that the regenerating parasympathetic nerve fibers do not reach the cutaneous sympathetic synapses. This barrier may be a thicker skin flap or tissue interposition, which may be performed in a preventative or therapeutic fashion.

Various authors have noted that thick skin flaps, or sub-SMAS skin flaps, are associated with a reduced incidence of Frey syndrome [46, 47], although this effect has not been universally repeatable and some studies have shown no decrease in postoperative Frey syndrome with a sub-SMAS skin flap [10, 48, 49]. Several authors have expanded on this approach by raising a separate SMAS flap, which is then replaced in the wound bed as a barrier [50–54]. Casler [51] as well as Allison [50] each showed a statistically significant decrease in postoperative Frey syndrome after SMAS interposition.

Free fascia lata grafting was initially proposed by Sessions in 1976 and again independently by Wallis in 1978, as a salvage procedure for patients who were suffering from post-parotidectomy Frey syndrome [55, 56]. Fat grafting has been widely employed intraoperatively, during parotidectomy, in order to provide improved facial contour after resection. A number of authors have noted a lower incidence of Frey syndrome after fat grafting or combined dermis-fat grafting [57–59]. A controlled study by Kim has shown that a parotidectomy with buccal fat grafting is superior to parotidectomy without barrier placement and seems equivalent to other autologous barriers with regard to prevention of gustatory sweating [60]. A 19-patient case series by Baum found no patients with Frey syndrome following the use of a combined dermal-fat grafting technique at a mean follow-up of 21 months [57].

Several reports have shown that usage of a temporoparietal flap as a barrier is efficacious in preventing [40, 61] or treating existing post-parotidectomy Frey syndrome [62]. Free temporalis fascia grafting has also been shown to be significantly beneficial in preventing Frey syndrome [63].

A sternocleidomastoid muscle (SCM) flap can be used as a barrier to prevent Frey syndrome and has the added benefit of improved facial contour. A number of authors have noted a reduced incidence of Frey syndrome with this flap versus controls [41, 51, 62, 64]. A 2013 meta-analysis by Liu et al. noted that sternocleidomastoid flaps consistently showed significant benefit versus no barrier; however, the analysis concluded that a significant publication bias was present and that the finding of benefit should be taken with appropriate caution [65]. A 2012 meta-analysis by Sanabria failed to conclude that the SCM flap was a significantly beneficial intervention; however, this was felt to be due to variability among trials and generally poor statistical power [66]. Nonetheless, no significant increase in complications was noted among the SCM flap groups in the Sanabria meta-analysis.

In addition to autologous flaps and grafts, a number of exogenous materials have been employed as barriers for the prevention of Frey

syndrome. Acellular dermal matrix (ADM) has been widely studied as an exogenous barrier material, and several meta-analyses have concluded that ADM is effective in reducing Frey syndrome [67–69]. A meta-analysis by Zeng, in 2012, demonstrated an 85% relative reduction in objective Frey syndrome with ADM usage, as well as a reduction in the rate of salivary fistula [68]. These meta-analyses did not demonstrate an increased risk of complications using ADM. A 2001 paper by Govindaraj showed a significant reduction in objective Frey syndrome in patients who received ADM when compared with controls [70]. However, this study did note an increase in complication rate in the ADM group (25%) compared with controls (9%). All of the complications were seromas, with the exception of one wound infection in the ADM group.

A multitude of other exogenous implants have been reported with variable degrees of benefit, including oxidized regenerated cellulose [7], irradiated animal pericardium [71], lyophilized dura [9], polyglactin 910 and polydioxanone mesh (Ethisorb, Johnson & Johnson, New Brunswick, NJ) [9], and expanded polytetrafluoroethylene (e-PTFE) [9]. Of these, oxidized regenerated cellulose and irradiated animal pericardium have not been thoroughly studied for this purpose, although early reports may show some benefit [7, 71]. Dulguerov published a study comparing no implant versus three types of exogenous implants (either lyophilized dura, Ethisorb, or e-PTFE), selected by surgeon preference [9]. Overall, the implant group demonstrated a significantly reduced incidence of Frey syndrome. Only 1 of 39 patients in the implant group had subjective Frey syndrome, compared with 11 of 21 patients in the no implant group. Objective testing also showed a significant reduction in the implant group. The paper, however, noted an increase in salivary fistula among the implant group compared with controls, including four out of seven patients with Ethisorb implants. While exogenous implants do provide a benefit in reduction of Frey syndrome, this benefit should be weighed against the reported increase in complication rates with exogenous implants.

Prior to the development of the above procedures, a number of other surgical procedures have been explored for symptom relief, although the following are largely of historical interest. Sectioning of the auriculotemporal nerve showed some benefit, at the risk of facial nerve injury. Sectioning of the chorda tympani has also been performed for this purpose. Most importantly, tympanic neurectomy had wide support as a definitive therapy, relieving symptoms in the majority of patients [13].

Medical Treatment

Symptomatic relief has been achieved with a number of medical therapies. Anticholinergics, applied topically, have demonstrated success in the past. Topical scopolamine was the first of this class to be widely used for this purpose, but with the cost of substantial systemic side effects, which proved too significant to justify continued usage [5, 13]. Anticholinergic symptoms such as dry mouth and urinary retention can be common with this medication, but furthermore, scopolamine readily crosses the blood-brain barrier, which could lead to hallucinations if excessive absorption were to occur [13]. Hays showed that a 0.5–1.0% topical glycopyrrolate solution was effective in controlling gustatory sweating for several days after a single application [13], and other authors have corroborated this finding [72, 73]. 2% diphemanil methylsulfate, a topical anticholinergic, has also been shown to provide 2–4 day relief of symptoms, with only dry mouth reported as an adverse effect [74].

Antiperspirants have also shown some efficacy in controlling symptoms. Black and Gunn reported a series of patients who showed consistent benefit from usage of topical aluminum chloride hexahydrate, the presumed mechanism of which was blockage of sweat ducts [75]. In their report, patients reported symptom relief with topical application with frequencies that range widely from 2 to 50 days. Other authors have likewise shown aluminum-containing antiperspirants to reduce the severity of gustatory sweating [5, 39].

Botulinum toxin A was first proposed for use in Frey syndrome by Drobik and Laskawi in 1995 [76]. Since then, it has come into wide use as the most effective means for long-term symptom control, and intradermal injection of botulinum toxin has essentially replaced the other medical therapies [5, 77]. Botulinum toxin works by blocking presynaptic release of acetylcholine and thus prevents postsynaptic flushing and sweating responses [15]. In contrast to other usages of botulinum toxin, which provoke voluntary muscle chemodenervation, intradermal injection for Frey syndrome can provide extended relief of symptoms, with reports of average duration of effect of over 6 months [6], 17 months [78], and over 18 months [79]. While patients may require multiple injections, eventual sweat gland atrophy renders continual injections unnecessary [80, 81]. Adverse side effects such as facial weakness are rare [79, 82, 83].

To employ botulinum toxin to this end, a map of the affected area is created, typically by starch-iodine identification [82]. A meta-analysis by Xie in 2015 recommended an interinjection distance of 1–2 cm, an injection volume of 0.1 mL per site, and a concentration of 2–5 U/mL [83]. In their investigation, 98.5% of patients benefited, while 3.6% of patients suffered complications limited to dry mouth and temporary muscle weakness lasting less than 3 months.

References

1. Frey L. Le syndrome du nerf auriculo-temporal. *Rev Neurol.* 1923;2:97–104.
2. Jacobsen N, Hopkins C. The bullet that hit a nerve: the history of Lucja Frey and her syndrome. *J Laryngol Otol.* 2006;120(3):178–80.
3. Dulguerov P, Marchal F, Gysin C. Frey syndrome before Frey: the correct history. *Laryngoscope.* 1999;109(9):1471–3.
4. Moltrecht M, Michel O. The woman behind Frey's syndrome: the tragic life of Lucja Frey. *Laryngoscope.* 2004;114(12):2205–9.
5. Clayman MA, Clayman SM, Seagle MB. A review of the surgical and medical treatment of Frey syndrome. *Ann Plast Surg.* 2006;57(5):581–4.
6. Baillarger M. Mémoire sur l'oblitération du canal Sténon. *Gazette Médicale de Paris.* 1853;23:194–7.

7. Singh N, Kohli M, Kohli H. Innovative technique to reduce incidence of Frey's syndrome after parotid surgery. *Am Surg*. 2011;77(3):351–4.
8. Gooden EA, Gullane PJ, Irish J, Katz M, Carroll C. Role of the sternocleidomastoid muscle flap preventing Frey's syndrome and maintaining facial contour following superficial parotidectomy. *J Otolaryngol*. 2001;30(2):98–101.
9. Dulguerov P, Quinodoz D, Cosendai G, Piletta P, Marchal F, Lehmann W. Prevention of Frey syndrome during parotidectomy. *Arch Otolaryngol Head Neck Surg*. 1999;125(8):833–9.
10. Lafont M, Whyte A, Whyte J, Saura E, Tejedor MT. Frey syndrome: factors influencing the time to event. *Int J Oral Maxillofac Surg*. 2015;44(7):834–9.
11. Wenzel GI, Draf W. Unusually long latency before the appearance of Frey's syndrome after parotidectomy. *HNO*. 2004;52(6):554–6.
12. Shuman AG, Bradford CR. Ethics of Frey syndrome: ensuring that consent is truly informed. *Head Neck*. 2010;32(8):1125–8.
13. Hays LL. The Frey syndrome: a review and double blind evaluation of the topical use of a new anticholinergic agent. *Laryngoscope*. 1978;88(11):1796–824.
14. Hansen JT, Koeppen BM, Netter FH. Netter's atlas of human physiology. Teterboro: Icon Learning Systems; 2002.
15. Kreyden OP, Scheidegger EP. Anatomy of the sweat glands, pharmacology of botulinum toxin, and distinctive syndromes associated with hyperhidrosis. *Clin Dermatol*. 2004;22(1):40–4.
16. Kahn D, Rothman S. Sweat response to acetylcholine. *J Invest Dermatol*. 1942;5(6):431–44.
17. Toure G. Intraparotid location of the great auricular nerve: a new anatomical basis for gustatory sweating syndrome. *Plast Reconstr Surg*. 2015;136(5):1069–81.
18. Zohar Y, Siegal A, Siegal G, Halpern M, Levy B, Gal R. The great auricular nerve; does it penetrate the parotid gland? An anatomical and microscopical study. *J Craniomaxillofac Surg*. 2002;30(5):318–21.
19. Teague A, Akhtar S, Phillips J. Frey's syndrome following submandibular gland excision: an unusual postoperative complication. *ORL J Otorhinolaryngol Relat Spec*. 1998;60(6):346–8.
20. Islam S, Hoffman GR. Two rare causes of Frey syndrome. *J Maxillofac Oral Surg*. 2010;9(1):107.
21. Graham RM, Baldwin AJ. An unusual cause of Frey syndrome. *Br J Oral Maxillofac Surg*. 2009;47(2):146–7.
22. Bouchard C, Perreault MH. Postoperative complications associated with the retromandibular approach: a retrospective analysis of 118 subcondylar fractures. *J Oral Maxillofac Surg*. 2014;72(2):370–5.
23. Bulut E, Bekçioğlu B. Delayed Frey syndrome after closed treatment of condylar fracture. *J Craniofac Surg*. 2012;23(4):e308–11.
24. Kragstrup TW, Christensen J, Fejerskov K, Wenzel A. Frey syndrome—an underreported complication to closed treatment of mandibular condyle fracture? Case report and literature review. *J Oral Maxillofac Surg*. 2011;69(8):2211–6.
25. Sverzut CE, Trivellato AE, Serra EC, Ferraz EP, Sverzut AT. Frey's syndrome after condylar fracture: case report. *Braz Dent J*. 2004;15(2):159–62.
26. Kamath RA, Bharani S, Prabhakar S. Frey's syndrome consequent to an unusual pattern of temporomandibular joint dislocation: case report with review of its incidence and etiology. *Craniofac Trauma Reconstr*. 2013;6(1):1–8.
27. González-Mendiola R, Sánchez-Fernández C, De la Hoz-Caballer B, Prieto-Montañó P, Muñoz-Martín T, García-González MC, Sánchez-Cano M. Auriculotemporal syndrome: differential diagnostic of food allergy. *Allergy*. 2003;58(12):1315.
28. Sánchez-Morillas L, Reaño Martos M, Rodríguez Mosquera M, Iglesias Cadarso A, Pérez Pimiento A, Domínguez Lázaro AR. Auriculotemporal nerve syndrome. *Allergol Immunopathol (Madr)*. 2003;31(5):288–90.
29. Karunanathan CG, Kim HL, Kim JH. An unusual case of bilateral auriculotemporal syndrome presenting to an allergist. *Ann Allergy Asthma Immunol*. 2002;89(1):104–5.
30. Dizon MV, Fischer G, Jopp-McKay A, Treadwell PW, Paller AS. Localized facial flushing in infancy. Auriculotemporal nerve (Frey) syndrome. *Arch Dermatol*. 1997;133(9):1143–5.
31. Sethuraman G, Mancini AJ. Familial auriculotemporal nerve (Frey) syndrome. *Pediatr Dermatol*. 2009;26(3):302–5.
32. Buyuktiryaki B, Sekerel BE. Is it food allergy or Frey syndrome? *J Allergy Clin Immunol Pract*. 2015;3(2):269–70.
33. Caulley L, Hong P. Pediatric auriculotemporal nerve (Frey) syndrome. *CMAJ*. 2013;185(6):504.
34. Watkins PJ. Facial sweating after food: a new sign of diabetic autonomic neuropathy. *Br Med J*. 1973;1(5853):583–7.
35. Freedman A. Facial sweating after food in diabetes. *Br Med J*. 1973;3(5874):291.
36. Luna-Ortiz K, Sansón-RíoFrío JA, Mosqueda-Taylor A. Frey syndrome. A proposal for evaluating severity. *Oral Oncol*. 2004;40(5):501–5.
37. Minor V. Eines neues verfahren zu der klinischen untersugung der schweissabsonderung. *Dtsch ZNervenheilk*. 1928;101:258–61.
38. Sato KT, Richardson A, Timm DE, Sato K. One-step iodine starch method for direct visualization of sweating. *Am J Med Sci*. 1988;295(6):528–31.
39. Chueasupparobon N, Rawangban W, Tangtaturonrasme N. Treatment of Frey's syndrome with topical ammonium alum: first report with twenty-two cases. *Clin Otolaryngol*. 2016;41(5):593–6.
40. Dai XM, Liu H, He J, Tu MS, Yu LF, Liu L. Treatment of postparotidectomy Frey syndrome with the interposition of temporalis fascia and sternocleidomastoid flaps. *Oral Surg Oral Med Oral Pathol Oral Radiol*. 2015;119(5):514–21.

41. Demirci U, Basut O, Noyan B, Demir UL, Afsin Ozmen O, Kasapoglu F, Hakan Coskun H, Onart S. The efficacy of sternocleidomastoid muscle flap on Frey's syndrome via a novel test: galvanic skin response. *Indian J Otolaryngol Head Neck Surg.* 2014;66(Suppl 1):291–8.
42. Vetrugno R, Liguori R, Cortelli P, Montagna P. Sympathetic skin response: basic mechanisms and clinical applications. *Clin Auton Res.* 2003;13(4):256–70.
43. Tuzemen G, Basut O, Ozmen OA, Coskun HH. Galvanic skin response test: a new quantitative diagnostic method for Frey syndrome. *J Craniofac Surg.* 2013;24(4):1280–4.
44. Isogai N, Kamiishi H. Application of medical thermography to the diagnosis of Frey's syndrome. *Head Neck.* 1997;19(2):143–7.
45. Choi HG, Kwon SY, Won JY, Yoo SW, Lee MG, Kim SW, Park B. Comparisons of three indicators for Frey's syndrome: subjective symptoms, minor's starch iodine test, and infrared thermography. *Clin Exp Otorhinolaryngol.* 2013;6(4):249–53.
46. Durgut O, Basut O, Demir UL, Ozmen OA, Kasapoglu F, Coskun H. Association between skin flap thickness and Frey's syndrome in parotid surgery. *Head Neck.* 2013;35(12):1781–6.
47. Singleton GT, Cassisi NJ. Frey's syndrome: incidence related to skin flap thickness in parotidectomy. *Laryngoscope.* 1980;90(10 Pt 1):1636–9.
48. Taylor SM, Yoo J, Matthews TW, Lampe HB, Trites JR. Frey's syndrome and parotidectomy flaps: a retrospective cohort study. *Otolaryngol Head Neck Surg.* 2000;122(2):201–3.
49. Taylor SM, Yoo J. Prospective cohort study comparing subcutaneous and sub-superficial musculoaponeurotic system flaps in superficial parotidectomy. *J Otolaryngol.* 2003;32(2):71–6.
50. Allison GR, Rappaport I. Prevention of Frey's syndrome with superficial musculoaponeurotic system interposition. *Am J Surg.* 1993;166(4):407–10.
51. Casler JD, Conley J. Sternocleidomastoid muscle transfer and superficial musculoaponeurotic system application in the prevention of Frey's syndrome. *Laryngoscope.* 1991;101(1 Pt 1):95–100.
52. Bonanno PC, Casson PR. Frey's syndrome: a preventable phenomenon. *Plast Reconstr Surg.* 1992;89(3):452–6; discussion 457–8.
53. Yu LT, Hamilton R. Frey's syndrome: prevention with conservative parotidectomy and superficial musculoaponeurotic system preservation. *Ann Plast Surg.* 1992;29(3):217–22.
54. de Ru JA, van Benthem PP, Bleys RL, Hordijk GJ. Prevention of Frey syndrome in parotid gland surgery. *J Otolaryngol.* 2007;36(5):291–5.
55. Roark DT, Sessions RB, Alford BR. Frey's syndrome—a technical remedy. *Ann Otol Rhinol Laryngol.* 1975;84(6):734–9.
56. Wallis KA, Gibson T. Gustatory sweating following parotidectomy: correction by a fascia lata graft. *Br J Plast Surg.* 1978;31(1):68–71.
57. Baum SH, Pfoertner R, Ladwein F, Schmeling C, Rieger G, Mohr C. Use of dermis-fat grafts in the prevention of Frey's syndrome after parotidectomy. *J Craniofac Surg.* 2016;44(3):301–8.
58. Balasundaram I, Nasser NA. Paraumbilical fat graft for the correction of contour deformity following parotidectomy and prevention of Frey syndrome. *Int J Oral Maxillofac Surg.* 2016;45(3):380–2.
59. Fasolis M, Zavattero E, Iaquinata C, Berrone S. Dermofat graft after superficial parotidectomy to prevent Frey syndrome and depressed deformity. *J Craniofac Surg.* 2013;24(4):1260–2.
60. Kim JT, Naidu S, Kim YH. The buccal fat: a convenient and effective autologous option to prevent Frey syndrome and for facial contouring following parotidectomy. *Plast Reconstr Surg.* 2010;125(6):1706–9.
61. Sultan MR, Wider TM, Hugo NE. Frey's syndrome: prevention with temporoparietal fascial flap interposition. *Ann Plast Surg.* 1995;34(3):292–6; discussion 296–7.
62. Dai XM, Liu H, Li YS, Ji SG, Qin SH, Liu L. Prevention of Frey syndrome with temporal fascia flap in Parotidectomy. *Ann Plast Surg.* 2015;75(6):610–4.
63. Sharma R. Prevention of Frey syndrome with superficial temporal fascia interpositioning: a retrospective study. *Int J Oral Maxillofac Surg.* 2014;43(4):413–7.
64. Filho WQ, Dedivitis RA, Rapoport A, Guimarães AV. Sternocleidomastoid muscle flap preventing Frey syndrome following parotidectomy. *World J Surg.* 2004;28(4):361–4.
65. Liu DY, Tian XJ, Li C, Sun SS, Xiong YH, Zeng XT. The sternocleidomastoid muscle flap for the prevention of Frey syndrome and cosmetic deformity following parotidectomy: a systematic review and meta-analysis. *Oncol Lett.* 2013;5(4):1335–42.
66. Sanabria A, Kowalski LP, Bradley PJ, Hartl DM, Bradford CR, de Bree R, Rinaldo A, Ferlito A. Sternocleidomastoid muscle flap in preventing Frey's syndrome after parotidectomy: a systematic review. *Head Neck.* 2012;34(4):589–98.
67. Li C, Yang X, Pan J, Shi Z, Li L. Graft for prevention of Frey syndrome after parotidectomy: a systematic review and meta-analysis of randomized controlled trials. *J Oral Maxillofac Surg.* 2013;71(2):419–27.
68. Zeng XT, Tang XJ, Wang XJ, Li MZ, Guo Y, Huang W, Niu YM, Leng WD. AlloDerm implants for prevention of Frey syndrome after parotidectomy: a systematic review and meta-analysis. *Mol Med Rep.* 2012;5(4):974–80.
69. Wang W, Fan JC, Sun CJ, Chen Y, Zhao HW, Ma H, Li CH, Mi K, Liao J, Liu K, Liu JF, Zhu GQ, Li C. Systematic evaluation on the use of acellular dermis matrix graft in prevention Frey syndrome after parotid neoplasm surgery. *J Craniofac Surg.* 2013;24(5):1526–9.
70. Govindaraj S, Cohen M, Genden EM, Costantino PD, Urken ML. The use of acellular dermis in the prevention of Frey's syndrome. *Laryngoscope.* 2001;111(1 Pt 1):1993–8.

71. Gennaro P, Di Curzio P, Mitro V, Facchini A, Saponaro G, Cascino F, Amodeo G, Gabriele G, Ungari C. Use of irradiate animal pericardium membrane for prevention of Frey's syndrome after parotidectomy. *Eur Rev Med Pharmacol Sci*. 2013;17(4):548–51.
72. May JS, McGuirt WF. Frey's syndrome: treatment with topical glycopyrrolate. *Head Neck*. 1989;11(1):85–9.
73. Goldstein DS, Pechnik S, Moak J, Eldadah B. Painful sweating. *Neurology*. 2004;63(8):1471–5.
74. Laccourreye O, Bonan B, Brasnu D, Laccourreye H. Treatment of Frey's syndrome with topical 2% diphemanil methylsulfate (Prantal): a double-blind evaluation of 15 patients. *Laryngoscope*. 1990;100(6):651–3.
75. Black MJ, Gunn A. The management of Frey's syndrome with aluminium chloride hexahydrate antiperspirant. *Ann R Coll Surg Engl*. 1990;72(1):49–52.
76. Drobik C, Laskawi R. Frey's syndrome: treatment with botulinum toxin. *Acta Otolaryngol*. 1995;115(3):459–61.
77. Steffen A, Rotter N, König IR, Wollenberg B. Botulinum toxin for Frey's syndrome: a closer look at different treatment responses. *J Laryngol Otol*. 2012;126(2):185–9.
78. Laskawi R, Drobik C, Schönebeck C. Up-to-date report of botulinum toxin type A treatment in patients with gustatory sweating (Frey's syndrome). *Laryngoscope*. 1998;108(3):381–4.
79. Hartl DM, Julieron M, LeRidant AM, Janot F, Marandas P, Travagli JP. Botulinum toxin A for quality of life improvement in post-parotidectomy gustatory sweating (Frey's syndrome). *J Laryngol Otol*. 2008;122(10):1100–4.
80. Blitzer A, Sulica L. Botulinum toxin: basic science and clinical uses in otolaryngology. *Laryngoscope*. 2001;111(2):218–26.
81. de Bree R, Duyndam JE, Kuik DJ, Leemans CR. Repeated botulinum toxin type A injections to treat patients with Frey syndrome. *Arch Otolaryngol Head Neck Surg*. 2009;135(3):287–90.
82. Dulguerov P, Quinodoz D, Cosendai G, Piletta P, Lehmann W. Frey syndrome treatment with botulinum toxin. *Otolaryngol Head Neck Surg*. 2000;122(6):821–7.
83. Xie S, Wang K, Xu T, Guo XS, Shan XF, Cai ZG. Efficacy and safety of botulinum toxin type A for treatment of Frey's syndrome: evidence from 22 published articles. *Cancer Med*. 2015;4(11):1639–50.

Charley Coffey and Ryan Orosco

Key Points

1. Facial pain syndromes often present in the region of the salivary glands during chewing or swallowing and may therefore be confused with salivary gland disorders.
2. Trigeminal neuralgia is one of the most common etiologies of chronic facial pain.
3. Temporomandibular joint disorders (TMDs) commonly radiate to the parotid region and may worsen during chewing mimicking an obstructive salivary disorder.

Introduction

In the evaluation of patients presenting with symptoms suggestive of salivary disorders, it is critical to rule out other etiologies which may result in similar symptoms. This distinction may be challenging, as facial pain is not only one of the most common and bothersome symptoms affecting

patients with obstructive sialadenitis but also a prominent symptom of numerous non-salivary pathologies. This chapter will review a range of common and less common facial pain syndromes, with a goal of helping the provider distinguish between salivary and non-salivary etiologies of facial pain and related symptoms (Table 19.1).

Cranial Neuralgias

Although the trigeminal nerve is by far the most frequently implicated in facial pain syndromes, multiple cranial nerves may also be affected. The pain experienced with cranial neuralgias is usually very characteristic, including paroxysmal attacks with acute onset, intense but lasting only seconds, with an electric or lancinating quality [1]. The sensory distribution of the involved nerve or branches determines the location of pain. Additional symptoms or exam findings characteristic of the individual syndrome are frequently present and may help to narrow the differential diagnosis considerably.

Trigeminal Neuralgia

Although relatively rare in the general population, trigeminal neuralgia is one of the most common etiologies of chronic facial pain, with estimated annual incidence of 5–8 per 100,000

C. Coffey, M.D. F.A.C.S. (✉)
Division of Head and Neck Surgery,
Department of Surgery, University of California
San Diego Moores Cancer Center,
VA San Diego Healthcare, 200 W. Arbor Dr. #8895,
San Diego, CA 92103, USA
e-mail: coffey@ucsd.edu

R. Orosco, M.D.
Division of Head and Neck Surgery, Department of
Surgery, University of California San Diego,
9500 Gilman Dr, La Jolla, CA 92093, USA

Table 19.1 Comparison of symptomatology: sialadenitis and facial pain syndromes

Disorder	Etiology	Characteristics of pain			Description	Inciting factors	Other symptoms
		Location	Duration				
Submandibular sialadenitis	Ductal obstruction, autoimmune, radiation, infection	Submandibular neck; unilateral > bilateral	Seconds (onset), hours to days (chronic)		Sharp or electric attacks; +/- chronically sore	Meals, sialogogues	Swelling, purulence
Parotid sialadenitis	Ductal obstruction, dehydration, autoimmune, radiation, infection	Upper neck, jaw; unilateral > bilateral	Seconds (onset), hours to days (chronic)		Sharp or electric attacks; +/- chronically sore	Meals, sialogogues	Swelling, purulence
Trigeminal neuralgia	Neurovascular compression (primary); herpes zoster, MS, trauma, tumor (secondary)	Facial skin, eye, ear; 95% unilateral	Seconds to minutes; paroxysmal		Electric, shocking, lancinating, burning; severe	Light touch of trigger point(s), chewing, shaving, temperature	Lacrimation, vesicles (zoster), hypesthesia, facial spasm
Glossopharyngeal neuralgia	Neurovascular compression (primary); herpes zoster, MS, tumor (secondary)	Tonsil/pharynx, jaw, ear; most often unilateral	Seconds to minutes; paroxysmal		Electric, shocking, lancinating; mild to severe	Swallowing, coughing, chewing	Syncope, cough, hoarseness
Nervus intermedius neuralgia	Idiopathic; potentially neurovascular compression	Deep in the ear, EAC; may radiate; unilateral	Seconds to minutes; paroxysmal		Sharp, stabbing, shocking	Stimulation of EAC trigger point (touch, temperature)	Lacrimation, dysguesia
Temporomandibular joint pain	Osteoarthritis, trauma, behavioral factors, altered pain thresholds	Jaw, ear, temple, neck	Chronic (years)		Constant ache, fluctuating severity	Mastication, mandibular excursion	Crepitus, trismus, movement dysfunction, tenderness
Dental pain	Infection (caries, abscess, periodontal disease), trauma (cracked tooth syndrome, bruxism), idiopathic (atypical odontalgia)	Tooth, jaw, ear, neck	Acute to sub-acute		Baseline ache; sharp, focal episodes	Biting, temperature changes (cold foods/liquids)	Swelling, purulence
Eagle's syndrome	Elongated styloid process, stimulating afferents of CN V, VII, IX or X; often post-surgery	Pharynx, ear, neck, face, shoulder	Chronic (years)		Aching, throbbing, burning	Head turn, swallow, cold liquids; palpating pharynx	Dysphagia, globus, syncope
Persistent idiopathic facial pain	Idiopathic	Orofacial; ill-defined, not associated w/ sensory nerve distribution	Chronic, non-episodic		Mild, dull, nagging, aching; +/- sharp pain	Stress, depression	None
First bite syndrome	Parapharyngeal surgery resulting in disruption of parotid sympathetic innervation; onset days or weeks after surgery	Unilateral cheek, upper neck, jaw, or ear	Brief- seconds		Intense cramping pain	First bite of meal; worse with sialogogues; thoughts of food may trigger pain	None (though Horner's syndrome may also be present)

people [2, 3], or 15,000 cases per year in the United States, and lifetime prevalence estimate of 70 per 100,000 people [1, 4]. Women are affected slightly more frequently than men, and incidence increases with age, with peak incidence in the sixth and seventh decades [1].

Trigeminal neuralgia is characterized by pain affecting one or more sensory distributions of the ophthalmic (V1), maxillary (V2), or mandibular (V3) divisions of the fifth cranial nerve. Patients experience recurrent, unilateral pain which is usually brief, intense, and described as shock-like, electrical, or stabbing in nature [5]. Symptoms more frequently involve the mid and lower face (V2/V3) than the upper face [6]. Pain is triggered by innocuous stimuli, such that light touch stimulation of anatomic trigger zones may elicit paroxysms of pain (allodynia) in many patients. Onset of pain may be associated with shaving, brushing of teeth, smiling, or even changes in temperature, and patients often learn to avoid contact or movement which they associate with pain.

Because trigeminal neuralgia pain may be triggered by such actions as chewing, the subjective experience for some patients may be similar to that experienced by sialadenitis patients who experience onset of pain with eating, particularly as both afferent pain pathways may be mediated by mandibular nerve fibers. In addition to pain, a significant portion of trigeminal neuralgia patients will experience autonomic symptoms (31%) or sensory abnormalities (29%) such as hypesthesia, hyperesthesia, or paresthesias [6]. Some may also experience facial spasm during painful episodes [7].

The pathophysiology of trigeminal neuralgia is generally related to demyelination of trigeminal sensory fibers, usually centered at the nerve root entry zone adjacent to the pons [8]. Direct compression of the nerve root by adjacent vessels (most commonly the superior cerebellar artery) is thought to be the primary cause of axonopathy in up to 90% of cases [9–11]. The International Classification of Headache Disorders, 3rd edition, categorizes such cases related to neurovascular compression as *classical trigeminal neuralgia* and distinguishes this from all other

etiologies, which are grouped under the term *painful trigeminal neuropathy* [5].

The pain associated with classical trigeminal neuralgia is frequently severe, and may increase over time, resulting in significant psychosocial dysfunction, cognitive deficits, and quality of life impairment [12]. Etiologies of painful trigeminal neuropathy include herpes zoster (acute infection or postherpetic neuropathy), multiple sclerosis, trauma, or space occupying lesions such as meningioma or schwannoma. The nature and intensity of pain associated with painful trigeminal neuropathy varies greatly according to the underlying etiology. Patients affected with herpes zoster may experience significant burning or lancinating pain as well as cutaneous herpetic eruption in the territory of the affected trigeminal nerve branch, or branches [13]. Involvement of the ophthalmic division is much more common with herpetic disease than other types of painful trigeminal neuropathy, or classical trigeminal neuralgia [14]. Painful trigeminal neuropathy affects approximately 2–5% of patients with multiple sclerosis, and bilateral symptoms are much more common in the setting of MS (14%) than other trigeminal pain syndromes [15, 16]. Although it appears most likely that symptoms in these patients are primarily attributable to MS-related pontine plaques, it is possible that neurovascular compression may also play a contributing role [15]. An association between painful trigeminal neuropathy and use of interferon beta has been reported, similar to the association between interferon and primary headaches in MS patients, but it is unclear whether this relationship is causative [17, 18]. Patients with schwannomas arising from the trigeminal nerve most commonly present with painful neuropathy; however, these are very rare lesions, accounting for <0.4% of intracranial tumors [19].

Establishing a diagnosis of trigeminal neuralgia is based upon clinical criteria, including recurrent attacks of characteristic pain occurring unilaterally in one or more divisions of CN V, without sufficient evidence to support another diagnosis [5]. Patients meeting these criteria who have signs or symptoms suggestive of an etiology other than neurovascular compression

may be diagnosed with painful trigeminal neuropathy, as outlined above. Diagnostic imaging such as MRI may be useful in identifying the small minority of patients with a compressive space occupying lesion, demyelinating disease such as MS, or other structural cause, but will not contribute to the diagnosis in about 85% of cases [20]. Notably, although neuroimaging may demonstrate evidence of neurovascular compression in patients with classical trigeminal neuralgia, the absence of radiographic findings does not exclude the possibility of compression or potential benefit from microvascular decompression surgery [21].

The natural history of trigeminal neuralgia includes spontaneous resolution for greater than 50% of patients [1]. A number of medical therapies have been demonstrated to be effective, though caution must be exercised in evaluating therapy for any disorder with high rates of spontaneous resolution [20]. Multiple trials provide level I evidence for carbamazepine in the management of trigeminal neuralgia, demonstrating excellent pain control response in 58–100% of patients, as compared to 0–40% of patients on placebo [22–24]. There is also good evidence that oxcarbazepine, baclofen, and lamotrigine are frequently effective [25–27].

If medical therapy proves ineffective, there are multiple surgical options which may be considered. Ablative techniques target either the Gasserian ganglion or portions of CN V distal to the ganglion and may include cryotherapy, neurectomy, injection of alcohol or glycerol, balloon compression, or radiofrequency ablation. Peripheral interventions which target distal nerve segments have little morbidity, but are associated with recurrence of symptoms in 50% of patients after 1 year [20]. Longer-term benefit is associated with percutaneous procedures targeting the Gasserian ganglion via cannulation of foramen ovale. 68–85% of patients undergoing destruction of the ganglion by balloon compression, glycerol injection, or radiofrequency ablation will be pain-free at 1 year, and about 50% remain pain-free at 5 years [28–31]. Not surprisingly, these procedures also result in sensory deficits in nearly half of the patients [20].

Trigeminal neuralgia resulting from neurovascular compression may also be surgically addressed by microvascular decompression (MVD) via a posterior fossa craniotomy (Fig. 19.1). This non-ablative approach is associated with a higher long-term success rate than other interventions, without the sensory sequelae frequently experienced after ablative procedures.

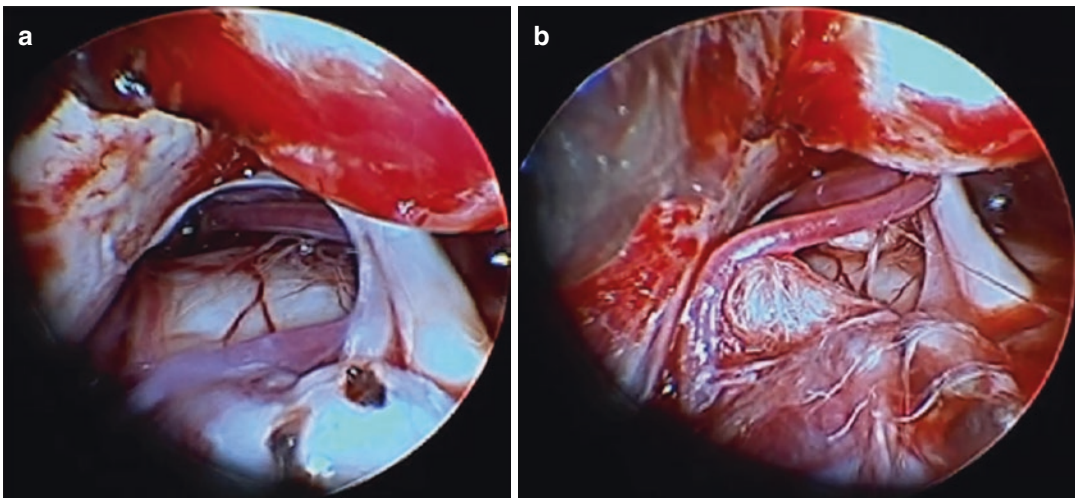


Fig. 19.1 Exposure via posterior fossa craniotomy demonstrates superior cerebellar artery impingement upon the nerve root of CN V (a). The arterial loop is repositioned,

with placement of shredded Teflon to eliminate points of contact between the vessel and nerve or brain stem (b) (images courtesy of Bob S. Carter, M.D., Ph.D.)

Ninety percent of patients undergoing MVD will experience pain relief, and over 70% will remain pain-free at 5 years [21, 32–34]. Although MVD is most frequently employed for patients with classical trigeminal neuralgia, it may also be successful for selected patients with painful trigeminal neuropathy related to MS or herpes zoster who have failed medical measures [33, 35]. Though rates of sensory deficits following MVD are low, this procedure is associated with serious complications that may be expected of an open intracranial approach, most notably, meningitis, CSF leak, infarct, hematoma, hearing loss, facial weakness, or diplopia. Interestingly, acute herpes zoster infection within trigeminal nerve distributions has also been reported shortly following MVD, which may be the result of viral reactivation due to manipulation of the nerve during surgery [36, 37]. Fortunately, this appears to be a rare occurrence. Mortality rates of up to 0.5% have been reported following MVD, though rates appear to be much lower at high-volume centers [38]. As an alternative to surgery, gamma knife radiation targeting the proximal trigeminal nerve root may be employed, with success rates of about 50% at 3 years [20].

Glossopharyngeal Neuralgia

Paroxysmal pain affecting regions innervated by the ninth and tenth cranial nerves is characteristic of glossopharyngeal neuralgia. This disorder is less commonly referred to as vagoglossopharyngeal neuralgia. Although glossopharyngeal neuralgia is the second most common painful cranial neuralgia, it is far more rare than trigeminal neuralgia, with an estimated incidence of 0.8 per 100,000 people [3].

Most instances of glossopharyngeal neuralgia are related to neurovascular compression by either the posterior inferior cerebellar artery or vertebral artery [39]. Pain is usually localized to the tonsil or base of the tongue, sometimes extending to the lower jaw or ear, and is almost exclusively unilateral [40]. Trigger zones are less identifiable than with trigeminal neuralgia, but trigger mechanisms such as swallowing, chew-

ing, coughing, and drinking cold liquids are frequently reported [40, 41]. Cutaneous trigger sites may also be present in the lateral neck, preauricular skin, or external auditory canal. The degree of pain associated with glossopharyngeal neuralgia is generally less severe than trigeminal neuralgia pain, as suggested based upon patient descriptions and the observation that affected patients often seem less inclined to pursue aggressive medical or surgical intervention [3, 41]. For patients who do experience pain triggered by swallowing, weight loss may be dramatic [40]. Numerous reports have described instances of bradycardia, syncope, and even asystole experienced during exacerbations of glossopharyngeal neuralgia [41–47]. It is speculated that intense vagal stimulation in these instances results from the spread of afferent impulses from the glossopharyngeal nerve to the dorsal motor nucleus of CN X [41, 45]. Similar albeit less severe vagal-mediated laryngeal symptoms may include paroxysmal cough and stridor [41].

Management of glossopharyngeal neuralgia is similar to that of trigeminal neuralgia. Medications such as carbamazepine, lamotrigine, baclofen, gabapentin, and pregabalin are variably effective [47, 48]. Surgical approaches to refractory glossopharyngeal neuralgia may include rhizotomy of the glossopharyngeal nerve roots and upper roots of CN X, or microvascular decompression of the nerve root entry zones [39, 43, 45]. For cases involving syncope, implantation of a temporary cardiac pacemaker may be required during the perioperative period, or prior to definitive surgery [43]. Long-term success rates of over 90% have been reported with microvascular decompression via a small retrosigmoid craniotomy, with low complication rates in high-volume centers [39, 49].

Nervus Intermedius Neuralgia

Nervus intermedius neuralgia, also known as geniculate neuralgia, is an extremely rare form of painful cranial neuralgia, with fewer than 150 cases reported in the English literature over a 70-year period [50]. It is speculated that

neurovascular compression at the root entry zone of the seventh and eighth cranial nerves may play a role, though the precise mechanism remains unknown. The character of the pain associated with nervus intermedius neuralgia is similar to that of other cranial neuralgias, namely, paroxysmal, intense, brief, and described as shooting, stabbing, or shocking. Nervus intermedius neuralgia is most uniquely distinguished by the location of pain, which is deep seated within the ear or external auditory canal, occasionally radiating to the temple, soft palate, or angle of the mandible [40, 50]. Pain may be triggered by touch or temperature stimulation of a trigger point within the auricle or ear canal. Additional symptoms may include disorders of lacrimation or gustatory sensation, and hemifacial spasm has been reported [51]. Anticonvulsant medications are frequently prescribed, though evidence for efficacy must be derived from reports on other painful cranial neuropathies or chronic neuropathic pain. Case reports and small series have reported transection of the nervus intermedius either at the brain stem or the geniculate ganglion and microvascular decompression at the nerve root entry zone [50]. Transection or regional block targeting the sensory auricular branch of the facial nerve may also provide a lower risk surgical alternative [52]. Of note, the International Classification of Headache Disorders, 3rd edition (ICHD-3), redefines Ramsay Hunt syndrome as “secondary nervus intermedius neuropathy attributed to acute Herpes zoster,” but the manifestations of Ramsay Hunt syndrome are much more broad than nervus intermedius neuralgia, and this syndrome will be considered separately for the purposes of this text [5].

Occipital Neuralgia

Occipital neuralgia is characterized by paroxysmal sharp pain in the posterior scalp, corresponding to sensory distribution of the greater or lesser occipital nerves. The majority of cases are related to cervical spine pathology, and idiopathic or primary cases are considered exceedingly rare [40].

Temporomandibular Joint Disorder

Temporomandibular joint disorders (TMDs) and TMD-related pain are very common, with an estimated prevalence of about 5% in the United States [53]. TMD pain affects women 3–4 times as often as men, and prevalence is roughly equivalent across the third to seventh decades.

As an encapsulated stress-bearing synovial joint, the temporomandibular joint (TMJ) is subject to the same issues that affect other such joints. TMD may be secondary to conditions affecting the joint capsule (degeneration, displacement, ankylosis, or trauma) or the associated connective tissues (myofascial pain, myositis, and fibromyalgia, among others). Current taxonomy includes 37 distinct disorders affecting the temporomandibular joint or surrounding tissues [54]. Pain is most often unilateral, but may be bilateral. The primary complaint of most patients (96%) with TMJ disorder is jaw pain. A significant portion of patients also report otalgia (82%), headache (79%), or TMJ dysfunction (75%) [55, 56]. TMJ pain frequently radiates to the temple, jaw, parotid region, or neck. The character of TMJ-related pain is usually described as a dull and persistent ache which fluctuates in intensity and is often worse in the morning. More acute, stabbing pain or otalgia may be associated with articular disc derangement [57]. Pain is often triggered by jaw motion with eating, yawning, or talking. Symptoms are most often unilateral, but may be bilateral in the setting of polyarthritis such as rheumatoid. Patients may report episodes of locking of the joint, most commonly with the inability to open the mouth. Clicking or popping is frequently present, but this is also common in the absence of TMJ dysfunction or pain.

The etiology of TMJ disorder is likely multifactorial, and the underlying cause remains uncertain for many patients [58]. Evidence of TMJ osteoarthritis is present in 22–38% of autopsy specimens, but most patients with OA do not develop TMJ disorder [57]. Parafunctional habits such as bruxism or jaw clenching may exacerbate TMJ pain, but a causal relationship between this habits and TMD has not been

established. Malocclusion, trauma, and psychogenic factors may also be contributory. There is an association between TMJ pain and depression in women, but it is not clear based upon available evidence whether depressed women tend to develop TMD or patients affected by TMD tend to develop depression [59]. There is evidence to suggest that pain thresholds or pain modulatory mechanisms may be different in TMD patients compared to unaffected controls [60].

Evaluation of TMD is primarily based upon history and physical exam. Pain associated with mastication is a cardinal feature, though it is important to recall that pain associated with jaw movement may also be present in trigeminal neuralgia. It is also important to distinguish mastication from the act of eating, as the latter, but not the former, is very commonly associated with obstructive sialadenitis. Tenderness overlying the TMJ joint or masseter is frequently present. The presence of crepitus or joint sounds should be noted, as well as trismus, malocclusion, or jerky motion with vertical mouth opening [57]. Plain film panoramic radiography may be used as a screening evaluation for degenerative changes in the glenoid fossa or mandibular condyle. Diagnostic imaging such as CT or MRI is usually reserved for more complex cases, where panoramic radiographs demonstrate abnormality or where the presentation is not classic for TMD.

Most cases of TMD are mild and self-limited. Patient education combined with conservative measures often provides adequate relief of pain. Patients should be educated regarding the nature of TMD and instructed regarding avoidance of triggers. Measures such as soft diet, nonsteroidal anti-inflammatory (NSAID) medications, compress, relaxation techniques, and stabilization via occlusal splints should be considered. Physical therapy is often employed, but the existing evidence evaluating physical therapy in TMD and TMJ pain is of limited quality [61]. Surgical interventions are reserved for patients with demonstrated articular derangements for whom conservative measures have failed [1]. Arthroscopy may be considered as a minimally invasive surgical option, allowing arthrocentesis with lavage of

the joint space, lysis of adhesions, and injection of glucocorticoids [62]. Trigger point injection with local anesthetic and trigger point acupuncture have both been demonstrated to be effective for patients with myofascial temporomandibular pain [63, 64]. Open joint surgery may be considered for severely affected patients if conservative options fail.

Dental Pain

Dental pathology is a very common cause of facial pain. In many cases, the source of dental pain, or *odontalgia*, is readily evident based upon a clinical history of dental disease or trauma. However, in instances where dental origin is not as easily recognizable, odontalgia may be difficult to distinguish from other causes of facial pain. Along with TMD, dental pathology is among the most common causes of secondary otalgia, and pain arising from dental sources may also radiate to the neck. It is thus critical to consider the possibility of dental pathology when evaluating patients for whom salivary disease is also on the differential diagnosis.

Odontogenic infections, including most notably dental caries and periodontal disease, are among the most common causes of orofacial pain. Approximately 90% of US adults develop dental caries, and 35% of dentate adults experience periodontitis [65, 66]. Early dental caries are generally asymptomatic, but can become acutely and severely painful if infection progresses to involve the dental pulp. Patients suffering from pulpitis are exquisitely sensitive to manipulation of the affected tooth and to changes in temperature, such as drinking cold liquids.

Dental trauma is another common cause of odontalgia. *Cracked tooth syndrome* refers to symptoms resulting from a fracture extending from the occlusal surface toward the apical aspect, without separation of the fracture fragments [67]. Fractures may result from repetitive masticatory trauma, from parafunctional habits such as bruxism, or in association with restorative dental procedures which can weaken the

tooth. Symptoms can be widely variable, but most often include some degree of orofacial discomfort for several months as well as sharp pain associated with biting or with consumption of cold foods. Pain may also be exacerbated by eating sugars, or by mandibular movement unassociated with eating. Patients may be unable to localize the pain to a specific tooth, or even to realize that the pain is dental in origin. Fractures which are covered by restorations can be difficult to diagnose, requiring exploratory excavation to visualize the site. Panoramic radiographs may demonstrate fractures which are aligned perpendicular to the plane of the film (buccolingual), but fractures aligned parallel to the plane of the film (mesiodistal) may be radiographically occult [67].

Atypical odontalgia refers to chronic pain in a tooth or alveolar region in the absence of clinically or radiographically evident dental pathology [68]. Patients with atypical odontalgia generally report chronic, persistent intraoral pain of moderate intensity which is frequently well localized to a tooth or extraction site. Pain is often associated with hyperesthesia or allodynia and evoked or exacerbated by temperature changes [68].

It is important to elicit history of associated dental symptoms or recent procedures in evaluating patients presenting with orofacial pain. Particular attention should be paid to history of temperature sensitivity or point tenderness. Intraoral examination should include careful inspection of the teeth and gums for signs of trauma or active infection. Localized erythema and swelling of the gingiva may indicate acute or chronic periodontal disease. Palpation along the occlusal surfaces of the teeth as well as the lingual and buccal aspects of the alveolar ridges may help to localize sites of infection, fracture, or hypersensitivity suggesting atypical odontalgia. Teeth with heavy restoration are at highest risk of infection or fracture, though specialized examination may be required to fully evaluate these sites. If dental pathology is suspected as the source of symptoms, a dental professional should be consulted for further evaluation and management [56].

Persistent Idiopathic Facial Pain

Persistent idiopathic facial pain (PIFP), previously called atypical facial pain, is characterized by daily, chronic facial pain in the absence of other clinical signs or symptoms. The underlying etiology of PIFP is uncertain, and it is largely a diagnosis of exclusion. As described by the International Classification of Headache Disorders, 3rd edition, the pain associated with PIFP is generally a deep, dull ache which is not well localized and does not correspond with a single sensory distribution [5]. There may be sharp exacerbations of more intense pain, and episodes may be aggravated by stress. There is no associated neurologic deficit, and no abnormalities are identified by laboratory or radiographic evaluation [69]. The incidence of PIFP is estimated at 1 case per 100,000 individuals [70].

Although the underlying pathophysiology is not well understood, PIFP may arise following minor surgery or injury to the face, suggesting an alteration in pain modulation following the initial noxious event [5]. Changes in the excitability of primary nociceptive afferents or central sensitization to pain stimuli may play a role in PIFP [71]. PIFP more commonly affects females and is sometimes comorbid with other incompletely understood entities such as chronic widespread pain, irritable bowel syndrome, and chronic fatigue [71, 72]. Empiric medical management with amitriptyline, SSRIs, or anticonvulsant drugs (lamotrigine, topiramate) may be successful in some instances, though no pharmacotherapy has been demonstrated to be consistently effective [69, 73]. Surgical interventions for PIFP have largely proven ineffective; as such, one of the primary goals of evaluation should be to establish the diagnosis of PIFP and thus avoid ineffective and potentially harmful invasive interventions.

Eagle's Syndrome

Eagle's syndrome describes a constellation of head and neck pain symptoms seen in association with an elongated styloid process or ossified

stylohyoid ligament. Although the anatomic anomaly was first described by Marchetti in 1652, the first clinical report associating the anatomic finding with symptomatology is credited to Weinlecher in 1872 [74]. The most common presentation of Eagle's syndrome is unilateral throat pain which is chronic and persistent, usually in patients who have previously undergone tonsillectomy. Although pain may be limited to the throat, it frequently refers to the ipsilateral ear and may radiate to the neck and even the shoulder or chest [75, 76]. Pain is generally described as aching or throbbing in quality, though sharper pain can be associated with certain triggers, including head turn, swallowing, and drinking cold liquids. Some patients will describe burning of the throat or neck, and globus or dysphagia may be present to varying degrees. Voice changes may rarely be present.

It is suspected that symptoms which develop following tonsillectomy are related to postoperative inflammatory changes and fibrosis affecting the styloid tip in patients with susceptible anatomy [76]. However, history of tonsillectomy or other prior surgery is not required for the development of symptoms. In the "carotid type" or variant of Eagle's syndrome, curvature or displacement of the distal styloid process may result in stimulation of pain-sensitive receptors within the adventitia of the internal or external carotid arteries [77, 78]. It is likely these anatomic variants which account for cases in which pain is referred to the neck, face, or shoulder. Carotid involvement has also been credited with headaches, dizziness, transient visual loss, syncope, and even transient ischemic attacks associated with Eagle's syndrome [79]. Although Eagle's syndrome is considered by some to be a secondary form of glossopharyngeal neuralgia [40], Eagle himself pointed out that the character and degree of pain associated with styloid pathology "is in no way comparable to the momentary, lancinating pains, of extremely severe character, that occur in cases of glossopharyngeal neuralgia" [77]. The syndrome is also distinct from glossopharyngeal or other cranial neuralgias in that multiple cranial nerves, including CN V, CN VII, CN IX, and CN X, have all been implicated in the

range of symptoms which these patients may experience [75, 79]. Due to the heterogeneity of clinical presentation, patients with Eagle's syndrome are often symptomatic for years before the correct diagnosis is established and may undergo numerous failed interventions as a result [75].

Physical examination of patients suspected to have Eagle's syndrome should include careful palpation of the tonsillar fossa. The presence of a palpable styloid process and reproducible pain with manipulation in this area is pathognomonic. Palpation of the neck over the region of the carotid bifurcation may elicit pain in a subset of patients [75, 79]. It should be noted here that the term *carotidynia* is often used to describe pain originating from carotid pathology, including not only Eagle's syndrome but also carotid aneurysm, dissection, atherosclerosis, or arteritis. In the past, carotidynia has been classified as a unique clinical entity [80], but this classification did not gain wide acceptance and carotidynia is now generally considered to be a symptom rather than a diagnosis [81, 82]. The diagnosis of Eagle's syndrome is easily confirmed by radiography, including either plain skull x-rays, panorex views, or diagnostic neck CT (Fig. 19.2). Although plain films are sufficient for diagnosis, CT offers additional anatomic information regarding adjacent neurovasculature which may be useful for surgical planning. Definitive management consists of surgical removal of the distal portion of the styloid, via either a transoral or transcervical approach. Patients with Eagle's syndrome who are appropriately diagnosed and treated have excellent prognosis, with resolution of pain following surgery in the majority of cases.

First Bite Syndrome

First bite syndrome (FBS) was first described in the otolaryngology literature in 1998 by Netterville and others as a postoperative pain syndrome observed following surgery for vagal paragangliomas [83]. FBS is now a well-recognized complication which may develop following any surgery of the parapharyngeal space. The true incidence of FBS is unknown, but has

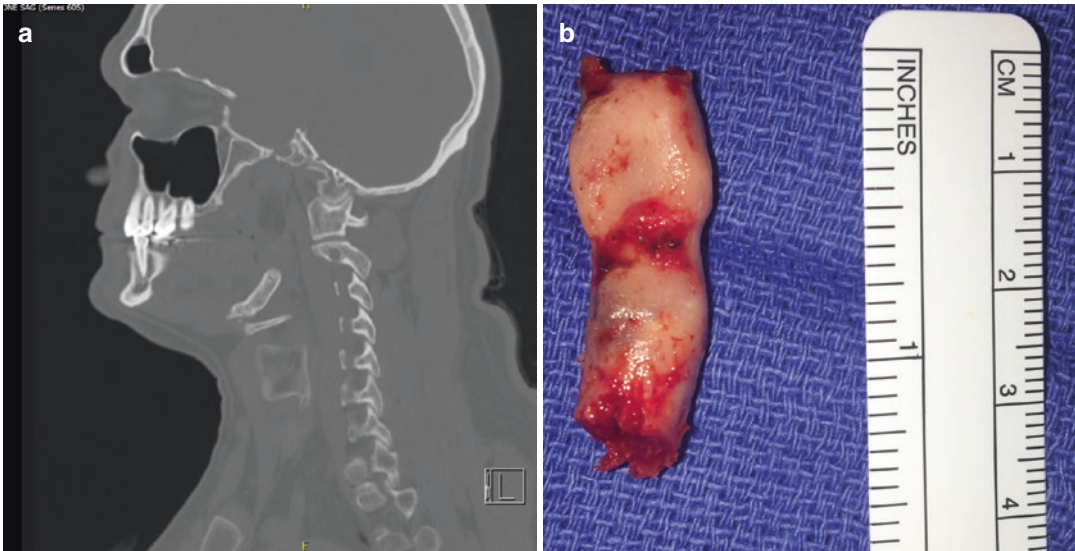


Fig. 19.2 Non-contrast sagittal CT scan demonstrating a thick calcified stylohyoid ligament (a) which was removed at surgery (b) to relieve symptoms of Eagle's syndrome (images courtesy of M. Boyd Gillespie, M.D.)

been reported at 12% in a series of 166 patients undergoing surgery of the parapharyngeal space [84]. FBS symptoms may be underreported or neglected in patients dealing with other treatment-associated issues.

First bite syndrome most often develops within days of parapharyngeal surgery, but may also be delayed several months [85]. Patients with FBS describe symptoms which begin immediately following the first bite of a meal and which consist primarily of intense cramping pain or spasm in the ipsilateral cheek, jaw, or ear. Pain generally resolves following several mouthfuls and is absent for the remainder of the meal. The most severe symptoms often occur with the first meal of the day, or with sialogogues such as sour, spicy, or acidic foods. Eating is not required to elicit symptoms; in many instances, the mere thought or smell of food can trigger symptoms. Symptoms can persist for months to years following surgery and may resolve without intervention in some cases. Symptoms are recurrent and predictable and result in significant anxiety for many patients affected by FBS. In severe cases, patients may alter or limit their diet in attempts to limit symptoms. The impacts on quality of life related to issues other than pain can thus also be significant.

The diagnosis of first bite syndrome is exclusively clinical, and a careful history and physical examination are therefore essential to distinguish FBS from temporomandibular joint disorders, cranial neuralgias, and other facial pain syndromes discussed in this chapter. Although history will include preceding parapharyngeal space surgery in 95% of cases, there have been multiple reports of FBS associated with malignant tumors of the parapharyngeal space [86–89]. In the absence of a history of neck surgery, pain fitting the description of FBS should thus prompt imaging to rule out the presence of tumor. A distinguishing feature of the physical exam is the absence of any trigger points or exacerbating movements associated with FBS, in contrast to TMJ disorder, trigeminal or glossopharyngeal neuralgia, Eagle's syndrome, or dental pain.

Netterville and colleagues theorized that FBS results from loss of sympathetic innervation to the parotid gland, resulting in unopposed parasympathetic stimulation of salivary myoepithelial cells [83]. The sympathetic cervical chain is composed of second-order neurons which exit the spinal cord near the junction of the cervical and thoracic spine and ascend to the superior cervical ganglion [90]. This ganglion measures about 3 cm in length and resides posterior to the

carotid sheath within the parapharyngeal space [91]. Postganglionic sympathetic fibers that course with the internal carotid artery innervate the orbit and eyelid. Disruption of these fibers leads to Horner's syndrome. Other postganglionic sympathetic fibers travel along the external carotid on their way to the sweat glands, skin, blood vessels, and parotid gland [92]. Disruption of sympathetic pathways at the level of the superior cervical ganglion itself may result in both Horner's syndrome and parotid gland sympathetic denervation, while injury distal to the ganglion may affect either of these pathways in isolation. Parasympathetic innervation of the parotid gland follows anatomically distinct pathways. First-order neurons arising from the inferior salivatory nucleus exit the jugular foramen, track with Jacobson's nerve (branch of CN IX) back into the skull via the inferior tympanic canaliculus to form the tympanic plexus, and then continue along the lesser petrosal nerve to exit foramen ovale. These neurons synapse with the postganglionic parasympathetic neurons in the otic ganglion, which is located medial to the mandibular branch of CN V, and postganglionic fibers travel to the submandibular and parotid glands via lingual and auriculotemporal branches of the trigeminal nerve, respectively [93]. Parapharyngeal space surgery thus provides an opportunity for sympathetic denervation of the parotid gland without disruption of the parasympathetic pathways.

Salivary myoepithelial cells are innervated by both sympathetic and parasympathetic fibers, either of which can elicit myoepithelial cell contraction via the release of acetylcholine [93–95]. It is speculated that in the setting of sympathetic denervation, sympathetic receptors on parotid myoepithelial cells may be cross-stimulated by acetylcholine released by parasympathetic fibers. This results in hypersensitivity to parasympathetic stimulation, with the result that intense, supramaximal contraction may accompany the initial parasympathetic signaling at the onset of eating. It is this hypersensitivity and intense contractile response that results in the acute cramping pain of FBS [83, 96, 97]. This supersensitivity appears to become quickly

desensitized after its abrupt activation, and subsequent bites do not elicit the same response [83, 98].

Given the natural history of eventual spontaneous resolution in many cases, it is reasonable to offer reassurance and observation as an initial strategy for patients presenting with first bite syndrome. Patients may try dietary modification and avoidance of sialogogues, though this may not prove particularly effective [83, 99]. The rarity of FBS has precluded thorough investigation of any intervention, and outcomes of pharmacologic therapy are based almost entirely upon case reports [88]. The use of pregabalin and carbamazepine has been reported, with mixed results [85, 100–102]. Nonsteroidal anti-inflammatory agents have not shown benefit [96, 103].

Surgical approaches involving targeted parasympathetic denervation have been reported, though little success has been observed with tympanic neurectomy [96, 104, 105] or auriculotemporal nerve resection [83]. Patients with FBS receiving adjuvant radiation therapy for oncologic indications have been reported to have significant improvement of FBS pain symptoms, but the morbidity and associated risks likely outweigh the benefit of administering radiation with the sole purpose of treating FBS [96, 103]. Completion parotidectomy is not advised due to inappropriate risk to the facial nerve. Existing literature suggests that botulinum toxin A can be an effective and safe treatment for FBS, though an optimal dosing regimen has yet to be defined [98, 99, 104, 106]. It may take up to 2 years to achieve complete symptom resolution, with repeat injections required every 4–6 months during that time [104, 106].

Neoplasm

It must be emphasized that any evaluation of a patient presenting with symptoms of head, neck, or facial pain should include consideration of the possibility of tumor. Both benign and malignant neoplasms of the head and neck may result in pain, neurosensory changes, or other symptoms similar or identical to those which may be experienced with the various facial pain syndromes described

in this chapter. Careful history and comprehensive head and neck examination should include evaluation for potential tumor, with additional testing or imaging if indicated based upon this evaluation. Description of the appropriate evaluation for head and neck neoplasms is beyond the scope of this text, but will likely be familiar to most otolaryngologists, head and neck surgeons, or maxillofacial surgeons evaluating these patients.

References

- Hentschel K, Capobianco DJ, Dodick DW. Facial pain. *Neurologist*. 2005;11:244–9.
- Brewis M, Poskanzer DC, Rolland C, Miller H. Neurological disease in an English city. *Acta Neurol Scand*. 1966;42(Suppl 24):1–89.
- Katusic S, Williams DB, Beard CM, et al. Epidemiology and clinical features of idiopathic trigeminal neuralgia and glossopharyngeal neuralgia: similarities and differences, Rochester, Minnesota, 1945–1984. *Neuroepidemiology*. 1991;10:276–81.
- MacDonald BK, Cockerell OC, Sander JW, Shorvon SD. The incidence and lifetime prevalence of neurological disorders in a prospective community-based study in the UK. *Brain*. 2000;123:665–76.
- IHS Classification Committee. The International classification of headache disorders, 3rd edition (beta version). *Cephalalgia*. 2013;33:629–808.
- Maarbjerg S, Gozalov A, Olesen J, Bendtsen L. Trigeminal neuralgia—a prospective systematic study of clinical characteristics in 158 patients. *Headache*. 2014;54:1574–82.
- Cohen-Gadol AA. Microvascular decompression surgery for trigeminal neuralgia and hemifacial spasm: nuances of the technique based on experiences with 100 patients and review of the literature. *Clin Neurol Neurosurg*. 2011;113:844–53.
- Love S, Coakham HB. Trigeminal neuralgia: pathology and pathogenesis. *Brain*. 2001;124:2347–60.
- Devor M, Amir R, Rappaport ZH. Pathophysiology of trigeminal neuralgia: the ignition hypothesis. *Clin J Pain*. 2002;18:4–13.
- Devor M, Govrin-Lippmann R, Rappaport ZH. Mechanism of trigeminal neuralgia: an ultrastructural analysis of trigeminal root specimens obtained during microvascular decompression surgery. *J Neurosurg*. 2002;96:532–43.
- Maarbjerg S, Wolfram F, Gozalov A, et al. Significance of neurovascular contact in classical trigeminal neuralgia. *Brain*. 2015;138:311–9.
- Wu Z, Qian X-Y, An J-X, et al. Trigeminal neuralgia induced by cobra venom in the rat leads to deficits in abilities of spatial learning and memory. *Pain Physician*. 2015;18:E207–16.
- Wellbery C. Coping with the pain. *Am Fam Physician*. 2007;76:1757.
- Vallejo-García JL, Vañó-Galván S, Rayward O, Moreno-Martin P. Painful eye with a facial rash. *Cleve Clin J Med*. 2009;76:410–2.
- Cruccu G, Biasiotta A, Di Rezze S, et al. Trigeminal neuralgia and pain related to multiple sclerosis. *Pain*. 2009;143:186–91. doi:10.1016/j.pain.2008.12.026.
- Hooge JP, Redekop WK. Trigeminal neuralgia in multiple sclerosis. *Neurology*. 1995;45:1294–6.
- Bischof A, Sprenger T. Interferon beta-associated recurrence of painful trigeminal neuropathy attributed to a multiple sclerosis plaque. *J Headache Pain*. 2014;15:21.
- La Mantia L, D’Amico D, Rigamonti A, et al. Interferon treatment may trigger primary headaches in multiple sclerosis patients. *Mult Scler*. 2006;12:476–80.
- McCormick PC, Bello JA, Post KD. Trigeminal schwannoma. Surgical series of 14 cases with review of the literature. *J Neurosurg*. 1988;69:850–60.
- Gronseth G, Cruccu G, Alksne J, et al. Practice parameter: the diagnostic evaluation and treatment of trigeminal neuralgia (an evidence-based review): report of the Quality Standards Subcommittee of the American Academy of Neurology and the European Federation of Neurological Societies. *Neurology*. 2008;71:1183–90.
- Hitchon PW, Zanaty M, Moritani T, et al. Microvascular decompression and MRI findings in trigeminal neuralgia and hemifacial spasm. A single center experience. *Clin Neurol Neurosurg*. 2015;139:216–20.
- Campbell FG, Graham JG, Zilkha KJ. Clinical trial of carbamazepine (tegretol) in trigeminal neuralgia. *J Neurol Neurosurg Psychiatry*. 1966;29:265–7.
- Killian JM, Fromm GH. Carbamazepine in the treatment of neuralgia. Use of side effects. *Arch Neurol*. 1968;19:129–36.
- Rockliff BW, Davis EH. Controlled sequential trials of carbamazepine in trigeminal neuralgia. *Arch Neurol*. 1966;15:129–36.
- Beydoun A. Safety and efficacy of oxcarbazepine: results of randomized, double-blind trials. *Pharmacotherapy*. 2000;20:152S–8S.
- Fromm GH, Terrence CF, Chattha AS. Baclofen in the treatment of trigeminal neuralgia: double-blind study and long-term follow-up. *Ann Neurol*. 1984;15:240–4.
- Zakrzewska JM, Chaudhry Z, Nurmikko TJ, et al. Lamotrigine (lamictal) in refractory trigeminal neuralgia: results from a double-blind placebo controlled crossover trial. *Pain*. 1997;73:223–30.
- De Siqueira SRDT, da Nóbrega JCM, de Siqueira JTT, Teixeira MJ. Frequency of postoperative complications after balloon compression for idiopathic trigeminal neuralgia: prospective study. *Oral Surg Oral Med Oral Pathol Oral Radiol Endod*. 2006;102:e39–45.
- Mittal B, Thomas DG. Controlled thermocoagulation in trigeminal neuralgia. *J Neurol Neurosurg Psychiatry*. 1986;49:932–6.
- North RB, Kidd DH, Piantadosi S, Carson BS. Percutaneous retrogasserian glycerol rhizotomy.

- Predictors of success and failure in treatment of trigeminal neuralgia. *J Neurosurg.* 1990;72:851–6.
31. Zakrzewska JM, Jassim S, Bulman JS. A prospective, longitudinal study on patients with trigeminal neuralgia who underwent radiofrequency thermocoagulation of the Gasserian ganglion. *Pain.* 1999;79:51–8.
 32. Barker FG, Jannetta PJ, Bissonette DJ, et al. The long-term outcome of microvascular decompression for trigeminal neuralgia. *N Engl J Med.* 1996;334:1077–83.
 33. Broggi G, Ferroli P, Franzini A, et al. Microvascular decompression for trigeminal neuralgia: comments on a series of 250 cases, including 10 patients with multiple sclerosis. *J Neurol Neurosurg Psychiatry.* 2000;68:59–64.
 34. Piatt JH, Wilkins RH. Microvascular decompression for tic douloureux. *Neurosurgery.* 1984;15:456.
 35. Li G-W, Lan Q, Zhang W-C. Clinical characteristics and treatment of trigeminal neuralgia following herpes zoster. *J Craniofac Surg.* 2015;26:e448–51.
 36. Mansour N, Kaliaperumal C, Choudhari KA. Facial herpes zoster infection precipitated by surgical manipulation of the trigeminal nerve during exploration of the posterior fossa: a case report. *J Med Case Rep.* 2009;3:7813.
 37. Simms HN, Dunn LT. Herpes zoster of the trigeminal nerve following microvascular decompression. *Br J Neurosurg.* 2006;20:423–6.
 38. Kalkanis SN, Eskandar EN, Carter BS, Barker FG. Microvascular decompression surgery in the United States, 1996 to 2000: mortality rates, morbidity rates, and the effects of hospital and surgeon volumes. *Neurosurgery.* 2003;52:1251–61.
 39. Ferroli P, Fioravanti A, Schiariti M, et al. Microvascular decompression for glossopharyngeal neuralgia: a long-term retrospective review of the Milan-Bologna experience in 31 consecutive cases. *Acta Neurochir.* 2009;151:1245–50.
 40. De Simone R, Ranieri A, Bilo L, et al. Cranial neuralgias: from physiopathology to pharmacological treatment. *Neurol Sci.* 2008;29(Suppl 1):S69–78.
 41. Rushton JG, Stevens JC, Miller RH. Glossopharyngeal (vagusglossopharyngeal) neuralgia: a study of 217 cases. *Arch Neurol.* 1981;38:201–5.
 42. Elias J, Kuniyoshi R, Carloni WVH, et al. Glossopharyngeal neuralgia associated with cardiac syncope. *Arq Bras Cardiol.* 2002;78:510–9.
 43. Esaki T, Osada H, Nakao Y, et al. Surgical management for glossopharyngeal neuralgia associated with cardiac syncope: two case reports. *Br J Neurosurg.* 2007;21:599–602.
 44. Kazemi B, Akbarzadeh F. Syncopal storm caused by glossopharyngeal neuralgia. *Am J Emerg Med.* 2012;30:2101.e5–7.
 45. Ozenci M, Karaoguz R, Conkbayir C, et al. Glossopharyngeal neuralgia with cardiac syncope treated by glossopharyngeal rhizotomy and microvascular decompression. *Eurpace.* 2003;5:149–52.
 46. Park K-J, Choi N-C, Kim S-K, et al. Teaching neuroimages: glossopharyngeal neuralgia with syncope: heart rate and blood pressure change. *Neurology.* 2011;77:e84.
 47. Savica R, Laganà A, Calabrò RS, et al. Vagusglossopharyngeal neuralgia: a rare case of syncope responding to pregabalin. *Cephalalgia.* 2007;27:566–7.
 48. Rozen TD. Trigeminal neuralgia and glossopharyngeal neuralgia. *Neurol Clin.* 2004;22:185–206.
 49. Rey-Dios R, Cohen-Gadol AA. Current neurosurgical management of glossopharyngeal neuralgia and technical nuances for microvascular decompression surgery. *Neurosurg Focus.* 2013;34:E8.
 50. Tang IP, Freeman SR, Kontorinis G, et al. Geniculate neuralgia: a systematic review. *J Laryngol Otol.* 2014;128:394–9.
 51. Yeh HS, Tew JM. Tic convulsif, the combination of geniculate neuralgia and hemifacial spasm relieved by vascular decompression. *Neurology.* 1984;34:682–3.
 52. Eshraghi AA, Buchman CA, Telischi FF. Sensory auricular branch of the facial nerve. *Otol Neurotol.* 2002;23:393–6.
 53. Isong U, Gansky SA, Plesh O. Temporomandibular joint and muscle disorder-type pain in U.S. adults: the National Health Interview Survey. *J Orofac Pain.* 2008;22:317–22.
 54. Peck CC, Goulet J-P, Lobbezoo F, et al. Expanding the taxonomy of the diagnostic criteria for temporomandibular disorders. *J Oral Rehabil.* 2014;41:2–23.
 55. Cooper BC, Kleinberg I. Examination of a large patient population for the presence of symptoms and signs of temporomandibular disorders. *Cranio.* 2007;25:114–26.
 56. Kim DS, Cheang P, Dover S, Drake-Lee AB. Dental otalgia. *J Laryngol Otol.* 2007;121:1129–34.
 57. Kapur N, Kamel IR, Herlich A. Oral and craniofacial pain: diagnosis, pathophysiology, and treatment. *Int Anesthesiol Clin.* 2003;41:115–50.
 58. Greene CS. The etiology of temporomandibular disorders: implications for treatment. *J Orofac Pain.* 2001;15:93–105.
 59. Giannakopoulos NN, Keller L, Rammelsberg P, et al. Anxiety and depression in patients with chronic temporomandibular pain and in controls. *J Dent.* 2010;38:369–76.
 60. Bragdon EE, Light KC, Costello NL, et al. Group differences in pain modulation: pain-free women compared to pain-free men and to women with TMD. *Pain.* 2002;96:227–37.
 61. McNeely ML, Armijo Olivo S, Magee DJ. A systematic review of the effectiveness of physical therapy interventions for temporomandibular disorders. *Phys Ther.* 2006;86:710–25.
 62. McCain JP, Sanders B, Koslin MG, et al. Temporomandibular joint arthroscopy: A 6-year multicenter retrospective study of 4,831 joints. *J Oral Maxillofac Surg.* 1992;50:926–30.
 63. Itoh K, Asai S, Ohyabu H, et al. Effects of trigger point acupuncture treatment on Temporomandibular disorders: a preliminary randomized clinical trial. *J Acupunct Meridian Stud.* 2012;5:57–62.

64. Özkan F, Cakır-Özkan NÇ, Erkorkmaz Ü. Trigger point injection therapy in the management of myofascial temporomandibular pain. *Agri*. 2011;23:119–25.
65. Albandar JM, Brunelle JA, Kingman A. Destructive periodontal disease in adults 30 years of age and older in the United States, 1988–1994. *J Periodontol*. 1999;70:13–29.
66. Beltrán-Aguilar ED, Barker LK, Canto MT, et al. Surveillance for dental caries, dental sealants, tooth retention, edentulism, and enamel fluorosis—United States, 1988–1994 and 1999–2002. *MMWR Surveill Summ*. 2005;54:1–43.
67. Hasan S, Singh K, Salati N. Cracked tooth syndrome: overview of literature. *Int J Appl Basic Med Res*. 2015;5:164–8.
68. Forssell H, Jääskeläinen S, List T, et al. An update on pathophysiological mechanisms related to idiopathic oro-facial pain conditions with implications for management. *J Oral Rehabil*. 2015;42:300–22.
69. Evans RW, Agostoni E. Persistent idiopathic facial pain. *Headache*. 2006;46:1298–300.
70. Didier H, Marchetti C, Borromeo G, et al. Persistent idiopathic facial pain: multidisciplinary approach and assumption of comorbidity. *Neurol Sci*. 2010;31(Suppl 1):S189–95.
71. Sardella A, Demarosi F, Barbieri C, Lodi G. An up-to-date view on persistent idiopathic facial pain. *Minerva Stomatol*. 2009;58:289–99.
72. Aggarwal VR, McBeth J, Zakrzewska JM, et al. The epidemiology of chronic syndromes that are frequently unexplained: do they have common associated factors? *Int J Epidemiol*. 2006;35:468–76.
73. Volcy M, Rapoport AM, Tepper SJ, et al. Persistent idiopathic facial pain responsive to topiramate. *Cephalalgia*. 2006;26:489–91.
74. Eagle WW. Elongated styloid processes: report of two cases. *Arch Otolaryngol*. 1937;25:584–7.
75. Mendelsohn AH, Berke GS, Chhetri DK. Heterogeneity in the clinical presentation of Eagle's syndrome. *Otolaryngol Head Neck Surg*. 2006;134:389–93.
76. Mortellaro C, Bianucci P, Picciolo G, Vercellino V. Eagle's syndrome: importance of a corrected diagnosis and adequate surgical treatment. *J Craniofac Surg*. 2002;13:755–8.
77. Eagle WW. Symptomatic elongated styloid process; report of two cases of styloid process-carotid artery syndrome with operation. *Arch Otolaryngol*. 1949;49:490–503.
78. Krespi YP, Shugar JMA, Som PM. Stylohyoid syndromes: an uncommon cause of pharyngeal and neck pain. *Am J Otolaryngol*. 1981;2:358–60.
79. Fusco DJ, Asteraki S, Spetzler RF. Eagle's syndrome: embryology, anatomy, and clinical management. *Acta Neurochir*. 2012;154:1119–26.
80. IHS Classification Committee. Classification and diagnostic criteria for headache disorders, cranial neuralgias and facial pain, 2nd edition. *Cephalalgia*. 1988;8:1–96.
81. Biousse V, Boussier MG. The myth of carotidynia. *Neurology*. 1994;44:993–5.
82. Forwith KD, Tami TA. Carotidynia: symptom or diagnosis? *Curr Opin Otolaryngol Head Neck Surg*. 1999;7:150.
83. Nettekville JL, Jackson CG, Miller FR. Vagal paraganglioma: a review of 46 patients treated during a 20-year period. *Arch Otolaryngol Head Neck Surg*. 1998;124(10):1133–40.
84. Cohen SM, Burkey BB, Nettekville JL. Surgical management of parapharyngeal space masses. *Head Neck*. 2005;27:669–75.
85. Cernea CR, Hojaij FC, De Carlucci D. First-bite syndrome after resection of the styloid process. *Laryngoscope*. 2007;117:181–2.
86. Deganello A, Meccariello G, Busoni M, et al. First bite syndrome as presenting symptom of parapharyngeal adenoid cystic carcinoma. *J Laryngol Otol*. 2011;125:428–31.
87. Diercks GR, Rosow DE, Prasad M, Kuhel WI. A case of preoperative “first-bite syndrome” associated with mucoepidermoid carcinoma of the parotid gland. *Laryngoscope*. 2011;121:760–2.
88. Laccourreye O, Werner A, Garcia D, et al. First bite syndrome. *Eur Ann Otorhinolaryngol Head Neck Dis*. 2013;130:269–73.
89. Lieberman SM, Har-El G. First bite syndrome as a presenting symptom of a parapharyngeal space malignancy. *Head Neck*. 2011;33:1539–41.
90. Fields CR, Barker FI. Review of Horner's syndrome and a case report. *Optom Vis Sci*. 1992;69:481–5.
91. Amonoo-Kuofi HA. Horner's syndrome revisited: with an update of the central pathway. *Clin Anat*. 1999;12:345–61.
92. Collins SL. The cervical sympathetic nerves in surgery of the neck. *Otolaryngol Head Neck Surg*. 1991;105:544–55.
93. Holsinger FC, Bui DT. Anatomy, function, and evaluation of the salivary glands. In: Myers EN, Ferris RL, editors. *Salivary gland disorders*. Berlin: Springer Science & Business Media; 2007.
94. Garrett JR, Emmelin N. Activities of salivary myoepithelial cells: a review. *Med Biol*. 1979;57:1–28.
95. Garrett JR, Kidd A. The innervation of salivary glands as revealed by morphological methods. *Microsc Res Tech*. 1993;26:75–91.
96. Chiu AG, Cohen JJ, Burningham AR. First bite syndrome: a complication of surgery involving the parapharyngeal space. *Head Neck*. 2002;24:996–9.
97. Kawashima Y, Sumi T, Sugimoto T, Kishimoto S. First-bite syndrome: a review of 29 patients with parapharyngeal space tumor. *Auris Nasus Larynx*. 2008;35:109–13.
98. Lee BJ, Lee JC, Lee YO, et al. Novel treatment of first bite syndrome using botulinum toxin type A. *Head Neck*. 2009;31:989–93.
99. Sims JR, Suen JY. First bite syndrome: case report of 3 patients treated with botulinum toxin and review of other treatment modalities. *Head Neck*. 2013;35:E288–91.
100. Borràs-Perera M, Fortuny-Llansas JC, Palomar-Asenjo V, Palomar-García V. First-bite syndrome. *Acta Otorrinolaringol*. 2009;60:144–5.

101. Casserly P, Kiely P, Fenton JE. Cervical sympathetic chain schwannoma masquerading as a carotid body tumour with a postoperative complication of first-bite syndrome. *Eur Arch Otorhinolaryngol*. 2009;266:1659–62.
102. Phillips T, Smith WF. Pharmacological treatment of a patient with first-bite syndrome. *Anaesthesia*. 2009;64:97–8.
103. Costa TP, de Araujo C, Filipe J. First-bite syndrome in oncologic patients. *Eur Arch Otorhinolaryngol*. 2011;268:1241–4.
104. Ali MJ, Orloff LA, Lustig LR. Botulinum toxin in the treatment of first bite syndrome. *Otolaryngol Head Neck Surg*. 2008;139:742–3.
105. Amin N, Pelsner A, Weighill J. First bite syndrome: our experience of laser tympanic plexus ablation. *J Laryngol Otol*. 2014;128:166–8.
106. Ghosh A, Mirza N. First bite syndrome: our experience with intraparotid injections with botulinum toxin type A. *Laryngoscope*. 2016;126:104–7.

Part VI

Bringing it All Together: Expert Opinions

Arjun S. Joshi

Case 1

An otherwise healthy 42-year-old female presented to her primary care physician with acute onset left submandibular fullness with ear pain of 3-day duration. She denied any postprandial symptoms or external neck swelling. She denied any prior episodes. She was placed on antibiotics, and after several days the fullness subsided, but she continued to have ear discomfort. She was then referred and evaluated by an outside otolaryngologist who ordered a CT neck with contrast which failed to demonstrate any obstructive pathology involving the parotid or submandibular glands (Fig. 20.1). Conservative management was recommended.

The patient continued to complain of left neck/ear fullness and sought further evaluation. Physical examination was unrevealing overall. There was no expressible saliva from the left submandibular duct. The right submandibular duct was normal. Based on the patient's history which was convincing for obstruction, ultrasound was performed, and intraglandular

ductal dilation of the left submandibular gland was appreciated. The ultrasound examination was repeated after oral administration of citric acid which demonstrated a markedly dilated submandibular duct which was visualized into the anterior floor of the mouth suggesting distal obstruction (Fig. 20.2).

The patient underwent diagnostic sialendoscopy under local anesthesia in the office, and a small 1.5 mm stone was identified in the distal aspect of the submandibular duct. This was easily retrieved with a wire basket using a purely endoscopic technique.

The patient is doing well after follow-up for 4 months without any further symptoms.

Key Points

1. Typical symptoms of obstructive sialadenitis of the submandibular glands include fullness with or without visible swelling and commonly ear pain or fullness.
2. CT and US are complementary examinations, and in cases with a high index of suspicion, should both be performed for complete evaluation.
3. Although ultrasound may not demonstrate a sialolith in all cases (small stones), it is excellent at demonstrating ductal dilation which is an indirect sign for obstructive pathology.
4. The use of oral citric acid is particularly helpful to evaluate patients in which obstruction is suspected.

Electronic Supplementary Material The online version of this chapter (doi:[10.1007/978-3-319-58335-8_20](https://doi.org/10.1007/978-3-319-58335-8_20)) contains supplementary material, which is available to authorized users.

A.S. Joshi, M.D.

Division of Otolaryngology —Head and Neck Surgery,
George Washington University,
Washington, DC, USA
e-mail: ajoshi@mfa.gwu.edu

Fig. 20.1 Axial computed tomography scan with contrast demonstrates normal anatomy in patient with history of left submandibular swelling

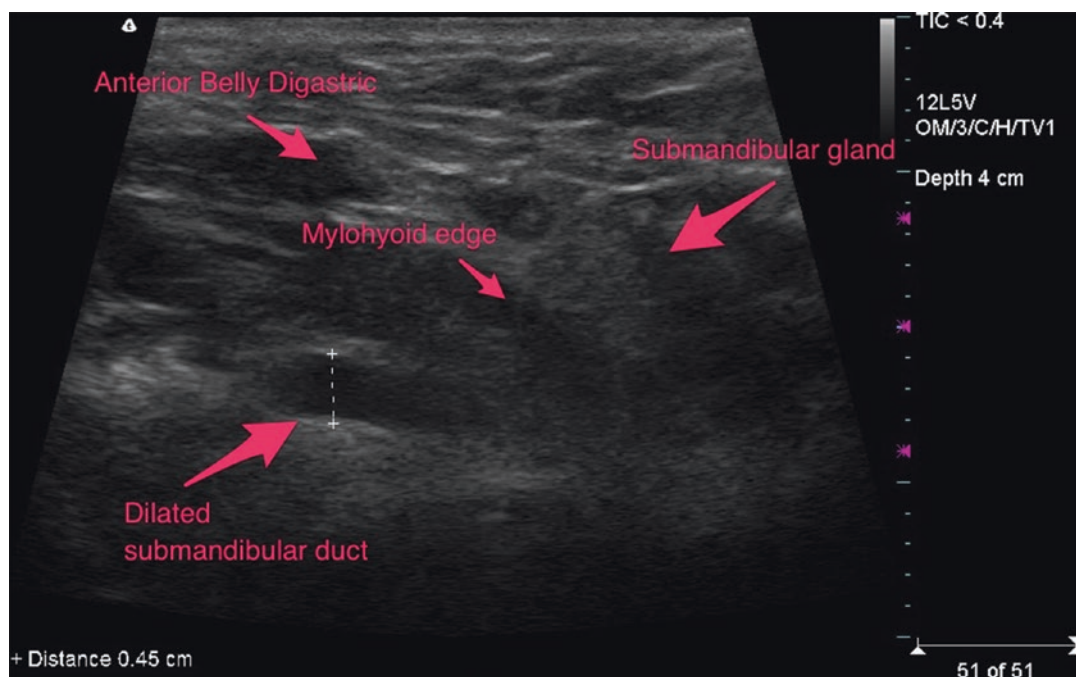
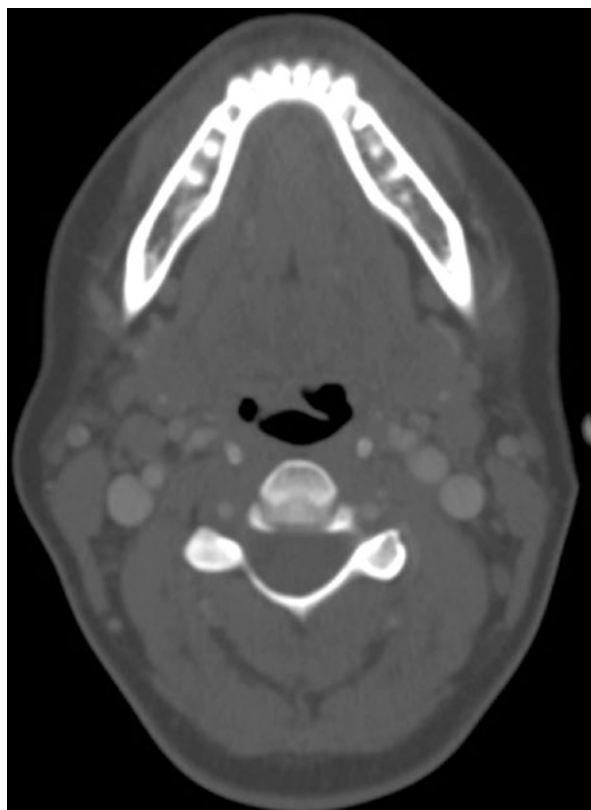


Fig. 20.2 Ultrasound image of left submandibular gland after sialogogue challenge shows dilated duct consistent with obstructive pathology

Case 2

A 62-year-old female presented with a 6-year history of intermittent right submandibular gland swelling and pain. In the year prior to the onset of her symptoms, she underwent treatment for breast cancer, including postoperative chemoradiation therapy, during which time she experienced prolonged dehydration and xerostomia. The following year, she developed recurrent episodes of right submandibular gland swelling and pain, which gradually became more frequent and occasionally required antibiotic therapy for resolution. Between episodes, she reported mild persistent swelling. She underwent a CT scan of the neck, which revealed multifocal punctate salivary stones in the right submandibular gland, the large-

est measuring 8 mm (Fig. 20.3). She was seen at an outside hospital and counseled to undergo gland removal due to the large hilar stones. Concerned about the potential xerostomia from gland removal, she presented to our institution to discuss gland-preserving options.

On exam, the patient had turbid saliva produced from the right submandibular duct with gland massage. The stones could be felt on bimanual palpation of the right posterior floor of the mouth. Upon independent review of the CT scan, using bone windowing (Fig. 20.4), the previously identified larger stones showed variable densities suggesting that they possibly could be a conglomeration of smaller stones. Therefore, the patient was scheduled for sialendoscopy-assisted sialolithotomy, with potential gland

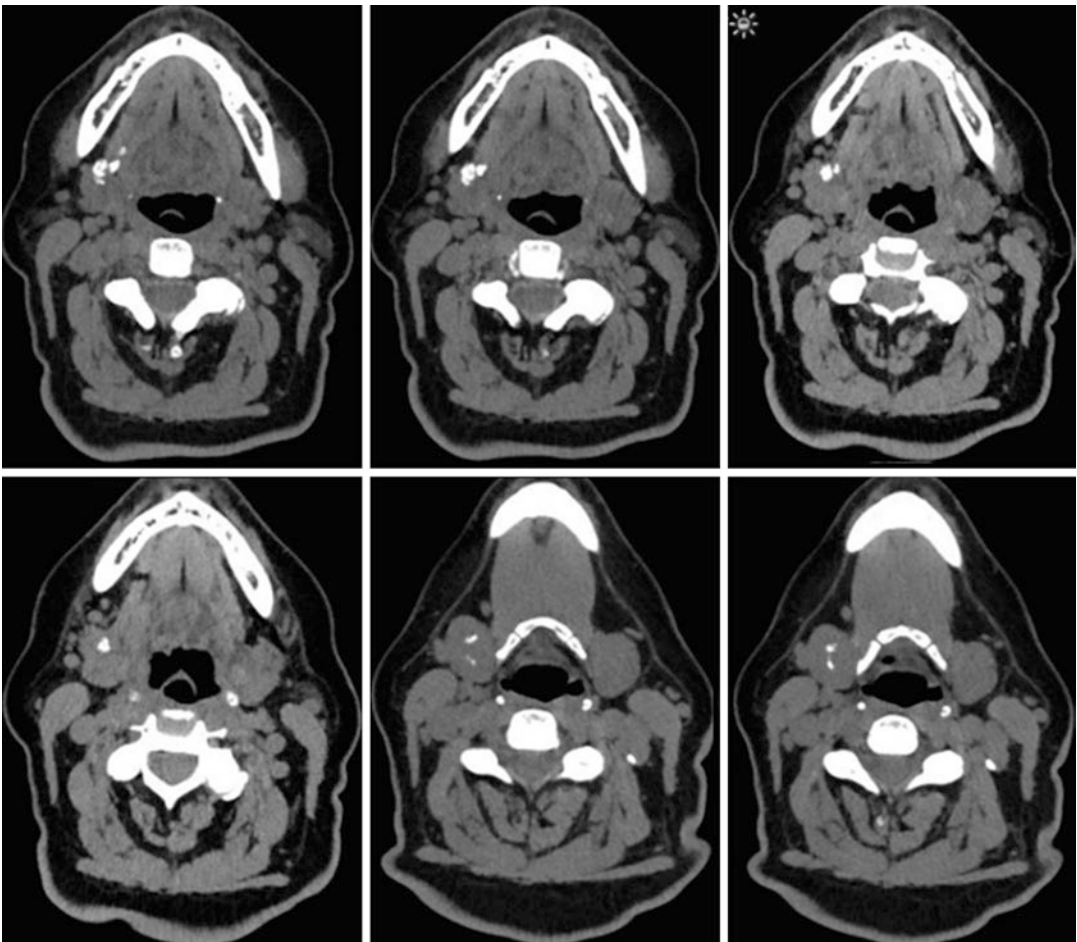


Fig. 20.3 CT demonstrating the multifocal stones in the right submandibular gland

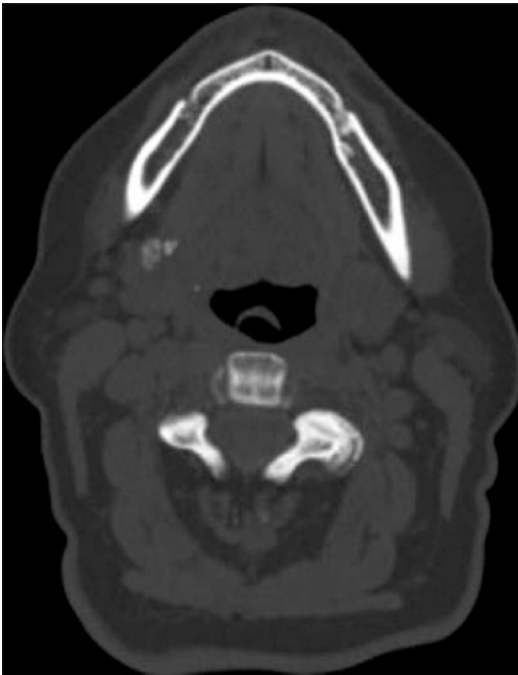


Fig. 20.4 CT scan from Fig. 20.3, on bone window, demonstrating variable density within the larger calcification

excision. Given the multiple stones, we elected to check the patient's serum calcium and parathyroid hormone level as part of her operative blood work, and they returned elevated at 10.7 mg/dL and 91 pg/mL, respectively, suggesting primary hyperparathyroidism.

The patient underwent successful outpatient sialendoscopy with endoscopic sialolithotomy of 32 individual submandibular stones (Fig. 20.5), the largest being 3 mm in length, confirming the suspicion of conglomerate stones and not megaliths. Salivary flow was restored and her submandibular swelling resolved.

On postoperative follow-up, the patient was counseled about the diagnosis of hyperparathyroidism and its relationship to sialolithiasis development. The patient underwent DEXA scan, which revealed osteopenia of her femur. Due to the osteopenia, elevated PTH levels, and sialolithiasis, she was recommended for parathyroidectomy and counseled that the majority of cases of hyperparathyroidism are due to adenomas. SPECT/CT was obtained but failed to localize an adenoma. The patient was therefore

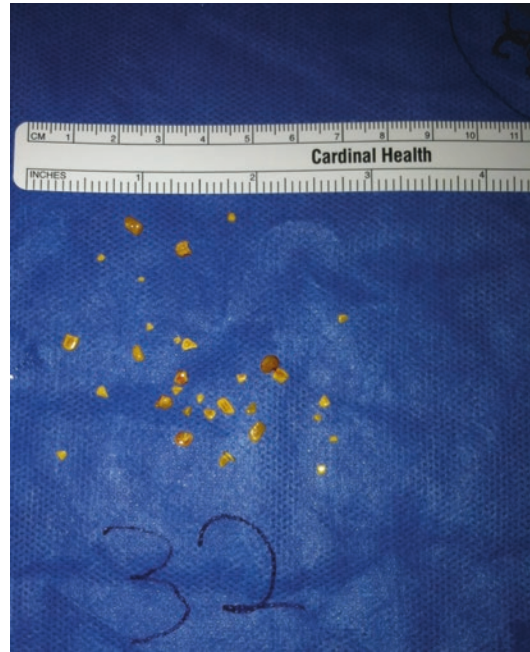

Fig. 20.5 Back-table operative view of the 32 stones endoscopically extracted from the submandibular gland

evaluated in the clinic with ultrasonography during her preoperative workup for parathyroidectomy, and a hypoechoic rounded lesion was detected below the right inferior pole of the thyroid, consistent with a likely parathyroid adenoma. She was advised of the findings and prepared for parathyroidectomy, including possible four gland excisions.

She underwent parathyroidectomy, during which a right inferior parathyroid adenoma was identified and removed resulting in a drop in her intraoperative PTH value from 91 (pre-incision) to 30 (10 min post-excision).

Since surgery, her calcium and PTH levels have remained normal, and she has remained symptom-free with respect to her salivary glands for the last 3 years (Fig. 20.6).

Key Points

1. Conditions or medications resulting in dehydration change salivary viscosity and may lead to stones.
2. Glands that intermittently swell from obstruction possess salivary function that is worth saving.

3. Salivary stones are best viewed on bone windowing.
4. Larger stones on CT may actually be a conglomeration of smaller stones amenable to sialendoscopy.
5. The presence of multiple or recurrent salivary stones should prompt a workup for hyperparathyroidism.
6. Ultrasonography is a very sensitivity tool for detecting parathyroid adenomas not seen on SPECT scan.

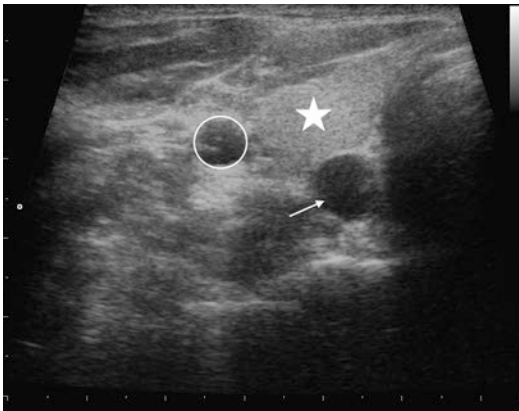


Fig. 20.6 Ultrasound of the right parathyroid adenoma (*arrow*) posterior to the inferior pole of the thyroid (*star*); carotid artery is seen lateral to the gland (*circle*)

Case 3

Key Points

1. A focal parotid abscess should raise suspicion for a parotid stone.
2. Stones posterior to the posterior edge of the parotid are not typically visualized on sialendoscopy.
3. Existing scars can be utilized for transfacial excision of parotid stones.
4. Ultrasound can be used to needle localize stones within the parotid gland.
5. Punctate stones within the proximal gland are unlikely to be symptomatic.

A 39-year-old man presents with purulent drainage from the skin just behind the angle of the mandible with underlying fluctuance. He reports that this began with parotid swelling 2 weeks prior. He was evaluated at an urgent care after 3 days and started on antibiotics. Despite this, the swelling and pain progressed which prompted a CT scan. This scan identified a 6 mm stone within the posterior parotid with a surrounding complex abscess (Fig. 20.7). There were punctate scattered additional stones in the parotid. Needle aspiration was performed but did not resolve the abscess. He sought further evaluation when the overlying skin opened with purulent drainage.

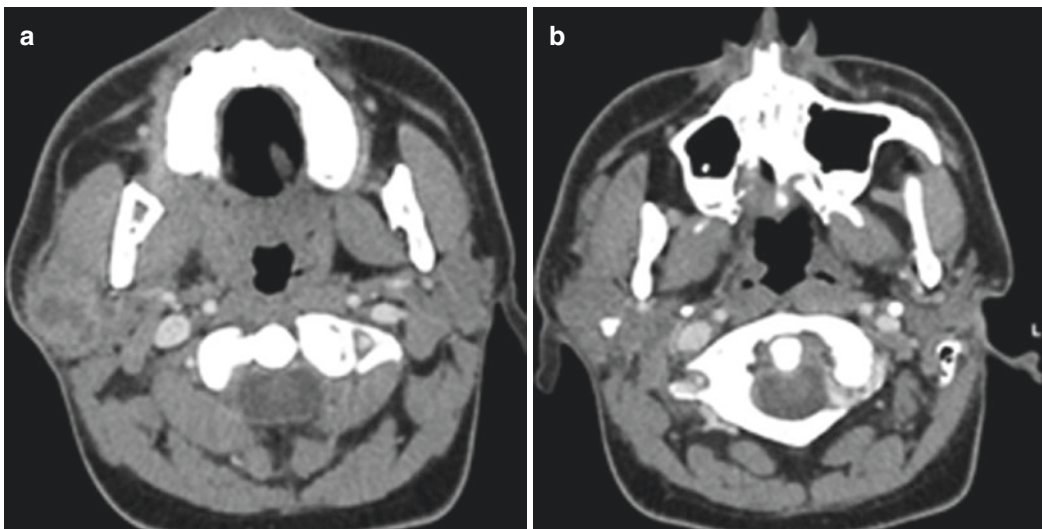


Fig. 20.7 CT demonstrating right parotid stone (**a**) with developing abscess (**b**)

He is healthy without significant past medical history. He denied any history of previous swelling and denies any history of smoking. He was on no long-term medications. He denied long-term difficulty with dry mouth.

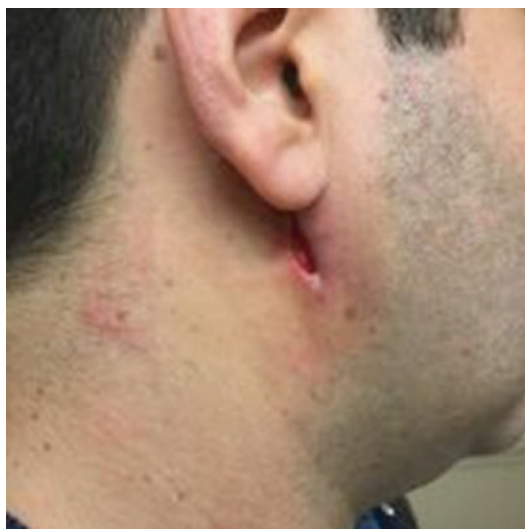

Fig. 20.8 Healing wound after incision and drainage of right parotid abscess

On examination, his oral cavity was clear. There was no expressible saliva from Stenson's papilla. In the right posterior parotid, there was an area of focal fluctuance with thinning of the overlying skin. Incision and drainage was performed which drained all pus but did not deliver the stone (Fig. 20.8). Packing was placed.

After the wound healed, his symptoms essentially resolved. Ultrasound demonstrated the large stone remained present within the parotid parenchyma just anterior to his earlobe. After a discussion of options, he was taken to the operating room for sialendoscopy and ultrasound-guided transfacial excision of stone. Another CT scan was performed preoperatively (Fig. 20.9).

Based on the location of the stone posterior to the edge of the masseter muscle and in the parenchyma of the gland, it was anticipated that the stone would not be visualized on sialendoscopy. Sialendoscopy was performed, and the duct was navigated past the main branching point at 4.5 cm and into proximal branches. No stones were visualized. As such a transfacial approach was planned. His existing scar from his previous incision and drainage was utilized for access

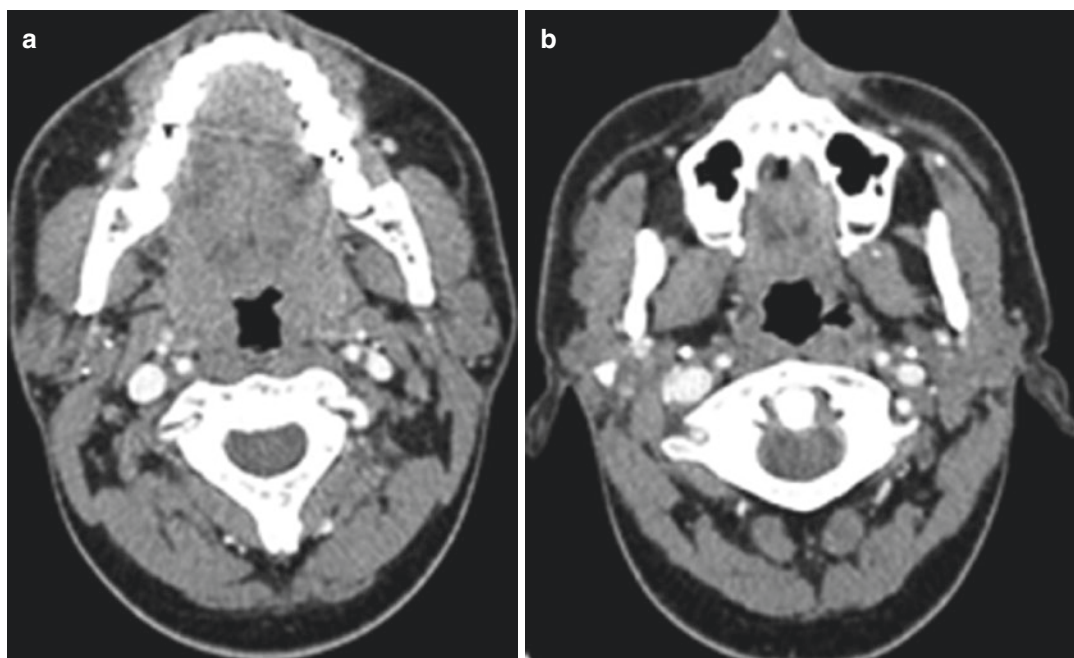


Fig. 20.9 CT demonstrating persistent right parotid stone with additional punctate parotid stones

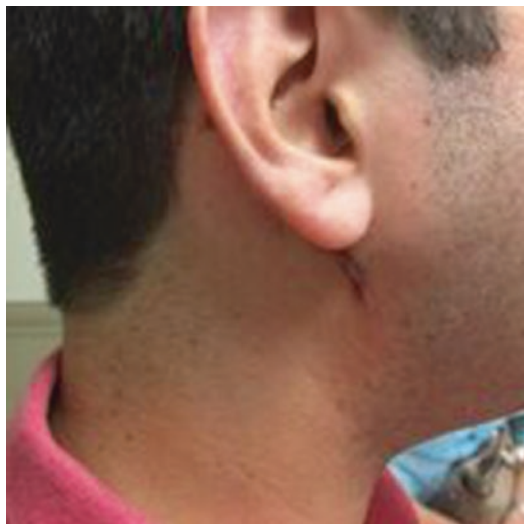

Fig. 20.10 Well-healed closure after ultrasound-guided transfacial incision of parotid stone via previous incision and drainage site

to the parotid. Ultrasound was used to identify the large stone and guide a needle against the stone to allow localization with dissection. Blunt dissection successfully delivered the large stone. The additional punctate stones were not retrieved.

Postoperatively, he did well. His symptoms resolved and his incision healed without fistula or difficulty (Fig. 20.10). Due to the punctate size and proximal location, observation was recommended for his additional stones. He remains without symptoms 7 months after his procedure.

Case 4

An 8-year-old male child presented with recurrent episodes of unilateral right sided parotid gland swellings. Over the last year the patient experienced four episodes of recurrent parotitis for which the patient was treated with medical conservation including antibiotic therapy and salivary gland hygiene. An outside CT scan was available for review; the imaging was unremarkable for obstructive pathology. The patient and parents did not report dry mouth or dry eyes or symptoms associated with meals. The past medical and surgical history was unremarkable.

On examination, the oral cavity was clear. There was no expressible saliva from both Stenson's papilla. No discrete masses were felt, neither was there any tenderness on palpation of the parotid and submandibular glands. However, the parents emphasized that the right parotid gland enlarges with associated pain during the acute episodes. No left parotid or submandibular symptoms. A clinical diagnosis of juvenile recurrent parotitis (JRP) was made.

After an appropriate consent was taken for right parotid endoscopy with infusion of Kenalog solution and possible stent placement. The procedure was performed under general anesthesia. Duct dilation was performed using standard mechanical dilation techniques using the Marchal dilators. Once the duct was dilated to up to No. 4 dilator, a diagnostic endoscopy was performed i.e. the endoscope was navigated to evaluate the main duct and secondary, tertiary branches of the ductal system. Findings, typical of JRP included narrow diffusely smaller (stenotic) ducts, blanched mucosa devoid of vascular markings on the ductal walls (normal is pink mucosa with vascular markings), debris and mucous plugs that were either irrigated out or removed with stone wire baskets (Fig. 20.11). In many cases of JRP, it is not unusual to find isolated ductal stenosis that may benefit from dilation using the salivary endoscope, balloon dilators, or metal/disposable dilator systems. If necessary, a stent can be placed if there is a papillary stenosis and need for sialodochoplasty. The position of the scope within the gland can be ascertained by transillumination (Fig. 20.12). Adequate gland irrigation and wash-out is indicated by observing and palpating an enlarging gland due to the endoscopic irrigation. Intervention was performed only on the symptomatic gland.

Postoperatively, the patient did well with same day discharge to home. The patient has been symptom free over 1 year. In the author's experience, patients with JRP benefit from endoscopic intervention either through long symptom-free periods or reduced intensity and frequency of episodes; both of which bring about significant quality of life improvement for both patients and parents.

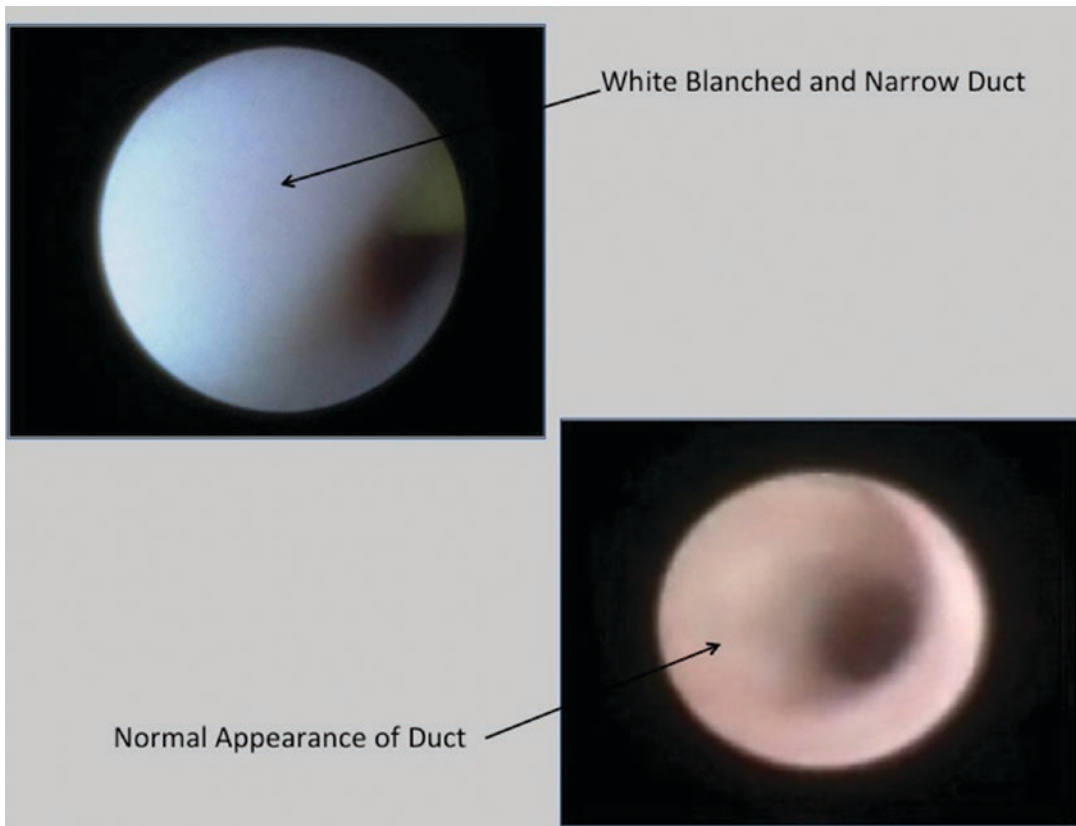


Fig. 20.11 Images comparing endoscopic view of normal salivary duct vs. patient with JRP

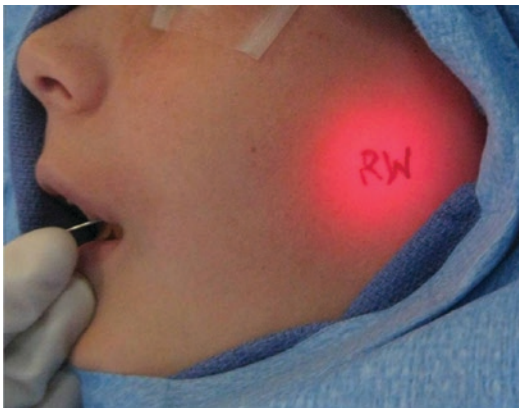

Fig. 20.12 Transillumination indicating position of the salivary endoscope within the parotid ductal system and gland parenchyma

Key Points

1. Recurrent non-suppurative swelling of the parotid gland in children without any evidence of obstructive disease should raise a suspicion of recurrent parotitis of childhood or juvenile recurrent parotitis (JRP).
2. JRP is self-limiting and symptoms resolve in teen years; parotidectomy is contraindicated for this reason.
3. Treatment goal includes reduction or resolution of symptoms, as well as reducing the intensity and frequency of episodes.
4. The diagnosis essentially clinical.
5. Salivary endoscopy, dilation and washout of the symptomatic gland(s) provide benefit and helps in achieving treatment goals.

6. Salivary gland washout may or may not be coupled with infusion of steroid (e.g. Kenalog) with equivalent results.
7. Postoperative antibiotics are a consideration. However, in the author's experience, perioperative antibiotics are sufficient.

Case 5

A 34-year-old man presented with left submandibular gland swelling for several years, asymptomatic with occasional left submandibular gland swelling. Recurrent symptoms prompted an evaluation and imaging that revealed a large 20 mm megalith in the left submandibular hilum on CT imaging (Fig. 20.13). The patient was otherwise healthy without significant past medical or relevant surgical history. On examination, oral cavity examination revealed a palpable posterior floor mouth sialolith. The left submandibular duct was

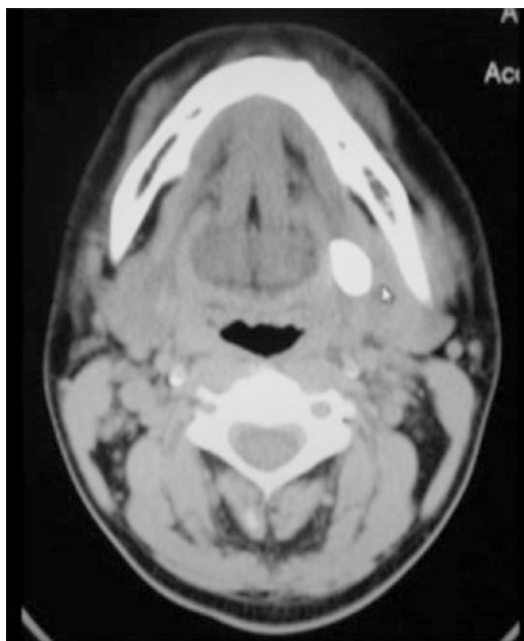


Fig. 20.13 Axial CT scan showing left submandibular hilar megalith (20 mm in maximum dimension)

patent. The patient did not want to have a submandibular gland excision.

After a discussion of options, he was taken to the operating room for sialendoscopy and combined approach stone removal with robotic assistance (Video 20.1). Lingual nerve and submandibular duct was clearly identified and stone was delivered via a sialolithotomy after which the duct was repaired over a Walvekar salivary duct stent; the stent was left in situ for 2 weeks and removed in the office. The postoperative evaluation after stent removal revealed a patent draining left submandibular duct (Fig. 20.14). The patient over the next few years was asymptomatic except for feeling increased salivation and gland engorgement that would resolve with gland massage.

After a symptom-free and stone-free period of 3 years, the patient presented with a left submandibular gland swelling that did not resolve with gland massage. An in-office ultrasound revealed a large dilated hilum, which could be decompressed with gland massage. Ultrasound repeated after “emptying” the gland revealed a second hypoechoic mass that could now be felt as a firm nodule on bimanual palpation. A CT scan of the

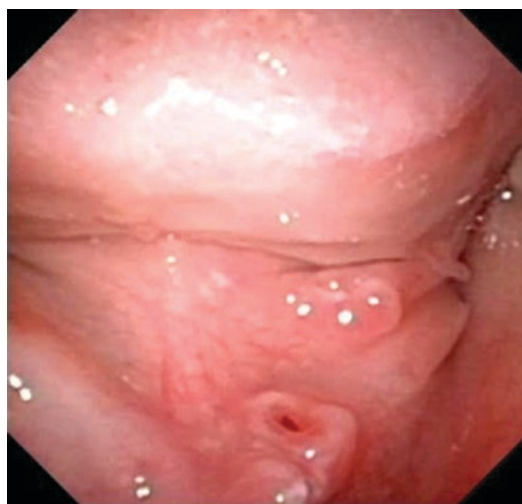

Fig. 20.14 Left submandibular papilla widely patent post-stent removal with good salivary flow

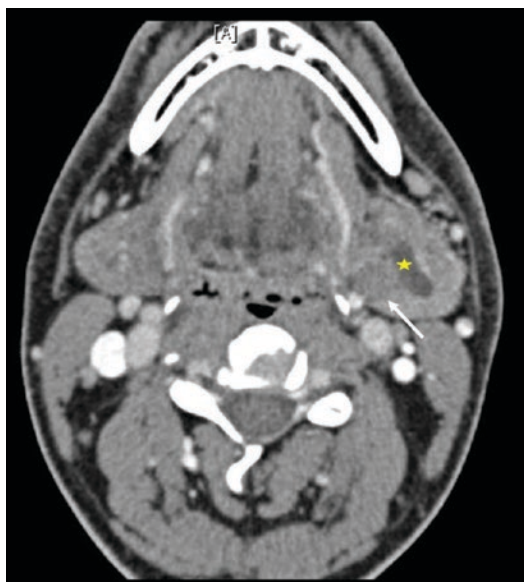


Fig. 20.15 Axial CT scan showing a dilated left submandibular duct post-stone removal (indicated by *yellow asterisk*) with a hypo lucent mass in the medial and posterior aspect of the gland (indicated by *white arrow*)

neck 1 mm cuts with and without contrast was ordered. The axial CT scan confirmed a left submandibular mass that was separate from the dilated submandibular hilum (Fig. 20.15). Fine needle aspiration biopsy and imaging confirmed a 1.8 cm pleomorphic adenoma of the left submandibular gland. The submandibular gland was subsequently excised via a transcervical incision with negative margins.

Post-operatively, the patient did well. The transcervical incision healed without complications. There was no marginal nerve paresis. The patient remains symptom-free and without recurrence 2 years after submandibular gland excision.

Key Points

- A large hilar submandibular stone is amenable to gland sparing techniques and can be managed using combined approach procedures with or without robotic assistance.
- Sialendoscopy is helpful in stone localization during combined approach technique and follow up diagnostic evaluations.
- In office ultrasound can provide great value in diagnosis of salivary gland pathology by

providing real time dynamic information. Ultrasound guided fine needle aspiration biopsy (FNAB) can accurately target lesions within the submandibular gland to confirm diagnosis of neoplastic disease.

- Sialolithiasis and salivary gland neoplasms are not exclusive of each other; suspicious clinical and imaging findings should prompt further investigation with additional imaging, ultrasound guided fine needle aspiration biopsy and if necessary gland removal.
- Sialolithiasis can “hide” neoplastic salivary gland disease. Persistent glandular swelling after successful stone removal should be investigated both for residual sialoliths and/or coincidental neoplastic disease.

Case 6

A 12-year-old male child was brought to the emergency room with pain and swelling of the right submandibular gland. The swelling was painful but there were no other associated symptoms such as dysphagia, shortness of breath or stridor. The patient was otherwise healthy without significant past medical history. Examination was consistent with acute sialadenitis. A stone could be palpated at the papilla of the right submandibular duct. A transoral stone removal was attempted in the ER without success. The patient underwent a salivary endoscopy after this initial acute episodes was treated with conservative management.

CT Imaging showed two stones; a more distal 5 mm stone and proximal 2–3 mm stone (Fig. 20.16). On endoscopy, the distal 5 mm stone had extruded to be partially embed into the submandibular ductal wall (Fig. 20.17). Sialendoscopy beyond this stone revealed the second, 2 mm hilar stone in a branching secondary duct; the 2 mm stone was not easily accessible to endoscopic removal since it was not within the line of site of the endoscope and consequently not amenable to endoscopic removal (Fig. 20.18). On attempting to reposition the 2 mm stone, a minor ductal tear occurred (Fig. 20.19). Continued endoscopic intervention

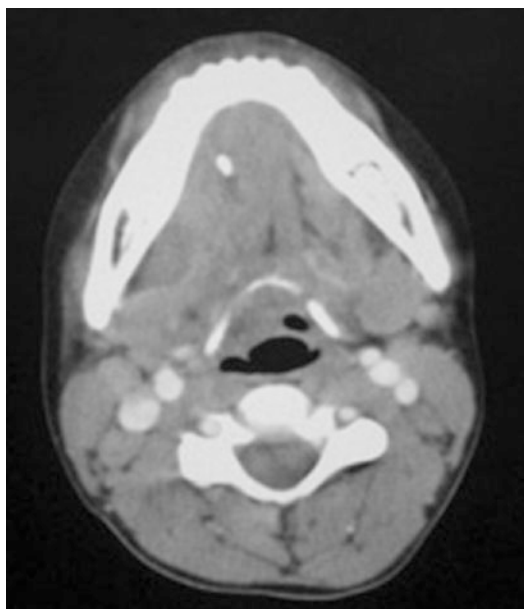


Fig. 20.16 Axial CT imaging showing 5 mm stone with ductal dilation and floor mouth edema consistent with acute sialadenitis

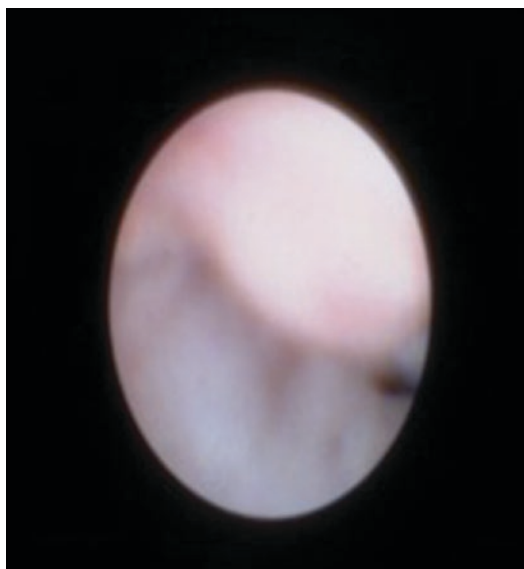


Fig. 20.17 Endoscopic view of the 5 mm stone embedded into the duct wall

and consequent saline infusion resulted in floor of mouth edema due to saline extravasation via the ductal tear. At this point, the endoscopic portion procedure was terminated; a floor mouth incision was made over the 5 mm stone and the stone was

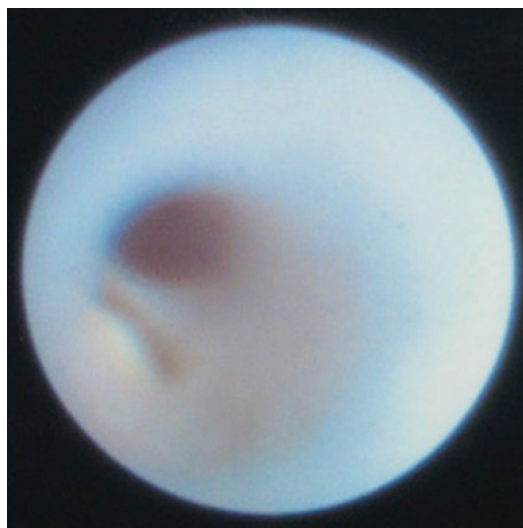


Fig. 20.18 2 mm distal stone lodged in a secondary branching duct inaccessible to endoscopic intervention

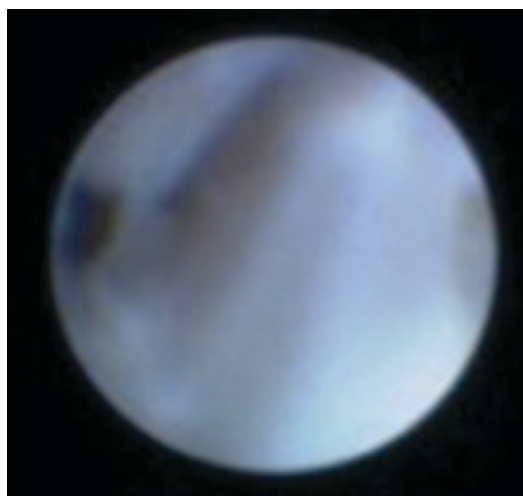


Fig. 20.19 Minor ductal tear due to endoscopic manipulation using stone baskets and guide wires

delivered. The floor mouth incision served two purposes, access for combined approach technique for removal of larger (5 mm) ductal stone and also a way to relieve floor of mouth pressure due to fluid entrapment. The 2 mm stone was left in situ, since it was small and not obstructing the main duct.

Despite the complex nature of the presentation and procedure, the patient did very well from the intervention; minimal swelling of the floor

mouth that subsided quickly and the patient was discharged the same day of surgery. The patient remained symptom free for 1 year; then presented with another episode of right submandibular gland swelling. CT imaging demonstrated 2–3 mm stone in more favorable orientation at the distal papilla. An endoscopic intervention was performed and stone removed endoscopically (Video 20.2). The patient and parents were satisfied with overall outcome and the patient remains symptom free.

Key Points

- Success of sialendoscopy and endoscopic stone removal depends on several factors such as endoscopic access, presence of absence of stenosis distal to the stone restricting access, ability to visualize the stone within line of sight of the endoscope and hence amenable to instrumentation. Adhesions or infiltration of the stone into the ductal wall favor combined techniques rather than pure endoscopic removal.
- Asymptomatic stones, which are not amenable to sialendoscopy, may be observed till they are symptomatic or present themselves in an orientation more amenable to endoscopic removal.
- Floor mouth edema can occur due to overzealous irrigation or ductal tear; floor of mouth incision can help relieve floor of mouth pressure and allow egress of extravasated irrigation.
- Simple transoral stone removal via papillotomy can be challenging at times. Papillary stenosis can be a complication that may continue to cause obstructive symptoms. Transoral stone removal is best-attempted if and endoscopy can be performed at the time of the papillotomy to identify and removal a stone that may not be apparent after the papillotomy is performed.

Pearls, Perils, and Learning Curve of Salivary Endoscopy

21

David M. Coggnetti and Joseph M. Curry

Key Points

1. Sialendoscopy has a learning curve, and surgeons should seek appropriate training.
2. Sialendoscopy equipment is fragile and requires attentive care.
3. Submandibular stones are more common than parotid stones and are typically easier to manage.
4. Sialendoscopy allows a gland-sparing approach for the vast majority of patients with sialolithiasis and other inflammatory disorders.

Introduction

Prior to the advent of sialendoscopy, treatment options for obstructive sialadenitis were limited. Conservative measures such as ductal dilation and sialodochoplasty rarely resolved the underlying etiology, whereas gland excision unnecessarily removed functional tissue in the vast majority of patients [1, 2]. Patients were left to choose between

the likelihood of ongoing symptoms or a scar with risks of open surgery. While the availability of sialendoscopy has risen significantly in the past 10 years, the above choice remains a reality for many patients who are not aware of the technology. Sialendoscopy permits endoscopic access to the salivary ductal system, and it can be used for both diagnostic and therapeutic purposes [3]. It offers gland-sparing treatment for obstructive and inflammatory salivary disorders. As both surgeons and patients increasingly realize its value, the interest in sialendoscopy by both groups will continue to grow.

As with any new procedure or technology, there is a learning curve with sialendoscopy. The learning curve takes place on a specialty level as new uses and accessory instruments are developed as well as with individual surgeons, reflected in physician comfort levels and outcomes [4–6]. It is the ethical duty of medical professionals to minimize the potential of negative impact of a learning curve on patient care. This is accomplished by appropriate training and education and by learning from the experiences, favorable and unfavorable, of oneself and others. The pearls and perils of these experiences are shared through many venues including training courses, specialty meetings, peer-reviewed journals, textbooks, and direct consultations, and they are valuable for both beginner and more experienced surgeons. This chapter reviews pearls and perils of sialendoscopy from initial training and case selection through the postoperative course.

Electronic Supplementary Material The online version of this chapter (https://doi.org/10.1007/978-3-319-58335-8_21) contains supplementary material, which is available to authorized users.

D.M. Coggnetti, M.D. (✉) • J.M. Curry, M.D.
Department of Otolaryngology—Head and Neck
Surgery, Sydney Kimmel Cancer Center, Thomas
Jefferson University, Philadelphia, PA 19107, USA
e-mail: david.coggnetti@jefferson.edu

Getting Started

Sialendoscopy will seem intuitive and familiar to most otolaryngologists. Experience with laryngoscopy, esophagoscopy, bronchoscopy, and nasal endoscopy affords a natural transition to endoscopy of the salivary ducts. While navigation of the salivary ductal lumen will not be technically challenging to most otolaryngologists and non-otolaryngologists alike, sialendoscopy does carry unique potential impediments. The difficulty with cannulation of the punctum, unfamiliarity with ductal anatomy, and the cost and fragility of the equipment can temper the enthusiasm of even the most ambitious surgeons. It behooves the beginner to take a formal sialendoscopy course prior to initiation in practice. Advantages of a course include hands-on experience with the equipment on animal and cadaveric models as well as access to expert instruction and advice. The temptation to learn on the go without a course should be avoided as most beginners would exhibit the “just enough knowledge to be dangerous” phenomenon. Courses are also beneficial for more experienced salivary endoscopists as they offer a venue to seek counsel and share ideas for difficult scenarios that have been encountered.

A thorough understanding of the anatomy of the salivary systems and surrounding structures is paramount for successful sialendoscopy. This is especially important for interventional approaches that require incisions and dissections through the surrounding tissue. While the oral cavity anatomy is familiar to otolaryngologists and oral surgeons, the deep floor of the mouth and deep buccal anatomy are rarely encountered in routine practice. Transoral and transcutaneous approaches to these areas result in different orientations of the same structures and require a surgeon to have a three-dimensional understanding of the anatomy. The relationship of the salivary ducts to surrounding muscles and nerves has important implications for both endoscopic and open (combined approach) sialendoscopy interventions. Due to the potential for complications, all surgeons embarking on sialendoscopy must have the proficiency to carry out gland excision as a salvage procedure.

An important first step in sialendoscopy is determining which equipment is needed. In general,

the equipment is expensive and fragile, and it can be the biggest impediment to practice initiation and growth. The endoscopes come in a variety of sizes, and there are an increasing number of tools available for access, intervention, and stenting. It is advisable that the beginner limit purchases to the most necessary equipment until experience and volume warrant expansion. Most experienced salivary endoscopists agree that a single-sized scope can serve as a “workhorse” and accommodate most beginner and intermediate level procedures. The 1.1 mm scope is well suited for both diagnostic and interventional use. Due to the fragility of the scopes, at least one backup scope is recommended to minimize the need to cancel or prematurely terminate a procedure. Commonly available medical equipment can be repurposed as access and stenting tools if necessary and is discussed in sections below.

Pearls: Take a training course; gain a thorough understanding of the anatomy; identify “workhorse” equipment.

Perils: Early frustration (lack of training, poor anatomic knowledge, poor early outcomes) and broken equipment.

Case Selection

The learning curve for sialendoscopy has been estimated to be between 30 and 50 cases [5, 6]. However, for most surgeons, case selection will have a bigger impact on success than technical ability, even early in one’s experience. The ability to recognize the feasibility of each case will optimize outcomes and minimize frustration. Treatment algorithms with regard to size and location of stones exist to guide case selection [7].

Small stones (<4 mm) are typically successfully managed with endoscopic basket retrieval. Large stones (>10 mm) are usually palpable in the submandibular duct, which lends well to successful open retrieval with a combined cutdown approach. The medium-size stones (4–10 mm) are frequently the most challenging cases as they are too large for endoscopic basket retrieval and may be too small to easily identify during a cutdown approach. Novice salivary endoscopists may waste time attempting to basket a stone that

is too large or attempting to dissect to a stone that is difficult to locate. Anticipating the role of cut-down approach, laser lithotripsy, or intraoperative ultrasound differentiates the experienced salivary endoscopists from the novice.

The location of a stone also impacts the likelihood of successful intervention. The more distal the location, the more accessible the stone is. The location is especially important in the parotid gland due to the difference in ductal anatomy compared to the submandibular gland. Proximal to its main branching point, the parotid duct continues to branch and be of sufficient size to allow development and trapping of stones. This portion of the parotid ductal tree is inaccessible with the rigid sialendoscope, and stones within these proximal branches are often not visualized endoscopically, thus limiting intervention for even the smallest stones. The posterior edge of the masseter muscle can be used as a line on preoperative imaging to predict the likelihood of endoscopic visualization of parotid stones (Fig. 21.1) ([8, 9]). The submandibular duct, on the other hand, has a much smaller intraglandular network due to

the smaller size and round shape of the submandibular gland. While many submandibular stones get trapped at the hilum of the gland, it is very rare for a submandibular stone to not be visualized on sialendoscopy.

In general, interventional sialendoscopy of the submandibular gland is more successful than the parotid gland [6]. Fortunately, sialolithiasis occurs less frequently in the parotid gland. A major difference between the two glands is the transoral access to the duct. Combined approaches with cutdown to the duct is accomplished transorally for the submandibular duct, which makes access and management of the duct much easier. Most parotid stones that require a cutdown to the duct, on the other hand, necessitate a transfacial approach [10]. An external approach results in scarring and risk to facial nerve branches and requires closure of the duct to prevent a sialoceles or salivary fistula. A sialolithotomy in the floor of the mouth does not require closure as any resultant fistula simply drains into the oral cavity.

Pearls: Treatment algorithms for size of stones; impact of stone location; interventional sialendoscopy of the submandibular gland is more successful.

Perils: Medium stones, proximal location, and parotid gland.

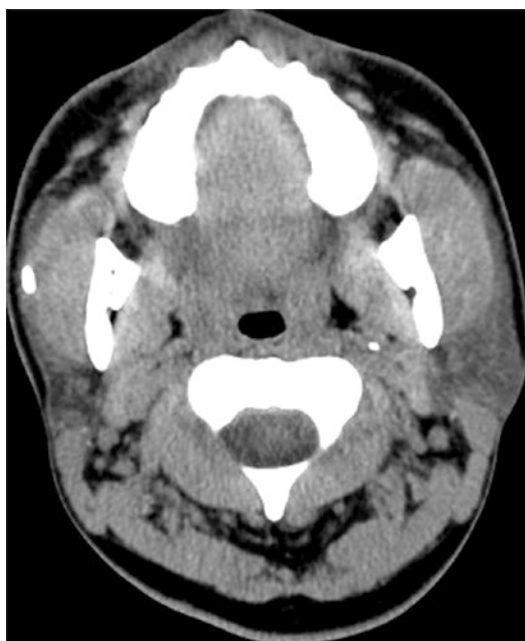

Fig. 21.1 A CT scan showing a stone in the midportion of the right parotid duct. Stones anterior to the posterior edge of the masseter muscle, such as this one, are typically visualized endoscopically. This stone was removed endoscopically with laser lithotripsy

Case Setup

Proper preparation and communication with the nursing and anesthesia teams are critical for successful outcome of sialendoscopy. Consideration must be given to airway management and oral exposure as well as to room setup and equipment needs (Fig. 21.2). A video tower or mounted video boom is required and is ideally situated at the head of the patient's bed. This can be to the side contralateral to where the surgeon is standing to facilitate viewing and preserve the midline for the anesthesiologist or a surgical assistant. The circulating nurse utilizes a back table and a mayo stand. The mayo stand is situated over the patient's midsection and is used to hold the endoscope when not in use. The mayo stand should be kept free of clutter to minimize inadvertent damage to the endoscope.

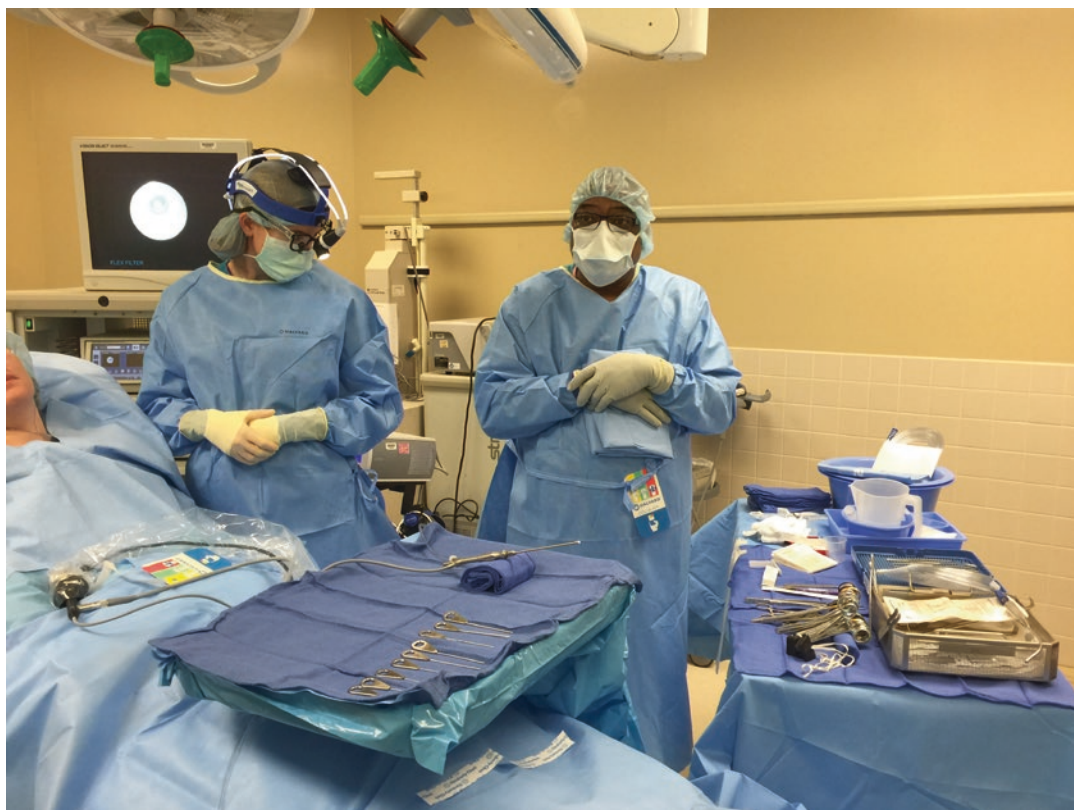

Fig. 21.2 Room setup for sialendoscopy. A video tower or boom is positioned off the head of the bed to facilitate viewing by the surgeon. The mayo stand is kept free of clutter with a separate back table for additional instrumentation

The endoscope is very fragile and can be easily broken in any step of its use or care. The integrity of the endoscope should be checked at the beginning and end of each case. During the case, the endoscope should be handed directly between personnel deliberately and with care. When not in use, the endoscope should be positioned on the mayo stand in a way to avoid pressure on its endoscopic portion. A rolled towel can be utilized to facilitate this (Fig. 21.3). The handle of the endoscope is rested on the rolled towel, and the endoscopic portion is elevated so that it has no contact with the table or other instruments. The camera and IV tubing attachments must be secured in a way to prevent inadvertent pull of the endoscope off of the table. When in use, the surgeon must exhibit care to avoid any torque on the endoscope. Even a wipe or dab of the tip of the endoscope, habits engrained in endoscopic sinus surgeons, can be enough to fracture the endoscope.

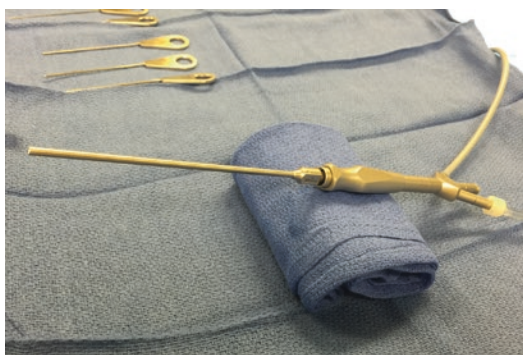

Fig. 21.3 Towel roll to protect the endoscope. The endoscope is very fragile. Care must be taken to avoid pressure on its endoscopic portion

The camera should be focused and white balanced prior to entry of the endoscope into the patient. It is important to make sure that the orientation of the camera attachment to the endoscope matches the orientation of the view on the

screen. Otherwise, the surgeon will not be able to navigate the duct. Typically, the surgeon should use no more than 30–35% light power.

Since the Wharton papillae are behind the dentition, the jaw must be propped open for submandibular duct access. Either a rubber bite block or a side-biting mouth gag (Denhardt) is utilized for this. These instruments are placed contralateral to the side of the procedure. Parotid cases can be performed with the teeth in occlusion as the Stensen's papillae exist external to the dentition. In fact, wide opening of the mouth creates tension in the buccinator and masseter muscles which may make scope insertion and advancement more difficult. In these cases, a soft tissue retractor or the surgeon's thumb is used to retract the cheek.

Pearls: Position the video monitor at the head of bed contralateral to the surgeon; Handle the scope with care; Bite block or mouth gag for submandibular cases.

Perils: Room setup that does not facilitate video monitor viewing; inability to navigate the duct due to incorrect camera orientation; and case cancelation or early termination due to broken scope.

Anesthesia

Depending on the level of intervention, sialendoscopy can be accomplished under all levels of anesthesia: local, sedation, and general [11]. Local anesthesia can be accomplished with the patient in the seated position in an office setting. Sedation is accomplished with the patient in the seated position with the head of bed in the direction of the anesthesia team. General anesthesia is recommended during the surgeon's learning curve and for cases with significant intervention anticipated. Both the surgeon and the patient must be comfortable with an awake or sedated approach for it to be successful. For cases under general anesthesia, it is helpful to spin the bed 180° with the head away from the anesthesia team to allow more room for the video tower and the surgical team.

For cases under local anesthesia, patients tolerate ductal dilation without any local injection.

This allows identification and cannulation of the duct without distortion of the anatomy caused by the soft tissue infiltration of the anesthetic. Once the surgeon has confidently identified the punctum, injection with 1–2 cc of lidocaine with epinephrine around the papilla is performed to minimize discomfort with cannulation of the endoscope and to permit papillotomy if the intervention requires it. Initial irrigation of the duct with 2–3 cc of plain lidocaine with a 25-gauge angiocatheter alleviates patient discomfort from ductal expansion. For cases under sedation, it is important that the anesthesia team titrates the sedative to keep the patient awake and cooperative. Midazolam and/or fentanyl are typically sufficient to accomplish this goal. In all cases, anticholinergic agents such as glycopyrrolate should be avoided due to the drying effect on salivary secretions.

When general anesthesia is required, some surgeons favor nasal intubation for sialendoscopy [12]. While this improves oral access and exposure, the vast majority of cases can be accomplished with oral intubation with the endotracheal tube secured to the contralateral corner of the mouth. Oral intubation is easier for the anesthesia team and avoids the potential nasal and uvular trauma that can occur with nasal intubation. Nasal intubation may be needed in patients with narrow jaw structure or large tongue. The benefit of nasal intubation is most realized in cases with bilateral submandibular intervention. Parotid sialendoscopy limited to diagnostic exploration or endoscopic intervention is an ideal case for local or sedation. In parotid cases requiring general anesthesia and bilateral intervention, an oral endotracheal tube can be secured in the midline.

Pearls: Local anesthesia with or without sedation are options for diagnostic and limited intervention cases; general anesthesia is recommended if there is any question of surgeon or patient comfort; nasal intubation is helpful for cases requiring access to bilateral submandibular ducts.

Perils: Local anesthesia infiltration impeding identification of punctum; anticholinergic medications eliminating salivary production; oversedation of awake patients; and trauma from nasal intubation.

Ductal Access

The first procedural step in the sialendoscopy is identification and cannulation of the duct. It is important to direct attention to the punctum on preoperative evaluation. The location on the papilla as well as surrounding anatomic features such as mandibular tori, tall mandibular incisors, and scarring from previous interventions or infections will help predict the ease of cannulation of the punctum. The best way to identify the punctum is to express saliva from the duct (Video 21.1). This is accomplished by massaging the gland and sliding one's finger along the course of the duct to milk the saliva forward. There is a finite amount of saliva within the ductal system, so one should limit expression of the saliva until the case is setup and the surgeon is ready to dilate the punctum. As discussed above, anticholinergics should be avoided as they will inhibit salivary production and interfere with identification of the punctum with this method. The use of methylene blue has been described as a way to enhance the view of salivary expression by creating visual contrast between the saliva being expressed and the surrounding pooled secretions and mucosal surfaces [13]. Vitamin C can stimulate salivary production and expression; however, its use must be discussed with the anesthesia team. If saliva cannot be expressed from the duct of interest, expression of saliva from the punctum of its paired gland may be helpful by comparing the mirroring anatomy.

Once the punctum is identified, it is dilated. This is typically easier for the parotid duct. The submandibular punctum is smaller and can sit on a taller papilla, resulting in floppy mucosa that is more difficult to stabilize. The non-dominant hand of the surgeon uses a piece of gauze to create tension on the surrounding mucosa. The use of a forceps should be avoided as it can distort the anatomy, and even a small dimple from the tine of the instrument can result in the dilators preferentially falling into the dimple instead of the punctum. Successful dilation is aided by having an assortment of dilator shapes and sizes. The smallest dilator (0000) is always used first. Dilators are then sequentially increased in size

(Video 21.2). The direction of the ductal course should be noted and mimicked for subsequent dilators and the passage of the endoscope. After the size 1 or 2 dilator, the conical-shaped dilator is used to enlarge the punctum enough to allow passage of the endoscope. If difficulty with sequential dilation is identified or anticipated, then a guidewire is passed and used for dilation with Seldinger technique [14]. This is typically only necessary for the submandibular duct. Seldinger technique can be accomplished with hollow rigid bougies (Storz) or with flexible bougies (Cook Medical). Papillotomies prior to ductal cannulation should be avoided as it will complicate intubation of the duct, not facilitate it. If multiple reentries are anticipated in interventional submandibular cases, then a 16-gauge angiocatheter (non-FDA approved use) or the Kolenda Introducer Sheath (Cook Medical) can be used as a trocar to maintain ductal access.

The purpose of dilation is to enlarge the punctum for entry of the endoscope. The dilators should not be passed deep within the duct, as this is unnecessary for enlargement of the punctum and increases the risk of ductal trauma. The dilators should never be passed against resistance, as this will lead to ductal perforation and creation of a false passage. If in proper location, minimal force should be required to pass the dilators, and the dilators should feel as if they are gliding with gravity. It is not uncommon to meet resistance with the dilator at 1–2 cm from the punctum in the parotid due to a turn in the duct as it crosses the anterior edge of the masseter [15]. In this situation, it is best to limit dilation to the punctum and manage the area of resistance with direct visualization after endoscope entry.

In the rare situation that the punctum cannot be identified or cannulated, the duct can be accessed via an incision near the papilla [16]. This should only be pursued after all other measures have been exhausted. For the submandibular duct, the incision is made just posterior and lateral to the papilla. Blunt dissection is used to identify the duct. A stitch is placed in the side-wall of the duct, and the duct is incised along its course. At the conclusion of the procedure, the ductal opening is suspended to the surrounding

mucosa. For the parotid gland, a curvilinear incision is made in the mucosa just anterior to the papilla. The duct is identified and managed in a similar fashion.

Pearls: Expression of saliva is the best way to identify the punctum; always start with the smallest (0000) dilator; a guidewire and Seldinger technique can facilitate dilation of the submandibular punctum in difficult cases.

Perils: Manipulation and distortion of the papilla prior to ductal cannulation; ductal trauma or perforation from over-insertion of dilators; and inability to cannulate the punctum.

Navigation

Once the punctum is dilated, the endoscope is passed. Saline irrigation is utilized for expansion and visualization of the duct. It is often easier to identify the lumen by passing the scope a few centimeters (assuming no resistance) and looking for the lumen during scope withdrawal, as is done in esophagoscopy. Saline instillation can be accomplished by an assistant via a syringe attached with IV tubing to the irrigation port of the scope. Due to the small caliber of the scope, it can take significant pressure for the assistant to push the saline. This can be facilitated by the use of smaller caliber saline syringes (3–10 cc), with a handheld pressure???? (need name of instrument.), a segment of IV tubing, or with powered irrigation with the use of an electronic pump, such as the Integrated Power Console (Medtronic) used in sinus surgery. Powered irrigation has the advantage of being under the direct control of the surgeon through the use of a foot pedal. With any of the saline instillation methods, over-irrigation must be avoided as it can lead to rupture of the duct wall and infiltration of the surrounding soft tissue [17]. In submandibular cases, this can lead to significant floor of the mouth edema with airway implications. When irrigation is occurring, the working channel of the endoscope should be left open as an escape valve for intraductal pressure, and drainage of saline from the working channel is expected. If powered irrigation is utilized, it should be performed on the lowest setting.

In addition, the surgeon can take a moment to massage the gland in between scope insertions in order to empty the gland of excess irrigate.

Although the submandibular duct can be more difficult to cannulate, it is typically easier to navigate than the parotid duct. The parotid duct is narrower, has a sharp turn as it crosses the anterior edge of the masseter, and can frequently be tortuous in its route. Additionally, navigation of the proximal parotid system is limited by the branching and caliber of the duct within the parotid parenchyma.

Pearls: Identification of duct during scope withdrawal; powered irrigation for saline instillation; submandibular duct is easier to navigate.

Perils: Blind advance of scope leading to ductal perforation; over-irrigation leading to ductal tear and saline extravasation; and masseteric bend in the parotid duct limiting navigation.

Interventional Sialendoscopy

Sialolithiasis is the most common reason for interventional sialendoscopy [18]. This occurs at a 3:1 submandibular/parotid ratio due to differences in the ductal anatomy and salivary composition between the two glands. This ratio is fortunate as the management of submandibular sialolithiasis tends to be easier and more successful [6]. Stones smaller than 4 mm are typically retrievable endoscopically with a wire basket. When a stone is visualized in the duct, its size compared to lumen diameter, shape, orientation within the duct, location with regard to narrow areas and branch points, and whether or not it is floating within the lumen will all predict the likelihood of basket retrieval [19, 20]. Often the stone can be drawn with the basket to the papilla but can be too large to pull through the punctum. For this a papillotomy with a #11 blade will permit delivery (Video 21.3). In doing this, the surgeon must be mindful not to cut the basket itself. This could release the stone, or worse release a portion of the basket into the duct. If the basket gets caught along the duct, then a cutdown approach will be required. Care must be made not to exert too much traction of a caught basket

as it could result in ductal avulsion [21]. The baskets are also fragile and must be gently handled.

Larger submandibular stones usually get caught in the proximal duct or hilum. On imaging and physical examination, they can be found at the anteromedial aspect of the gland. On physical examination, they are best appreciated with bimanual palpation or sonopalpation with ultrasound [22]. For these stones, a cutdown approach in the posterior floor of the mouth is required [19, 20]. The location of the incision can be estimated with palpation and sialendoscopy visualization. Typically, this is medial to the first and second molar teeth. The incision should be placed laterally in the floor of the mouth to minimize mucosal overhang during dissection. Sharp dissection is limited to the mucosa itself to prevent injury to the lingual nerve. The submandibular duct crosses under the lingual nerve in the posterior floor of the mouth as it courses into the gland. The lingual nerve should be identified with blunt dissection and will frequently need to be displaced laterally to allow access to the stone. The sialolithotomy should always be made in the direction of the duct to prevent transection of the duct. Once the stone is delivered, sialendoscopy is repeated. It is not uncommon to identify an additional stone or fragments of stone [19, 20]. These can be irrigated through the sialolithotomy or retrieved with a wire basket. Sialendoscopy also permits the evaluation of the integrity of the duct after a cutdown approach.

Parotid stones are more challenging than submandibular stones [6]. The location of the stone along the masseter muscle may be more predictive of the approach and success of a sialendoscopy-assisted intervention than the size of the stone itself (Galinat 2016; [9]). Parotid stones anterior to the anterior edge of the masseter muscle can typically be managed transorally, even if the size of the stone necessitates a cutdown approach. Stones anterior to the posterior edge of the masseter muscle will be visible endoscopically and can be managed according to size. Treatment options include wire retrieval, manual or laser lithotripsy, and transfacial cutdown approach [23, 24]. Stones posterior to the edge of the masseter muscle are frequently not visualized

regardless of size. If a stone cannot be visualized endoscopically, then endoscopic management is not an option. Treatment options for stones in this location include medical management, ultrasound-guided transfacial cutdown approach, and parotidectomy. This decision is driven by the size of stone and patient symptomatology.

Lithotripsy can be utilized to fragment stones to facilitate removal. Extracorporeal lithotripsy is not available in the United States and is limited by the need for multiple treatment sessions and a modest success rate [25]. Sialendoscopy can be used for endoscopic lithotripsy. A manual burr is available but is limited in its efficacy. Frequently the stone pushes away from the burr, and most surgeons will find its use tedious and frustrating. Most commonly, the holmium laser is utilized [26]. As this is off-label use of the laser, the surgeon must discuss it clearly with the patient and obtain appropriate hospital credentials. While effective, laser lithotripsy is also time-consuming. As such, it is rarely favored over a cutdown approach for larger stones. Its ideal application is for the medium stones that would be a challenge for a cutdown approach. The biggest concern with the use of the laser is thermal damage. One must be careful not to engage the laser too close to the duct wall as it could potentially lead to perforation, scarring, or stricture. Additionally, if the laser is fired within or close to the tip of the endoscope, it will destroy the endoscope. A pneumatic lithotripter is in development and holds promise to eliminate the thermal problem [27, 28].

Other applications of sialendoscopy include inflammatory disorders, such as Sjogren's disease, juvenile recurrent parotitis, and radioactive iodine-induced sialadenitis, as well as anatomic obstruction from focal strictures or ductal stenosis [29–33]. The clearance of ductal debris and mucus plugging as well as irrigation with triamcinolone acetonide can assist in inflammatory cases. It is important to manage patient expectations, as these interventions will not improve the xerostomia that frequently coexists in these conditions. For stricture cases, bougie and balloon dilators can help open the duct and improve salivary flow.

Pearls: Endoscopic evaluation to predict success of wire basket retrieval; bimanual palpation to identify stones; identification of lingual nerve in submandibular cutdown approach; and lithotripsy for difficult medium-sized stones.

Perils: Trapped or broken wire basket; lingual nerve injury; thermal damage from laser; and non-visualized stones.

Closure/Stenting

Endoscopic procedures rarely require stenting. The exception would be in the case of laser lithotripsy of a parotid stone that has evidence of ductal trauma. For submandibular cutdown approaches, the floor of the mouth mucosa does not require closure. It heals very quickly on its own, and the effort to suture the mucosa back together is not warranted. The submandibular duct can be managed similarly. Closure is not required and may actually contribute to stricture formation. Additionally, fistula formation into the floor of the mouth is not a problem as it is consistent with the physiologic intent for saliva. For the submandibular gland, stenting can be limited to cases with an extended papillotomy or with significant ductal injury or repair. Management of the parotid duct differs from the submandibular duct due to the distance of the parotid duct's course from the oral cavity. For this same reason, most cutdown approaches to the parotid duct are via an external approach. As such, a sialolithotomy of the parotid duct requires meticulous closure over a stent to prevent a sialocele, infection, or salivary fistula. In the past, stenting was limited to off-label items such as angiocatheters and pediatric feeding tubes. Salivary stents have recently been developed that are easier to place for the surgeon and more comfortable for the patient. Stents are secured to the oral mucosa with a nylon suture and are removed in 1–2 weeks at the discretion of the surgeon. Due to the rapid turnover of the oral mucosa, the suture and stent may extrude early. Patients should be warned of this possibility.

Pearls: Closure and stenting are rarely required in the submandibular duct; closure and

stenting are required for any transfacial cutdown approach to a parotid duct stone.

Perils: Frustration from attempting posterior floor of the mouth and submandibular duct closure; and sialocele, infection, or salivary fistula after parotid duct sialolithotomy.

Postoperative Course

Almost all patients are discharged to home the same day. Antibiotics are rarely required. Patients can resume a regular diet with instructions to rinse after meals and to be careful of any sialolithotomy site while brushing the teeth. Most patients experience minimal pain and tolerate the procedure well. Patients will experience swelling of the gland in the first few days after the procedure due to intraoperative manipulation and irrigation. Patients should be warned of this and instructed to massage the gland and maintain hydration. Postoperative appointments take place 1–2 weeks following the procedure. Salivary flow should be assessed on examination at that time. Successful removal of an obstructive stone will typically result in long-term resolution of symptoms. The goal in inflammatory disorders is control of symptoms. A second follow-up appointment is scheduled for 3–4 months later but is rarely kept by patients due to lack of symptoms. These appointments are ideal for telephone or telemedicine assessment. Long-term follow-up is as needed.

Pearls: Outpatient procedure; no dietary restrictions; and telephone or telemedicine follow-up.

Perils: Dehydration and ongoing inflammatory symptoms.

Conclusion

Sialendoscopy has revolutionized the management of salivary disorders. Gland-sparing relief of symptoms is possible in the vast majority of patients. An understanding of the treatment options and the recognition of the therapeutic limitations of those options will guide a surgeon to optimal patient outcome.

References

1. Marchal F, Kurt AM, Dulguerov P, Becker M, Oedman M, Lehmann W. Histopathology of submandibular glands removed for sialolithiasis. *Ann Otol Rhinol Laryngol*. 2001;110(5 Pt 1):464–9.
2. Su YX, Xu JH, Liao GQ, Zheng GS, Cheng MH, Han L, Shan H. Salivary gland functional recovery after sialendoscopy. *Laryngoscope*. 2009;119(4):646–52. doi:[10.1002/lary.20128](https://doi.org/10.1002/lary.20128).
3. Zenk J, Koch M, Klintworth N, König B, Konz K, Gillespie MB, Iro H. Sialendoscopy in the diagnosis and treatment of sialolithiasis: a study on more than 1000 patients. *Otolaryngol Head Neck Surg*. 2012;147(5):858–63. doi:[10.1177/0194599812452837](https://doi.org/10.1177/0194599812452837).
4. Farneti P, Macri G, Gramellini G, Ghirelli M, Tesei F, Pasquini E. Learning curve in diagnostic and interventional sialendoscopy for obstructive salivary diseases. *Acta Otorhinolaryngol Ital*. 2015;35(5):325–31. doi:[10.14639/0392-100X-352](https://doi.org/10.14639/0392-100X-352). Review. PubMed PMID: 26824914; PubMed Central PMCID: PMC4720929
5. Luers JC, Damm M, Klusmann JP, Beutner D. The learning curve of sialendoscopy with modular sialendoscopes: a single surgeon's experience. *Arch Otolaryngol Head Neck Surg*. 2010;136(8):762–5. doi:[10.1001/archoto.2010.109](https://doi.org/10.1001/archoto.2010.109).
6. Modest MC, Galinat L, Rabinowitz MR, Curry JM, Rosen D, Cognetti DM. Learning progression in the use of sialendoscopy for sialolithiasis: effect on gland preservation. *Otolaryngol Head Neck Surg*. 2014;151(2):240–5.
7. Marchal F, Dulguerov P. Sialolithiasis management: the state of the art. *Arch Otolaryngol Head Neck Surg*. 2003;129(9):951–6.
8. Galinat L, Curry J, Luginbuhl, et al. Nonvisualization of sialoliths during sialendoscopy. *Otolaryngol Head Neck Surg*. 2016;154:1019–22.
9. Kiringoda R, Eisele DW, Chang JLA. Comparison of parotid imaging characteristics and sialendoscopic findings in obstructive salivary disorders. *Laryngoscope*. 2014;124(12):2696–701. doi:[10.1002/lary.24787](https://doi.org/10.1002/lary.24787).
10. Koch M, Bozzato A, Iro H, Zenk J. Combined endoscopic and transcutaneous approach for parotid gland sialolithiasis: indications, technique, and results. *Otolaryngol Head Neck Surg*. 2010;142(1):98–103. doi:[10.1016/j.otohns.2009.10.022](https://doi.org/10.1016/j.otohns.2009.10.022).
11. Luers JC, Stenner M, Schinke M, Helmstaedter V, Beutner D. Tolerability of sialendoscopy under local anesthesia. *Ann Otol Rhinol Laryngol*. 2012;121(4):269–74.
12. Witt RL, Iro H, Koch M, McGurk M, Nahlieli O, Zenk J. Minimally invasive options for salivary calculi. *Laryngoscope*. 2012;122(6):1306–11. doi:[10.1002/lary.23272](https://doi.org/10.1002/lary.23272).
13. Luers JC, Vent J, Beutner D. Methylene blue for easy and safe detection of salivary duct papilla in sialendoscopy. *Otolaryngol Head Neck Surg*. 2008;139:466–7.
14. Chossegros C, Guyot L, Richard O, Barki G, Marchal F. A technical improvement in sialendoscopy to enter the salivary ducts. *Laryngoscope*. 2006;116:842–4.
15. Reddy R, White DR, Gillespie MB. Obstructive parotitis secondary to an acute masseteric bend. *ORL J Otorhinolaryngol Relat Spec*. 2012;74(1):12–5. doi:[10.1159/000334246](https://doi.org/10.1159/000334246).
16. Chang JL, Eisele DW. Limited distal sialodochotomy to facilitate sialendoscopy of the submandibular duct. *Laryngoscope*. 2013;123(5):1163–7. doi:[10.1002/lary.23801](https://doi.org/10.1002/lary.23801).
17. Luers JC, Ortmann M, Beutner D, Hüttenbrink KB. Intraductal pressure during sialendoscopy. *J Laryngol Otol*. 2014;128(10):897–901. doi:[10.1017/S0022215114001959](https://doi.org/10.1017/S0022215114001959).
18. Laaksonen J, Haapaniemi A, Ojala J, Mäkitie A, Saarinen R. Sialendoscopy in sialadenitis: an unselected cohort of 228 patients. *Clin Otolaryngol*. 2016;41(4):416–20. doi:[10.1111/coa.12531](https://doi.org/10.1111/coa.12531).
19. Walvekar RR, Carrau RL, Schaitkin B. Endoscopic sialolith removal: orientation and shape as predictors of success. *Am J Otolaryngol*. 2009;30(3):153–6. doi:[10.1016/j.amjoto.2008.03.007](https://doi.org/10.1016/j.amjoto.2008.03.007).
20. Walvekar RR, Bomeli SR, Carrau RL, Schaitkin B. Combined approach technique for the management of large salivary stones. *Laryngoscope*. 2009;119(6):1125–9. doi:[10.1002/lary.20203](https://doi.org/10.1002/lary.20203).
21. Nahlieli O. Complications of sialendoscopy: personal experience, literature analysis, and suggestions. *J Oral Maxillofac Surg*. 2015;73(1):75–80. doi:[10.1016/j.joms.2014.07.028](https://doi.org/10.1016/j.joms.2014.07.028).
22. Patel NJ, Hashemi S, Joshi AS. Sonopalpation: a novel application of ultrasound for detection of submandibular calculi. *Otolaryngol Head Neck Surg*. 2014;151(5):770–5. doi:[10.1177/0194599814545736](https://doi.org/10.1177/0194599814545736).
23. Durbec M, Dinkel E, Vigier S, Disant F, Marchal F, Faure F. Thulium-YAG laser sialendoscopy for parotid and submandibular sialolithiasis. *Lasers Surg Med*. 2012;44(10):783–6. doi:[10.1002/lsm.22094](https://doi.org/10.1002/lsm.22094).
24. Su CH, Lee KS, Tseng TM, Hung SH. Endoscopic holmium:YAG laser-assisted lithotripsy: a preliminary report. *B-ENT*. 2015;11(1):57–61.
25. Schmitz S, Zengel P, Alvir I, Andratschke M, Berghaus A, Lang S. Long-term evaluation of extracorporeal shock wave lithotripsy in the treatment of salivary stones. *J Laryngol Otol*. 2008;122(1):65–71.
26. Phillips J, Withrow K. Outcomes of holmium laser-assisted lithotripsy with sialendoscopy in treatment of sialolithiasis. *Otolaryngol Head Neck Surg*. 2014;150(6):962–7. doi:[10.1177/0194599814524716](https://doi.org/10.1177/0194599814524716).
27. Hoffman HT, Walvekar RR, Tracy CR, Kolenda J, Pagedar N. Endoscopic salivary stone fragmentation with pneumatic lithotripsy in a simulation model. *Otolaryngol Head Neck Surg*. 2016;154(3):454–9. doi:[10.1177/0194599815626138](https://doi.org/10.1177/0194599815626138).
28. Koch M, Mantsopoulos K, Schapher M, von Scotti F, Iro H. Intraductal pneumatic lithotripsy for salivary

- stones with the StoneBreaker: preliminary experience. *Laryngoscope*. 2016;126(7):1545–50. doi:[10.1002/lary.25849](https://doi.org/10.1002/lary.25849).
29. Bhayani MK, Acharya V, Kongkiatkamon S, Farah S, Roberts DB, Sterba J, Chambers MS, Lai SY. Sialendoscopy for patients with radioiodine-induced sialadenitis and xerostomia. *Thyroid*. 2015;25(7):834–8. doi:[10.1089/thy.2014.0572](https://doi.org/10.1089/thy.2014.0572).
30. Bomeli SR, Schaitkin B, Carrau RL, Walvekar RR. Interventional sialendoscopy for treatment of radioiodine-induced sialadenitis. *Laryngoscope*. 2009;119(5):864–7. doi:[10.1002/lary.20140](https://doi.org/10.1002/lary.20140).
31. Jager DJ, Karagozoglu KH, Maarse F, Brand HS, Forouzanfar T. Sialendoscopy of salivary glands affected by Sjögren syndrome: a randomized controlled pilot study. *J Oral Maxillofac Surg*. 2016;74(6):1167–74. doi:[10.1016/j.joms.2015.12.019](https://doi.org/10.1016/j.joms.2015.12.019).
32. Kim YM, Choi JS, Hong SB, Hyun IY, Lim JY. Salivary gland function after sialendoscopy for treatment of chronic radioiodine-induced sialadenitis. *Head Neck*. 2016;38(1):51–8. doi:[10.1002/hed.23844](https://doi.org/10.1002/hed.23844).
33. Koch M, Iro H, Zenk J. Sialendoscopy-based diagnosis and classification of parotid duct stenoses. *Laryngoscope*. 2009;119(9):1696–703. doi:[10.1002/lary.20522](https://doi.org/10.1002/lary.20522).

Jack Kolenda

Key Points

1. The equipment and techniques for sialendoscopy continue to evolve and therefore will require ongoing learning by sialoendoscopists.
2. Surgeons must take an active role in the care and processing of salivary scopes due to their fragility.
3. A variety of reusable and disposable equipment should be on hand in order to successfully manage challenging sialendoscopy cases.

Introduction

Sialendoscopy is performed for diagnostic and curative purposes [1]. The procedure can be carried out under local or general anesthesia depending on surgeon preference. Most surgeons follow similar protocols for preoperative preparation and intraoperative intervention, but each surgeon has adopted some unique technique or borrowed a surgical tool from some other head and neck surgery we perform.

Previous authors have outlined the imaging workup that can be utilized to arrive at the diagno-

sis of the etiology of benign salivary swelling. Diagnostic sialendoscopy is an important tool in the workup [2]. The author strongly favors performing diagnostic sialendoscopy prior to proceeding to interventional sialendoscopy. In many practices in North America, interventional sialendoscopy is performed in an operating room setting either with sedation or general anesthesia. Diagnostic sialendoscopy can serve the same pre-planning purpose as does a CT scan prior to performing FESS. Important information can be gained that sometimes can be missed by a number of imaging studies in the same patient. It is not uncommon to discover findings on an endoscopic examination that were missed by imaging. For example, a stone has been visualized in the submandibular duct, but both CT and sialogram imaging failed to show a complete stenosis being present just in front of the stone that is easily detected on endoscopy. Parotid glands have a higher preponderance of stenosis development [3]. These can be the sole cause of the obstruction or may be present along with the sialolith. Performance of office diagnostic sialendoscopy can inform the surgeon whether a stone is the only pathology or if a stenosis is also present. The degree of stenosis can be appreciated much better on direct vision and can influence the future choice of intervention that will be proposed.

In terms of preoperative preparation, administration of sialagogues in the preoperative setting of salivary endoscopy patients allows for visualization

J. Kolenda, M.D.
Department of Otolaryngology, Oakville Trafalgar
Hospital, Oakville, ON, Canada
St. Joseph's Health Centre, Toronto, ON, Canada
University of Toronto, Toronto, ON, Canada
e-mail: jackkolenda@gmail.com

of saliva flow from the papilla which is important for establishing the location of the duct opening. This is especially important in localization of the Warthin's duct papilla which in certain cases can take some time to locate. If sialendoscopy is to be performed under local anesthesia, there are some centers where patients will be instructed to consume a meal a half hour or an hour prior to the procedure in order to produce salivation. Others employ variable sialagogues such as sour candies, slices of lemon, and lemon juice to stimulate salivary flow. Patient undergoing general anesthesia administration is often not permitted to have sialagogues in the immediate preoperative period. However, the author has found that preoperative administration of lemon juice, 20 min prior to induction of general anesthesia, is helpful in stimulating salivary flow and identification of the papilla, especially relating to the Wharton's duct, while this protocol has not resulted in adverse events such as aspiration or lung infections.

The current sialendoscopes are fragile instruments. Hospitals and surgical centers rely on central processing departments for cleaning and sterilization of endoscopes. Unfortunately, anecdotal evidence from most high-volume centers that have been performing sialendoscopies for a long time has encountered the frequent breakage of these scopes during processing. In an ideal world, one person in the central processing department should be in charge of processing these fragile scopes; this would ensure higher longevity. From a practical and best practices standpoint, it is important to have two salivary endoscopes available for each case to avoid having to cancel due to unexpected endoscope damage intraoperatively or preoperatively. Given the fragile nature of the salivary endoscopes, it is ideal that the scope is opened and tested before the patient is placed under general anesthesia. If a problem is found, the other scope is immediately available. Keeping with the same philosophy, if a scope fails during a procedure, another scope is available immediately. This is an ideal situation but obviously carries more investment.

There are a number of sialendoscopes available on the market through different manufacturers. The majority of surgeons prefer the all-in-one type of scopes (Karl Storz, Germany). There are however



Examination Sheath, AD. 1.1mm/1.3 mm



Operating Sheath, Working Channel 0.65 mm

Operating Sheath, Working Channel 1.15 mm

Fig. 22.1 Multipurpose system sheaths including a diagnostic sheath and a sheath with incorporated working channel

scopes which utilize a single optic fiber which can be utilized with different sheaths (Fig. 22.1). The one advantage to these sheaths is that the sheath can be bent. In certain cases, the small bend that can be made will allow a better head on visualization into the secondary duct so the intervention can be performed under direct vision. The sheath system also allows more flexibility with working channels while utilizing only a single optic fiber. This can be more economical as one does not have to buy three all-in-one scopes but rather one optic fiber with three different working sheaths.

Once the papilla has been identified, access is established. Preceding authors have outlined the different techniques that can be utilized in obtaining access (Fig. 22.2). Whichever technique is employed will be based on the surgeon's preference. Regardless of the technique, reduction of trauma around the papilla is very important. Obtaining access to the Stensen's duct generally speaking is straightforward. The situation can be more frustrating when dealing with the Warthin's papilla. A "no-touch" technique is always best. One should avoid the use of toothed forceps near the papilla. Maceration of the local soft tissues will make it even harder to identify the duct papilla that has already been difficult to find. Although it has been advocated to place a subcutaneous saline or 1% lidocaine injection to provide more stiffness to the papilla to aid in finding the papilla, the author has not found this to be helpful in those cases where the papilla has been difficult to find. Instead, in the author's experience, the hydrostatic pressure of the injection seems to constrict the opening of

Fig. 22.2 Basic dilation set with forceps, tapered ostium dilator, and fine duct dilators

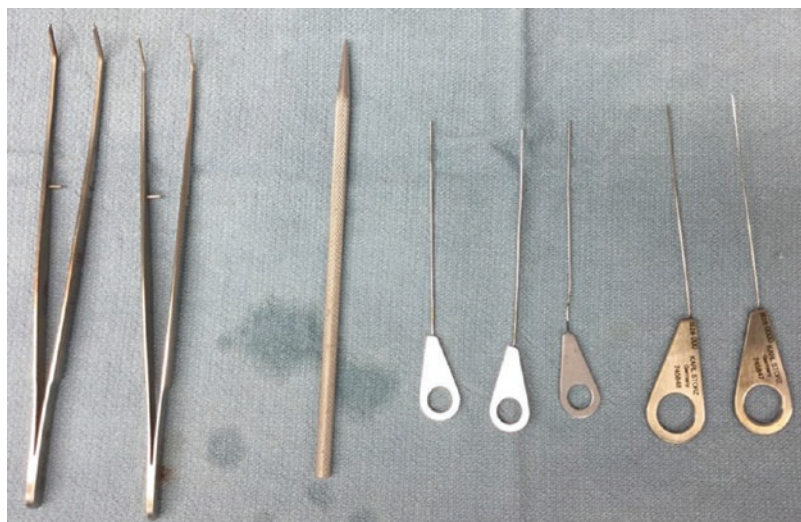
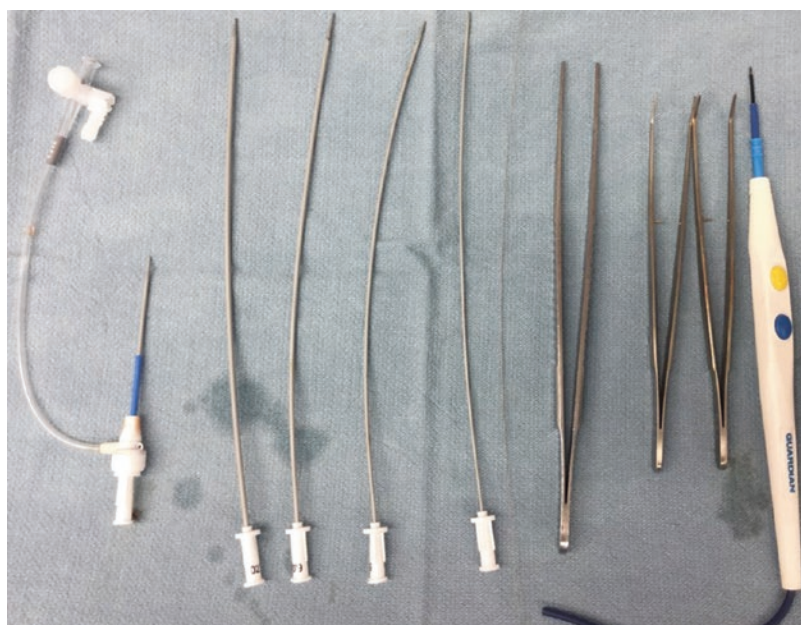
Fig. 22.3 Sialendoscopy tray with malleable, disposable dilators and ductal access sheath system (Cook Medical, Bloomington, IN)



the papilla further leading to a longer and more difficult dilatation procedure.

When the duct is small despite maximal dilatation, the introduction of the scope may still pose a challenge. If visual confirmation of the papilla opening is difficult, methylene blue can be painted onto the mucosa, and milking of the gland can show where the blue dye is washing off [4]. In such instances, a papillotomy may also be required. A needle tip cautery and middle ear scissors can be valuable for performing a papil-

lotomy. The middle ear scissors are the perfectly sized to create a papillotomy especially if one is dilating with the reusable metal dilator sets (Karl Storz, Germany). Chang et al. described a limited distal sialodochotomy as an alternative access technique [5]. The author routinely uses dilatation using the Cook flexible dilator system using Seldinger technique (Fig. 22.3). Chossegras et al. described an access technique relying on metal bougie dilatation over a guidewire technique [6]. The Cook dilator system technique incorporates

use of malleable, soft, hydrophilic-coated dilators to facilitate introduction and reduce trauma to the duct. If the papilla is tight after the first dilatation with the fourFrench Cook dilator, a small linear incision over the dilator using a needle tip cautery set on cut mode is helpful. This will immediately reduce any further resistance to insertion of subsequent dilators. If a papillotomy is created, stenting is advised to control scarring as the mouth has a wonderful preponderance to healing.

During sialendoscopy irrigation is required to visualize the duct. Surgeons have different ways of maintaining irrigation, and two principles are helpful in this regard. First, limit the amount of the irrigant in order to reduce the intraoperative and postoperative swelling of the gland. Luers et al. has shown that irrigation should be intermittent and reduction of pressure within the ductal system to below 400 daPa reduces possible ductal damage [7]. Secondly, you must check the surrounding areas during the course of the procedure to ensure that a ductal tear has not occurred which will lead to extravasation of the fluid into the surrounding soft tissues. This may evenlead to airway compromise from the surrounding soft tissue swelling. In terms of the technique, simple Luer-lock syringes have been used ranging in size from 1 to 20 cc. Smaller syringes require more frequent replacements, thereby impacting the surgeon's assistant's ability to operate the basket and also adding the possible introduction of air bubbles which obscure endoscopic visualization. On the other hand, the larger the syringe used, the greater the exertion pressure that needs to be applied to the plunger. Some surgeons propose using an automatic irrigation system that is designed for endoscopic sinus surgery. This technique transfers control of irrigation to the surgeon from the assistant, the latter being the more conventional approach. If one is using this automated irrigation system, the flow rate should be on the lowest setting to limit the volume of irrigant per case and reduce the risk of ductal damage and extravasation related complications. The Cook syringes used for balloon dilatation allow for low-pressure, low-flow, low-volume irrigation (Fig. 22.4).

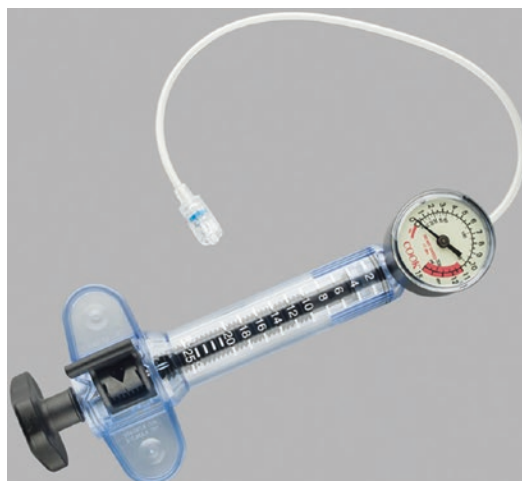


Fig. 22.4 Irrigation pump device

During the procedure, it may be necessary to reinsert the scope several times. In many cases, the reintroduction of the scope may not pose any difficulties. However, cases will be encountered where after several reinsertions the papilla will become edematous and either the scope cannot be reinserted at all or the forceful manipulation of the scope will cause further trauma to the distal duct mucosa leading to a small tear and creation of a false passage. Various surgeons have invented techniques and tools to overcome this problem. Li et al. has reported on the use of an epidural catheter [8]. Some sialendoscopists have incorporate-dangiocatheters to protect the duct from multiple introductions of the endoscope. However due to the small size of the angiocatheters, these have to be withdrawn along with the scope when a stone fragment is being removed. To overcome the loss of access, employment of guide wires is a more guaranteed wayof keeping ductaccess. Having the guidewire either stay within the duct all the time along the side of the scope can be accomplished in cases where the duct is large enough to accommodate both. Alternatively, as soon as the scope is withdrawn, the guide wire can be placed within the duct. The Kolenda Access Sheath is another alternative for constant duct access and maintains accessduring the multiple interventions. Currently, theKolenda Access Sheath is FDAapproved for placement within the submandibular ductal system

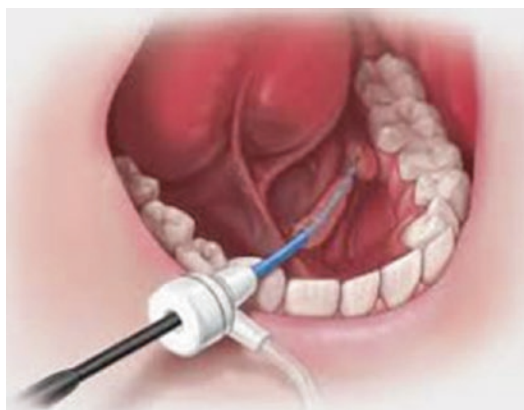

Fig. 22.5 Kolenda Access Sheath placed within the left Wharton's duct (Cook Medical, Bloomington, IN)




Fig. 22.6 The Stonebreaker system provides intracorporeal lithotripsy using a pneumatic, gas-driven piston to break salivary stones (Cook Medical, Bloomington, IN)

(Fig. 22.5). The advantage is that the diameter of the sheath allows several instruments to be placed sidebyside, which can be easily guided to the area of intervention. The opening is large enough to remove larger stone fragments than the angiocatheter without the need to remove the sheath for delivery of smaller stone fragments. Given that the sheath allows constant access, it also facilitates irrigation of finer stone fragment removal with the help of the irrigating catheter (Sialocath™, Cook Medical, USA), combined with suction on the sheath. The smallest multiple fragments can be cleared this way without the deployment of a basket.

Intraductal lithotripsy is most commonly carried out using a holmium laser. The Stonebreaker™ (Cook Medical, USA), which operates through transference of kinetic energy, is a new tool for endoscopic intracorporeal lithotripsy (Fig. 22.6). When intraductal lithotripsy is performed with the Stonebreaker, ductal perforation can arise in

situations where the stone is impacted into the ductal wall. It has been long taught that once a perforation is recognized, the procedure should be terminated. The obvious concern is that continuous irrigation will result in soft tissue edema with possible consequence of airway compromise. If the perforation is large, the procedure should be terminated; however, it is possible to continue lithotripsy with a stonebreaker after a small perforation. The caveat is that minimal amounts of irrigation are used and frequent visual checks of the surrounding soft tissues are made.

With intraductal lithotripsy utilizing the Stonebreaker, retropulsion of stones can be observed especially if a megaduct is present. In these cases, a basket can be used first to trap the stone [9]. This can be left in the duct, and a scope can be reintroduced with the Stonebreaker, which can be deployed on the stone that is being held by the basket. If a Kolenda Sheath is used, the basket can be slipped next to the scope, and the basket handle can be left intact. In cases where the scope provides the only working channel, the basket handle has to be cut off, and a mosquito holds the basket, while the scope is reintroduced with the Stonebreaker. In some cases, several baskets may have to be deployed before the stone is completely fragmented.

Floating stones are the easiest stones to remove solely with a basket [10, 11]. When starting performing sialendoscopy, one may be fooled that a floating stone is present as there appears to be space around the stone circumferentially. One must remember that as the stone enlarges, it causes distal blockage which in time will lead to dilatation of the proximal duct. Distally to the stone, the duct will remain its natural diameter. So the stone will appear to float, but it is floating in the enlarged duct so once the basket is engaged as the stone is being pulled out, it will get hung up on the lip of the distal duct. If sufficient force is applied, the duct can be stripped necessitating conversion to open gland removal. In such circumstance, lithotripsy needs to be performed before basket clearance is attempted to break the stone into pieces small enough to easily traverse the narrowest distal portion.

Post termination of the procedure, some sialendoscopists will place a stent. There is no agreement

when and for how long a stent should be placed [12]. Prospective randomized studies would be useful to answer these questions. In the meantime, surgeon's personal preferences will guide the case selection for stenting. In terms of choices of available stents, previous authors have eluded to these, but these may vary from MacGyver type of stents such as angiocatheters or pediatric feeding tubes to commercially available stents such as the Walvekar Salivary Stent or the Schaitkin Salivary Duct Cannula (Hood Laboratories, Pembroke, MA). The Kolenda Access Sheath can be used as a stent if employed during the case. A linear cut of the sheath forms a T split, which is then sutured to the mucosa using 4.0 nylon. The most important part of healing in post-interventional sialendoscopy cases is having good salivary flow. Stents can hinder flow so if utilized generally short-term use is advocated in most cases. Stents are more often considered in cases where a papillotomy is performed. The risk of scarring may also be mitigated in cases where a new ductal opening is created in the face of scarring from previous surgery involving the native papilla. Some surgeons will use stents for irrigation purposes to deliver intraductal steroid injections in the postoperative period.

The treatment of stenosis is a challenging dilemma. The majority of stenosis occurs in the parotid glands but can be found in submandibular ducts as well [13]. A purely endoscopic treatment approach is the ideal solution but may be achieved in few cases. Diagnostic office sialendoscopy is very important to gauge the size of the stenosis in decision-making for the most appropriate treatment. High-pressure balloons are best choice of treatment but are oftentimes difficult to insert as the ductal opening may be too small (Fig. 22.7). In cases with a tight stenosis, the Storz hand-held drill can be used to enlarge the stenosis followed by stretching with the scope and then introduction of the 1.5 mm Cook high-pressure balloon. In these cases, it is important to repeat the endoscopy and dilation again within a short period of time allowing for a greater success rate of keeping the stenosis open. If the stenosis is close to the papilla, stenting for 1–2 weeks should be considered.




Fig. 22.7 High-pressure salivary duct balloon (Cook Medical, Bloomington, IN)

References

1. Marchal F, Dulguerov P, Lehmann W. Interventional sialendoscopy. *N Engl J Med*. 1999;341:1242–3.
2. Marchal F. Salivary gland endoscopy: new limits? *Rev Stomatol Chir Maxillofac*. 2005;106(4):244–9.
3. Ngu RK, Brown JE, Whaites EJ, Drage NA, Ng SY, Makdissi J. Salivary duct stricture: nature and incidence in benign salivary obstruction. *Dentomaxillofac Radiol*. 2007;36(2):63–7.
4. Luers JC, Vent J, Beutner D. Methylene blue for easy and safe detection of salivary duct papilla in sialendoscopy. *Otolaryngol Head Neck Surg*. 2008;139(3):466–7.
5. Chang JL, Eisele DW. Limited distal sialodochotomy to facilitate sialendoscopy of the submandibular duct. *Laryngoscope*. 2013;123(5):1163–7.
6. Chossegros C, Guyot L, Richard O, Barki G, Marchal F. A technical improvement in sialendoscopy to enter the salivary ducts. *Laryngoscope*. 2006;116:842–4.
7. Luers JC, Ortmann M, Beutner D, Hüttenbrink KB. Intraductal pressure during sialendoscopy. *J Laryngol Otol*. 2014;128:897–901.
8. Li J, Fang W, Chen JF, Long X. Epidural tube: a useful device in sialendoscopy operations. *J Oral Maxillofac Surg*. 2016;74(3):552–5.
9. Geithoff UW. Basic sialendoscopy techniques. *Otolaryngol Clin N Am*. 2009;42:1029–52.
10. Walvekar RR, Carrau RL, Schaitkin B. Endoscopic sialolith removal: orientation and shape as predictors of success. *Am J Otolaryngol*. 2009;30:153–6.
11. Marchal F, Dulguerov P. Sialolithiasis management: the state of the art. *Arch Otolaryngol Head Neck Surg*. 2003;129:951–6.
12. CH S, Lee KS, Tseng TM, Hung SH. Post-sialendoscopy ductoplasty by salivary duct stent placements. *Eur Arch Otorhinolaryngol*. 2016;273:189–95.
13. Koch M, Iro H, Künzel J, Psychogios G, Bozzato A, Zenk J. Diagnosis and gland-preserving minimally invasive therapy for Wharton's duct stenoses. *Laryngoscope*. 2012;122(3):552–8.

M. Boyd Gillespie

Key Points

1. The current evidence clearly supports sialendoscopy as an effective and cost-effective treatment for sialolithiasis.
2. Less evidence is available supporting the use of sialendoscopy for non-stone disorders.
3. There is a pressing need for the validation of an agreed upon salivary-specific quality-of-life (QOL) instrument to capture the outcomes of gland-preserving interventions.
4. Salivary surgeons need to pool data from patients treated with gland preservation in order to answer basic questions that may improve patient outcomes.

State of the Science

During the first two decades of development, salivary gland-preserving therapy focused largely on sialolithiasis since this is the primary cause of salivary gland obstruction. The vast majority of studies were uncontrolled, retrospective case series ranging in size from a few patients to several hundred or more. A recent PubMed search of

the term *sialendoscopy* yielded a total of 250 articles, none of which were randomized, controlled trials (level I evidence). Although uncontrolled and not randomized, the available research clearly showed that salivary endoscopy could achieve the concrete outcome of successful stone removal in 85–90% of cases [1]. These series often report the concrete but less meaningful outcome of gland preservation rate. Although most series reported gland preservation rates of 90–95% in patient with sialolithiasis, this outcome is a false dichotomy since many patients with small or less symptomatic stones would unlikely require gland excision and many patients with parotid stones would refuse gland extirpation out of concerns of facial nerve dysfunction. In addition, most series provided only short-term (weeks to months) follow-up times with limited description of patient status such as improved or failure to improve.

More recently, gland-preserving surgery with sialendoscopy has been increasingly used for non-stone disorders such as scar tissue, radioiodine sialadenitis, Sjögren's syndrome, juvenile recurrent sialadenitis, sialadenosis, and idiopathic chronic sialadenitis. When used for obstructive symptoms such as glandular pain and swelling with meals, salivary endoscopy has shown improvement of symptoms in 70–80% of patients on average; however up to 50% of patients have some degree of ongoing symptoms although less compared to pretreatment [2].

M. Boyd Gillespie, M.D., M.Sc.
Department of Otolaryngology—Head and Neck
Surgery, University of Tennessee Health Science
Center, Memphis, TN, USA
e-mail: mgilles8@uthsc.edu

Less is known about rates of improvement of patients with nonobstructive symptoms such as persistent or paroxysmal glandular swelling and pain not related to meals although it is presumed to be lower than that of patients where an obstructive lesion or scar can be identified.

In order to gain acceptance, new interventions must be acceptable to patients, surgeons, and payers. Patient concerns include relief of symptoms, avoidance of complications, avoiding incisions, outpatients care, rapid recovery, preservation of function and cosmesis, and affordability. Surgeon concerns include success rates of therapies; avoidance of complications; technical feasibility, reproducibility, and teachability; and fair compensation for the time, training, and technology of the treatment. Payer concerns include cost-effectiveness, success rate, recurrence rates, and patient satisfaction. Gland-preserving therapy with sialendoscopy has demonstrated promise in this regard. A recent analysis compared the cost-effectiveness of gland-preserving therapy with sialendoscopy to gland excision for chronic obstructive sialadenitis. The study found that gland-preserving therapy was less expensive, involved shorter operative time and hospital stays compared to gland excision, and was highly successful with 87% of patients in the gland preservation group reporting improvement in symptoms [3].

Integration of Evidence-Based Medicine

The field of evidence-based medicine (EBM) was introduced by Guyatt in 1991 who described it as a “method of clinical practice in which the practitioner seeks to understand the evidence on which one’s practice is based, the soundness of that evidence, and the strength of inference that the evidence permits” [4].

There are five steps in the process of evidence-based medicine:

1. *Ask a clinical question based on a patient encounter.* For example, does removal of a salivary stone >1 cm require sialendoscopy?
2. *Search for the best evidence on the topic available in the medical literature.* This step

requires access to medical databases and search engines, as well as skills in effective search techniques.

3. *Perform an evaluation of the quality of the evidence.* This requires knowledge with regard to the effects of sample size (reduction of random error) and quality study design which safeguards against bias.
4. *Combine the evidence with personal clinical experience and patient preferences to come up with the best treatment option for a given patient.* This step requires a cost/risk vs. benefit analysis of the treatment options.
5. *The final step is to critically evaluate the outcomes of an intervention over time.* This requires valid outcome measurement tools as well as long-term data. This also implies that interventions that are ineffective or result in harm should be avoided.

Currently, there are many pertinent questions that need to be answered with regard to salivary gland-preserving therapy. A sample of these questions include the following:

1. Is the use of sialendoscopy superior to standard non-endoscopic techniques in the management of large (>1 cm), palpable salivary stones?
2. Do patients with glandular pain and swelling not associated with meals benefit from sialendoscopy?
3. Does sialendoscopy reduce the discomfort and swelling associated with sialadenitis?
4. Does sialendoscopy reduce the frequency and severity of flares related to recurrent juvenile parotitis compared to oral antibiotics and steroids?
5. Does sialendoscopy reduce xerostomia and improve quality of life in patients with Sjögren’s syndrome?

A search of the current evidence reveals a general lack of randomized, controlled studies; therefore it is difficult to ascertain, especially with regard to non-stone disease, whether the intervention is superior to placebo. Therefore, research in this field needs to progress to higher levels of evidence beyond retrospective case

series in order to improve the care of patients with salivary disorders. The current low-level evidence (level III and IV) suggests but does not confirm that sialendoscopy may be helpful in a variety of non-stone disorders. Given the relative low-risk and minimally invasive nature of sialendoscopy, many patients and surgeons skip to step 4 in the EBM hierarchy rather than repeat conservative measures that have failed (e.g., heat, massage, hydration, sialogogues) or progress to more invasive procedures with greater risk (e.g., parotidectomy). Also lacking is adequate follow-up data required by step 5 of EBM. Few studies report patient outcomes that are greater than a few months, and most fail to use validated outcome instruments. Commonly reported outcomes such as patient improvement or resolution of symptoms suffer from a lack of precision and reproducibility.

Currently Available Outcome Measures

Outcome research is clinical research that focuses on measurement of the results (outcomes) of medical interventions. Commonly used outcome measures in surgery vary from binary outcomes such as mortality or complication rate to non-binary outcomes such as disease-specific symptoms, quality of life (QOL), and satisfaction with care which are more difficult to measure and vary along a continuum. Validated instruments (staging scales; questionnaires) are generally required to capture non-binary outcomes with precision. Quality-of-life (QOL) measures are particularly valuable for chronic, nonlife-threatening disorders with symptoms that fluctuate over time. Examples of previously validated disease-specific and QOL measure in otolaryngology include the University of Michigan Xerostomia Scale, the M.D. Anderson Dysphagia Inventory, the Voice Handicap Index, and the University of Washington Head and Neck Quality of Life Index.

Currently, there is no agreed upon validated instrument for capturing salivary-related quality of life. One approach is the use of visual analog scales (VAS). One study assessed QOL

in 19 patients who underwent combined endoscopic and open transfacial surgery for chronic sialadenitis of the parotid gland after a mean follow-up time of 41 months [5]. Using a 100-point visual analog scale (VAS) with 0 indicating no symptoms and 100 maximal symptoms, patient salivary symptom severity was reduced from a mean of 77 (range, 55–100) preoperatively to only 2.4 (range, 0–15) following the combined approach. When asked to rate their overall QOL, with 0 indicating no QOL and 100 maximal QOL, patient QOL demonstrated a significant improvement increasing from 35 (range, 5–65) to 92 (range, 75–100). A benefit of VAS is that they are fast, easy to use, and easy to interpret; however they lack precision and detail that may guide future treatment decisions.

Another approach is to use established general QOL scales that are not specific for salivary disorders such as the Short-Form-36 (SF-36) or Glasgow Benefit Inventory (GBI). A study of 46 patients with chronic and recurrent salivary swelling found that 85% of patients reported symptom improvement at a mean of 7 months following salivary endoscopy but continued to have lower scores on role-physical functioning and bodily pain on the SF-36 compared to age-matched controls. Although general QOL instruments like the SF-36 allow comparison between disease states, it is impossible to determine from this survey whether the ongoing decrease QOL was due to the salivary disorder or an unidentified confounding factor [6]. A separate study employed the Glasgow Benefit Inventory (GBI), a validated scale used to assess a patient's perceived benefit from a medical intervention, to measure 54 patients' perceptions of short-term improvement after salivary endoscopy for salivary stones and ductal scar [7]. The study found a mean improvement in the GBI that was comparable to other otolaryngology procedures; however the GBI is unable to assess ongoing salivary-specific impairment.

The first disease-specific system to be introduced was the Lithiasis, Stenosis, and Dilation (LSD) Classification system (Table 23.1) [8]. Although the LSD system can be used to accurately describe ductal pathology as visualized by

Table 23.1 The Lithiasis, Stenosis, and Dilation (LSD) Classification system

L (Lithiasis)	S (Stenosis)	D (Dilation)
L0 no stones	S0 no stenoses	D0 no dilation
L1 floating stones	S1 intraductal diaphragmatic stenosis (single or multiple)	D1 single dilation
L2a fixed stone, visible, <8 mm	S2 single ductal stenosis (main duct)	D2 multiple dilation
L2b fixed stone, visible, >8 mm	S3 multiple or diffuse ductal stenoses (main duct)	D3 generalized dilation
L3a fixed stone, partly visible, palpable	S4 generalized ductal stenosis	
L3b fixed stone, partly visible, nonpalpable		

sialendoscopy, the scale, which is filled out by the surgeon, has never been correlated with patient symptoms or prognosis. Another study applied a modified version of the previously validated Oral Health Impact Profile-14 (OHIP-14) which was changed so that each question would specifically address the impact of the salivary glands on QOL (Table 23.2) [2]. The results of this study demonstrate that a lower score on the modified salivary-specific OHIP-14 instrument, indicative of good quality of life, is significantly associated with a higher incidence of complete symptom resolution and symptom improvement. Patients with stones reported significantly higher rates (66%) of complete symptom resolution when compared to patients with non-stone etiologies (41%), and likewise had significantly lower median scores on the modified OHIP-14 than patients without stone pathology. The study only used the modified OHIP-14 after treatment; therefore the reliability and sensitivity of the questionnaire over time could not be established.

Efforts to construct a better salivary QOL instrument continue. A promising recent effort was the publication of the chronic obstructive sialadenitis symptoms (COSS) questionnaire [9]. The COSS is a self-administered 20-question survey based on sialadenitis symptoms including salivary gland pain, tenderness, and swelling during and in between meals. In addition, the

Table 23.2 Modified Oral Health Impact Profile-14

Modified OHIP-14 for issues pertaining to salivary gland problems
<i>Available responses to questions include “never” = 0, “hardly ever” = 1, “occasionally” = 2, “fairly often” = 3, or “very often” = 4</i>
1. Have you had trouble pronouncing any words because of your salivary problems?
2. Have you felt that your sense of taste has worsened because of your salivary problems?
3. Have you had pain in your salivary glands since treatment?
4. Have you found it uncomfortable to eat any foods because of your salivary problems?
5. Have you been self-conscious because of your salivary problems?
6. Have you felt tense because of your salivary problems?
7. Has your diet been unsatisfactory because of your salivary problems?
8. Have you had to interrupt meals because of your salivary problems?
9. Have you found it difficult to relax because of your salivary problems?
10. Have you been a bit embarrassed because of your salivary problems?
11. Have you been a bit irritable with other people because of your salivary problems?
12. Have you had difficulty doing your usual jobs because of your salivary problems?
13. Have you felt that life in general was less satisfying because of your salivary problems?
14. Have you been totally unable to function because of your salivary problems?

Adapted from Slade, GD. Derivation and validation of a short-form oral health impact profile. *Community Dent Oral Epidemiol.* 1997 Aug;25(4):284–90
A salivary-specific, modified OHIP-14 was used to assess patient quality-of-life measures after sialendoscopy for chronic sialadenitis. Scores were assigned as follows for patient responses: “never” = 0; “hardly ever” = 1; “occasionally” = 2; “fairly often” = 3; “very often” = 4. Higher scores suggest worse salivary gland-related quality of life, while lower scores are indicative of relatively little impairment. Summated scores were recorded for each patient and used in subsequent analyses as a marker of salivary-related quality of life

instrument captures other disorder-specific symptoms such as noticeability by others, level of embarrassment, quality and quantity of saliva, and the effect on swallowing, speech, sleep, and daily activities (Table 23.3). In the initial study, 40 patients with chronic obstructive sialadenitis completed the survey prior and 3 months after

Table 23.3 The chronic obstructive sialadenitis symptoms (COSS) scale

UCSF Chronic Obstructive Sialadenitis Symptoms (COSS) Questionnaire

Today's Date _____ Your Name _____

The following questions ask about symptoms related to each of your symptomatic salivary glands.

Which salivary gland(s) bother you? (Please circle all affected glands)

- | | |
|---------------------------------------|---|
| 1. RIGHT Parotid gland (on the cheek) | 3. RIGHT Submandibular gland (under the chin/jaw) |
| 2. LEFT Parotid gland (on the cheek) | 4. LEFT Submandibular gland (under the chin/jaw) |

Please answer each question below. To answer a question, draw a **CIRCLE** around **ONE** of the numbers listed for that question, like this: (50%) or (5).

THIS PAGE SHOULD BE COMPLETED FOR EACH BOTHERSOME SALIVARY GLAND
Affected Gland: _____

1. Over the **PAST MONTH**, what percentage of the **TIME** do you experience **DISCOMFORT** in the area of your affected salivary gland when you are **NOT** touching or pressing on the area?

Never ➤ 0% 10% 20% 30% 40% 50% 60% 70% 80% 90% 100% ◀ Constantly

2. How **SEVERE** is this discomfort when you are **NOT** touching or pressing on the area?

No discomfort ➤ 0 1 2 3 4 5 6 7 8 9 10 ◀ Very Severe

3. Over the **PAST MONTH**, what percentage of the **TIME** do you experience **DISCOMFORT** in the area of your affected salivary gland when you **ARE** touching or pressing on the area?

Never ➤ 0% 10% 20% 30% 40% 50% 60% 70% 80% 90% 100% ◀ Constantly

4. How **SEVERE** is this discomfort when you **ARE** touching or pressing on the area?

No discomfort ➤ 0 1 2 3 4 5 6 7 8 9 10 ◀ Very Severe

5. Over the **PAST MONTH**, what percentage of **MEALS** do you experience **SWELLING** in the area of your affected salivary gland **WHILE EATING**?

Never ➤ 0% 10% 20% 30% 40% 50% 60% 70% 80% 90% 100% ◀ Every meal

6. How **SEVERE** is this swelling during meals?

No swelling ➤ 0 1 2 3 4 5 6 7 8 9 10 ◀ Very Severe

7. Over the past month, what percentage of the **TIME** do you experience **SWELLING** in the area of your affected salivary gland **BETWEEN MEALS** (when you are not eating)?

Never ➤ 0% 10% 20% 30% 40% 50% 60% 70% 80% 90% 100% ◀ Always

8. How **SEVERE** is this swelling when you are not eating?

No swelling ➤ 0 1 2 3 4 5 6 7 8 9 10 ◀ Very Severe

9. Is the swelling of your affected salivary gland **NOTICEABLE BY OTHERS**?

Not at all ➤ 0 1 2 3 4 5 6 7 8 9 10 ◀ Always

10. Are you **EMBARRASSED** to be seen in public when your salivary symptoms are active?

Not at all ➤ 0 1 2 3 4 5 6 7 8 9 10 ◀ Always

Over the **PAST MONTH**, what percentage of the time have you experienced:

	Never ▼																	Constantly ▼
11. Too LITTLE saliva (dry mouth)?	0%	10	20	30	40	50	60	70	80	90	100%							
12. Too MUCH saliva?	0%	10	20	30	40	50	60	70	80	90	100%							
13. A FOUL TASTE in your mouth?	0%	10	20	30	40	50	60	70	80	90	100%							

Table 23.3 (continued)

Over the PAST MONTH, how much do your salivary gland symptoms impact your ability to:											
	Not at all										Very severely
	▼										▼
14. Swallow?	0	1	2	3	4	5	6	7	8	9	10
15. Speak?	0	1	2	3	4	5	6	7	8	9	10
16. Chew?	0	1	2	3	4	5	6	7	8	9	10

Over the PAST MONTH, how much do your salivary gland symptoms interfere with your:											
	Not at all										Very severely
	▼										▼
17. Diet?	0	1	2	3	4	5	6	7	8	9	10
18. Sleep?	0	1	2	3	4	5	6	7	8	9	10
19. Daily activities?	0	1	2	3	4	5	6	7	8	9	10
20. Overall quality of life?	0	1	2	3	4	5	6	7	8	9	10

interventional sialendoscopy. The patients demonstrated significant improvement in COSS score posttreatment, while a simultaneously captured short-form 8 (SF-8) general QOL form did not change. COSS scores showed greater improvement in submandibular glands compared to parotid and stones compared to non-stone disorders.

Building Better Outcome Measures

Although COSS and OHIP-14 are promising tools for capturing the disorder-specific changes in salivary symptoms with treatment, neither survey has been completely validated. There are several components that a particular questionnaire must meet to be considered valid. The questionnaire would need evidence of the following:

- 1. Face validity—do the questions (items) seem to measure what they are supposed to measure? (e.g., does it measure salivary symptoms instead of myofascial pain?)
- 2. Content validity—do the questions (items) provide a representative sample of the disorder? (e.g., does it adequately represent the multiple etiologies of salivary disorders such as stone, scar, radioiodine, Sjögren’s, or inflammatory conditions?)

- 3. Criterion validity—does the questionnaire correlate with another measure of the trait of disorder? (e.g., does an improvement in glandular symptoms on the questionnaire correlate with improvement as seen on imaging/scintigraphy?)
- 4. Construct validity—does the questionnaire correlate with other questionnaires designed to capture similar outcomes? (How is the COSS questionnaire similar and different from the OHIP-14?)
- 5. Reliability—does the questionnaire result remain stable if there is no change in salivary-related health status? (This could be accomplished with proper treatment and control groups.)
- 6. Responsiveness—does the questionnaire result change if there is a change in salivary-related health status? (This could be done by assessing scores before and after gland excision.)

Validation of a generally agreed upon salivary QOL instrument is the next step needed for the progression of the field of salivary gland preservation therapy. Such an instrument would allow comparison between different techniques and treatments both medical and surgical. This would allow adoption of more effective therapies while avoiding ineffectual interventions. This would reduce ongoing debate on many

topics including the benefit of stenting, intraglandular steroids, and botox among other interventions.

What To Do Now

There are several steps that an invested community of salivary surgeons can do now to progress the field of gland-preserving therapy:

1. Form a national/international research group to share data.
2. Create an international database that captures patient-specific factors, disorder-specific factors, surgery-specific factors, and outcomes using a validated QOL salivary-specific QOL instrument.
3. Get enough participating surgeons to obtain a large enough sample size to answer basic treatment-related questions.

The above approach could provide an ongoing forum to address new treatment approaches as they emerge in a rational and systematic fashion. Getting there will require leadership along with time, talent, and some degree of financial support.

References

1. Strychowsky JE, Sommer DD, Gupta MK, et al. Sialendoscopy for the management of obstructive salivary gland disease: a systematic review and meta-analysis. *Arch Otolaryngol Head Neck Surg.* 2012;138:541–7.
2. Gillespie MB, O'Connell BP, Rawl JW, et al. Clinical and quality-of-life outcomes following gland-preserving surgery for chronic sialadenitis. *Laryngoscope.* 2015;125:1340–4.
3. Ong AA, Carroll WW, Nguyen SA, Gillespie MB. Cost-effectiveness of transfacial gland-preserving removal of parotid sialoliths. *Laryngoscope.* 2016;127(5):1080–6.
4. Guyatt GH. Evidence-based medicine. *ACP J Club.* 1991;114:A-16.
5. Koch M, Iro H, Zenk J. Combined endoscopic-transcutaneous surgery in parotid gland sialolithiasis and other ductal diseases: reporting medium-to long-term objective and patients' subjective outcomes. *Eur Arch Otorhinolaryngol.* 2013;270:1933–40.
6. Kroll T, Finkensieper M, Sharma SJ, et al. Short-term outcome and patient satisfaction after sialendoscopy. *Eur Arch Otorhinolaryngol.* 2013;270:2939–45.
7. Ianovski I, Morton RP, Ahmad Z. Patient-perceived outcome after sialendoscopy using the Glasgow Benefit Inventory. *Laryngoscope.* 2014;124:869–74.
8. Marchal F, Chossegros C, Faure F, et al. Salivary stones and stenosis: a comprehensive classification. *Rev Stomatol Chir Maxillofac.* 2009;110:1–4.
9. Aubin-Pouliot A, Delagnes EA, Chang JL, Ryan WR. Sialendoscopy-assisted surgery and the chronic obstructive sialadenitis symptoms questionnaire: a prospective study. *Laryngoscope.* 2016;126:1343–8.

Index

A

Ablative techniques, 206
Acellular dermal matrix (ADM), 197
Acinar cells, 33
Actinomycosis, 111
Active sialadenitis, 60
Acute sialadenitis, 4, 6, 22, 23, 33, 58, 60, 109, 110, 112, 116, 230, 231
 treatment algorithm, 117
Adenoid cystic carcinoma, 36
Alcoholic cirrhosis, 139
Alcoholism, 139
American College of Rheumatology (ACR), 24, 120
Amylase, 175
Anesthesia, 61, 237
Angiotensin-converting enzyme (ACE), 123
Angle of mandible, 128
Anticholinergic drugs, 187
Anticholinergic symptoms, 198
Antidiuretic hormone (ADH), 138
Antiperspirants, 198
Antiretroviral therapy (ART), 161
Arteriovenous (AV) malformations, 167
Arthroscopy, 209
Atropine, 188
Atypical odontalgia, 210
Auriculotemporal nerve, 195
Auriculotemporal syndrome, 195
Autoimmune sialadenitis, 34
Avulsion, 97
Axial T1 non-contrast MRI image, 165
Axial T2 contrast MRI image, 165

B

Baclofen, 206
Bacterial sialadenitis, 22, 69, 128
Basal cell neoplasm, 33
Basaloid neoplasm, 36
B-cell lymphoma, 123
Benign cytologic diagnosis, 36
Benign lymphoepithelial cysts (BLEC), 8
 in ART, 161
 in HIV patients, 160

Benign salivary masses, 7
Benign salivary neoplasms, 35
Bilateral parotid duct relocation (B-PDR), 189
Bilateral parotid enlargement, etiology, 139
Bilateral parotid swelling, 6
Bilateral submandibular duct relocation, 189
Biomarkers, 123
Blunt dissection, 238
Botulinum toxin (BoNT), 83, 188
Botulinum toxin A, 198
Breakup test, 5
Bulimia, 139

C

Carotidynia, 211
Chronic obstructive sialadenitis symptoms (COSS), 254, 255
Chronic sialadenitis, 24, 25, 33, 39, 59, 88, 111–113, 116, 131
 causes, 111
 parotid ultrasound, 113
 treatment algorithm, 117
Classical trigeminal neuralgia, 205
Clinical history, salivary gland diseases
 dry mouth patient, 5
 otolaryngologic review, 9
 parotid specific history, 8
 salivary issues, 3–5
 submandibular/sublingual-specific history, 7–8
Clostridium botulinum, 188
Computed tomography (CT), 17, 18, 59, 71, 113, 160
 acute parotid sialadenitis, 22
 FNA, 27, 30
 parotid stones, 52
 pleomorphic adenoma, 20
 submandibular gland and duct, 23
 submandibular stone, 114
Conservative management, 75
Conventional sialography, 53
Conventional X-ray imaging, 15
Cook flexible dilator system, 247
Cook syringes, 248
Corticosteroid therapy, 122

Cracked tooth syndrome, 209
 Cranial neuralgias, 203
 Crepitus, 209
 CT. *See* Computed tomography (CT)

D

Dental pain
 atypical odontalgia, 210
 cracked tooth syndrome, 209
 dental trauma causes, 209
 odontogenic infections, 209
 palpation, 210
 Dental trauma, 209
 Dermoid cysts, 161
 Diagnostic sialendoscopy, 43, 73
 ductal scar, 74
 office-based, 73
 Diff-Quik, 28
 Diffuse infiltrative lymphocytosis syndrome (DILS), 177
 Dilation set, forceps, 247
 Direct endoscopic visualization, 132
 Distal styloid process, 211
 Drooling. *See* Sialorrhea
 Drooling frequency and severity scale (DFSS), 187
 Drooling quotient (DQ), 186
 Dry mouth, 10
 Duct perforations, 96
 Duct stenosis, 44, 45
 Ductal corticosteroid infusion (DCI), 133
 Ductal dilation, 233
 Dysfunctional aquaporin channels, 138

E

Eagle's syndrome
 palpation, tonsillar fossa, 211
 symptoms, 210
 unilateral throat pain, 211
Echinococcus granulosus, 161
 Endoscopic equipment
 intraductal lithotripsy, 249
 Seldinger technique, 247
 sialendoscopy irrigation, 248
 sialendoscopyis, 245
 Endoscopic intracorporeallithotripsy, 249
 Endoscopic pneumatic lithotripsy, 68
 Enucleation, 148
 Enzyme linked immunoabsorbant assays (ELISA), 162
 Epstein-Barr virus (EBV), 131
 Erlangen Salivary Scope system, 74
 Evidence-based medicine (EBM), 252
 Extracapsular dissection (ECD), 147
 ECD-FND vs. SP/PSP, 153
 surgical technique, 149
 Extracapsular dissection with facial nerve dissection (ECD-FND), 147, 152

Extracorporeal shock-wave lithotripsy (ESWL), 116
 Extrinsic trauma, 104

F

Facial nerve
 branch, 150
 dissection procedures, 151
 monitoring, 150
 Facial pain syndrome, 208, 209, 211, 212
 cranial neuralgias, 203
 dental pain, 209–210
 Eagle's syndrome, 210–211
 FBS
 diagnosis, 212
 parapharyngeal space surgery, 211
 symptoms, 212
 glossopharyngeal neuralgia, 207
 neoplasm, 213–217
 nervus intermedius neuralgia, 207–208
 occipital neuralgia, 208
 PIFP, 210
 symptomatology comparison, sialadenitis vs., 203, 204
 symptoms, salivary and non-salivary pathologies, 203
 TMDs
 articular disc derangement, 208
 evaluation, 209
 NSAID, 209
 symptoms, 208
 TMJ, 208
 trigeminal neuralgia, 203–207
 Fibrosis, 32, 34
 Fine needle aspiration (FNA), 16, 27, 161, 230
 anxiety and discomfort, 31
 CT-guided, 30
 diagnostic accuracy, 32
 equipment, 27, 28
 fibrosis and biopsy site changes, 32
 vs. frozen section, 30, 31
 immediate microscopic assessment, 28
 inadequate sampling, 31
 infection, 31
 local hemorrhage/hematoma, 31
 needle tract contamination by malignant cells, 31
 non-neoplastic salivary lesions, 160
 patient perspective, 30
 procedural steps, 28
 specimen triage, 28
 surgeon-performed, 29
 vs. surgical biopsy, 30
 syncope, 31
 USGFNA, 29
 US-guided, 20
 Fine needle aspiration cytology (FNAC), 149
 First bite syndrome (FBS)
 diagnosis, 212

- parapharyngeal space surgery, 212
 - parotid gland sympathetic denervation, 213
 - salivary myoepithelial cells, 213
 - symptoms, 212
 - First branchial cleft anomalies
 - congenital lesions, 163
 - management, 164
 - sclerotherapy, 164
 - Flow cytometric analysis, 35
 - Fluid-filled cystic structure, 164
 - Fluorescence in situ hybridization (FISH), 29
 - FNA. *See* Fine needle aspiration (FNA)
 - Four-duct ligation, 190
 - French Cook dilator, 248
 - Frey syndrome
 - anatomy and mechanism, 194–195
 - etiology, 195
 - gustatory sweating, 193
 - history, 193–194
 - medical treatment, 198
 - Minor's starch-iodine test, 196
 - prevalence, 193–194
 - surgical prevention and treatment, 196–198
 - testing, 196
 - Frey's syndrome, 151
- G**
- Gamma knife radiation, 207
 - Gasserian ganglion, 206
 - Gland parenchyma, 228
 - Gland-preserving salivary gland surgery, 39, 253, 254, 256
 - benign neoplasm, 150, 151, 153–156
 - ECD surgical technique, 149–150
 - ECD-FND, 152–153
 - Frey's syndrome, 152
 - frozen section, 150
 - historical perspective, 148–149
 - imaging, 150
 - PA clinical and histological characteristics, 149
 - cost effectiveness, 251
 - outcome measurement
 - COSS, 254
 - disease-specific system, 253
 - GBI, 253
 - validation, salivary QOL instrument, 256
 - VAS, 253
 - pleomorphic adenoma, ECD
 - enucleation, 150
 - high-volume parotid centers, 151
 - state of science, 251–252
 - TORS
 - prestyloid parapharyngeal space tumours, 153–155
 - submandibular gland diseases, 155–156
 - treatment approaches, surgeons, 257
 - Glandular parenchyma, 140
 - Glandular swelling, 58, 138
 - Glasgow benefit inventory (GBI), 253
 - Glossopharyngeal neuralgia, 207
 - Glycopyrrolate, 188
 - Graves' disease, 87
 - Great auricular nerve, 150, 152
- H**
- Haemophilus influenzae*, 110
 - Head and neck cancer (HNC), 176–177
 - Heerfordt's syndrome, 35, 111, 123
 - Hematoma, 31
 - Hemorrhage, 31
 - Herpes zoster, 205
 - High-pressure salivary duct balloon, 250
 - Ho:YAG laser lithotripsy, 68
 - Holmium laser lithotripsy, 64, 68, 249
 - Horner's syndrome, 213
 - Human immunodeficiency virus (HIV), 34, 131, 177
 - Hydatid cysts, 161
 - ELISA, 162
 - management, 162
 - Hypersalivation, 185
- I**
- Idiopathic chronic sialadenitis, 251
 - IgA deficiency, 130
 - IgG4-related disease, 121, 123, 124
 - diagnosis, 122
 - medical management, 122
 - pathophysiology, 121
 - IgG4-related sialadenitis, 34
 - ¹³¹I-labeled sodium iodide (Na¹³¹I), 88
 - Immunoglobulin G4-related salivary disease (IgG4-RD), 170
 - Immunohistochemistry, 29
 - Inadequate sampling, 31
 - Incisional/excisional biopsy, 124
 - Inflammatory disorders, 240
 - Inflammatory salivary conditions, 119, 120
 - Intermediate-sized stones, 61, 64
 - Interventional sialendoscopy, 89, 90
 - sialolithiasis, 239
 - submandibular gland, 235
 - Intraductal lithotripsy, 64, 249
 - Intraductal mobile stones, 64
 - Intraparotid lymphadenopathy, 34
 - Irrigation pump device, 248
 - Interventional sialendoscopy, 240
- J**
- Juvenile recurrent parotitis (JRP), 39, 46, 111, 127, 227, 228
 - autoimmune disease, 129–130
 - inflammation, of parotid gland, 129
 - Juvenile recurrent sialadenitis, 251

K

Koch classification, of stenoses, 44, 45
 Kolenda Access Sheath, 248, 249

L

Labial minor salivary gland biopsy, 123, 124
 Lamotrigine, 206
 Large deep-lobe tumors, 21
 Laser lithotripsy, 64, 95, 235
 Lithiasis, stenosis, and dilation (LSD) classification system, 253, 254
 Lithotripsy, 53, 67, 240
 Local anesthesia, 43
 Local intravascular coagulation (LIC), 166
 Localized erythema, 210
 Localized trauma, 195
 Low-grade tumors, 21
 Ludwig's angina, 12
 Lymphatic malformations (LMs), 165
 Lymphoepithelial cysts, 22, 34, 160

M

Magnetic resonance imaging (MRI), 18, 21, 72, 114, 115, 160
 non-neoplastic salivary gland lesions, 160
 T1-weighted, 21, 114, 122
 T2-weighted, 23, 114
 Malignant salivary neoplasms, 36
 Malnutrition disorders, 139
 Mammary analogue secretory carcinoma, 36
 Mandibular tori, 46, 47
 Marchal classification system, salivary duct stones, 44
 Marchal Salivary Scope system, 74–75
 Medication-induced xerostomia, 176
 Megaducts, 81
 Meningioma, 205
 Metastatic squamous cell carcinoma, 36
 Microvascular decompression (MVD), 206
 Mild gland swelling, 99
 Minor salivary gland biopsy, 121, 178
 Minor salivary gland mucocele, 8
 Minor's starch-iodine test, 196
 Mixed malformations, 168
 Mobile salivary stone, 133
 Mouth duct marsupialization, 63
 MRI. *See* Magnetic resonance (MRI)
 MRI sialography, 60
 parotid stones, 53
 MS-related pontine plaques, 205
 Mucocèles
 management, 163
 minor salivary glands, 162
 sclerotherapy, 163
 submandibular gland, 162
 surgical treatments, 163
 Mucoepidermoid carcinomas, 36
 Mucus plugs, 130, 132

Multigland pathology. *See* Single gland pathology
 Multipurpose system sheaths, 246
 Mumps, 128
 Mycobacterial infection, 128
Mycobacterium spp., 128
 M. tuberculosis, 129
 Myoepithelial cells, 138

N

Necrotizing sialometaplasia, 169
 Neoplasm, 148, 213
 Nervus intermedius neuralgia, 208
 Neurectomy, 190–191
 Neuromonitoring, 150
 Neuropathy, sympathetic nervous system, 138
 Neurosarcoidosis, 123
 Neurovascular compression, 207
 Non-contrast sagittal CT scan, 211, 212
 Non-endoscopic techniques, 252
 Non-Hodgkin's lymphoma, 24
 Nonneoplastic salivary masses, 160, 161
 BLEC
 in ART, 161
 in HIV patients, 160
 dermoid cysts, 161
 differential diagnosis, office-based ultrasonography, 160
 hydatid cysts, 161–162
 masseter hypertrophy, 168
 mimic tumors, 159
 Nonsteroidal anti-inflammatory (NSAID) medications, 39, 45, 46, 209, 213
 Non-stone disorders, 251
 Nontuberculous mycobacteria (NTM), 129
 No-touch technique, 62

O

Obstructive sialadenitis, 39, 71
 salivary duct scar, 69
 Occipital neuralgia, 208
 Odontalgia, 209
 Office-based diagnostic sialendoscopy, 39–41, 73
 contraindications, 46
 diagnostic staging, 44
 ductal stenosis, 44
 Juvenile recurrent parotitis, 46
 local anesthesia, 43
 papilla, 42, 43
 patient tolerance, 40
 RAI sialadenitis, 45
 sialadenitis, 43
 Sjogren's syndrome, 45
 tools and setup, 40
 Office-based ultrasonography, 160
 Oral Health Impact Profile-14 (OHIP-14), 254
 Oral motor therapy, 187
 Oxcarbazepine, 206

P

- PA. *See* Pleomorphic adenoma (PA)
- Painful trigeminal neuropathy, 205
- Papillary cystadenoma lymphomatosum. *See* Warthin tumors
- Papillotomy, 238, 239
- Paramyxovirus, 128
- Paramyxovirus infection, 39
- Parapharyngeal space surgery, 213
- Parapharyngeal tumors, 155
- Parasympathomimetic drugs, 186
- Parathyroidectomy, 224
- Parkinson's disease, 186
- Parotid duct, 51, 95–97, 101
 - Mohs resection-lumen, 98
 - sialendoscopic appearance, 89
- Parotid duct ligation, 190
- Parotid ductal system, 228
- Parotid fascia, 128
- Parotid gland, 33, 34
 - postganglionic fibers, 138
- Parotid PA, 149
- Parotid sialoceles, 101
- Parotid specimen, sialadenosis, 141
- Parotid stones, 53, 225, 226
 - clinical presentation, 51
 - conventional sialography, 53
 - CT, 52
 - epidemiology, 51
 - gland excision, 56
 - MRI sialography, 53
 - nonsurgical therapy, 53
 - salivary endoscopy, 54, 55
 - sialolithotomy, 53
 - surgical therapy, 53
 - testing, 52
 - US, 52
- Parotid/submandibular ducts, 18
- Parotid/submandibular papilla, 42, 43
- Parotidectomy, 35, 55, 56, 150, 156
- Partial superficial parotidectomy (PSP), 148
- Patient evaluation, 3–5
 - clinical history
 - dry mouth patient, 5
 - salivary issues, 3–5
 - laboratory studies, 13
 - OLD CARTS, 3, 4
 - parotid specific history, 8
 - parotid-specific examination, 12–13
 - physical examination, 9
 - salivary pathology, 9–10
 - submandibular gland examination, 9–11
 - submandibular/sublingual-specific history, 7–8
- Pediatric salivary disorders, 128–130
 - clinical presentation and diagnosis, 130–131
 - etiologies
 - bacterial sialadenitis, 128
 - JRP, 129–130
 - viral sialadenitis, 128
 - etiologies, 128–129
 - JRP, 127
 - mumps, 128
 - pediatric sialadenitis, 127
 - prodromal symptoms, 128
 - salivary stones, 127
 - sialolithiasis, 130
 - tumours, salivary glands, 127
- Pediatric sialadenitis, 127
- Pediatric sialendoscopy, 133
- Permanent facial nerve dysfunction, ECD, 151
- Persistent idiopathic facial pain (PIFP), 210
- Phlebitis, 34
- Phleboliths
 - vs. sialoliths, 167
 - thrombus formation, 167
- Plain film panoramic radiography, 209
- Pleomorphic adenoma (PA), 20, 35, 147, 148
- Pneumoparotid, 170
- Poiseuille's law, 70
- Posterior fossa craniotomy, 206
- Postganglionic sympathetic fibers, 195, 213
- Postganglionic sympathetic nerves, 138
- Postoperative chemoradiation therapy, 223
- Potential devastation, recurrent disease, 151
- Preoperative imaging, 235
- Prestyloid parapharyngeal space tumours
 - anteromedial, to carotid artery, 154
 - transcervical approach, 153
 - transoral approach to, 154
- Ptyalism, 185
- Pull-through sialodochoplasty, 80
- Punctum identification, 238

Q

Quality of life (QOL), 253

R

- Radiation sialadenitis, 90
- Radiation therapy (RT), 4, 176
- Radioactive iodine (RAI), 4, 177
- Radioiodine (^{131}I), 87, 88
- Radioiodine sialadenitis, 45, 71, 89
 - management, 89
 - prevention, 88
 - sialendoscopy outcomes, 89
- Radiologic imaging, 140
- Ramsay Hunt syndrome, 208
- Ranula
 - CT view, patient, 163
 - management, 163
 - oral, 162
 - pathophysiology, 7
 - sclerotherapy, 163
 - soft masses, 162
 - surgical treatments, 163
 - ultrasonography image, 162

- Recombinant human thyroid-stimulating hormone (rhTSH), 88
- Recurrent parotitis, 227
- Recurrent Sialadenitis, 39
- S**
- Saline instillation, 239
- Saline irrigation, 239
- Salivary calculi, 110
- Salivary disease
- medical management, 115
 - sialendoscopy comparison, 115
 - surgical management, 116
- Salivary duct
- vs. patient with JRP, 228
 - stenting, 66
- Salivary duct papilla, 73
- Salivary duct scar, 71–73, 75–81, 83
- classification, 74, 75
 - diagnostic sialendoscopy, 73
 - ductal anatomy and definitions, 70
 - etiology, 70
 - gland-preserving therapy, 84
 - management
 - combined approach, 79–81
 - conservative management, 75, 76
 - endoscopic approach, 76
 - endoscopic management, 76–79
 - salvage therapy, 83
 - obstructive sialadenitis, 69
 - patient evaluation
 - history and physical examination, 71
 - imaging, 71–73
- Salivary duct stenosis, 19, 25
- Salivary duct stones, 44
- Salivary duct trauma
- avulsion, 97
 - consequences, 99
 - extrinsic trauma, 104
 - gland swelling, 99, 100
 - oncologic trauma, 97, 98
 - pain, 99
 - penetrating trauma, 98
 - perforations, 96
 - prevention, 102, 103
 - risk factors, 94
 - sialocele or fistula, 101
 - sialocele treatment, 105
 - stenosis/stricture, 100
 - Stensen's duct, 93
 - tears and abrasions, 94, 95
 - treatment, 103, 104
 - Wharton's duct, 93
- Salivary endoscopy, 54, 65, 133, 180, 237–239
- anesthesia
 - general, 237
 - local, 237
 - case selection, 234–235
 - case setup, 235–237
 - closure/stenting, 241
 - ductal access
 - identification, cannulation, ducts, 238
 - papillotomy, 238
 - pearls and perils, 239
 - ductal access, 238
 - interventional sialendoscopy, 239–241
 - navigation
 - saline irrigation, 239
 - submandibular duct, 239
 - otolaryngologists, 234
 - posterior edge of masseter muscle, preoperative imaging, 235
 - post-operative course, 241
 - sialadenitis treatment, 233
 - small stones, 234
- Salivary fistula, 67
- Salivary gland disease, 4, 10
- Salivary gland FNA
- benign salivary neoplasms, 35, 36
 - bias, 32
 - cystic lesions, 34
 - diagnostic categories, 33
 - diagnostic considerations, 33
 - inflammatory conditions, 33, 34
 - interpretation error, 32
 - intraparotid lymphadenopathy, 34, 35
 - malignant salivary neoplasms, 36
 - normal salivary tissue, 33
 - sampling error, 32
 - technical problems, 32
- Salivary gland hypofunction, 175
- Salivary gland imaging, 15–20, 22–25
- imaging modalities
 - conventional radiography, 15
 - CT, 17–18
 - MRI, 18
 - salivary gland neoplasms, 20
 - salivary gland scintigraphy, 20
 - sialography, 19–20
 - US, 15–17
 - inflammation and obstruction, 22
 - acute sialadenitis, 22
 - chronic sialadenitis, 24, 25
 - sialolithiasis, 23
 - stenosis, 25
 - lymphoepithelial cysts, 22
 - malignant tumors, 20, 21
 - pleomorphic adenomas, 20
 - Warthin tumors, 20
- Salivary gland inflammatory cycle, 130
- Salivary gland malignancy, 36
- Salivary gland neoplasms, 20
- Salivary gland pathology, 3, 13
- laboratory evaluations, 12
 - systemic illness, 4, 5
- Salivary gland scintigraphy, 20
- Salivary gland-preserving therapy, 251, 252

- Salivary glands, 119–125
 - inflammatory salivary conditions, 119
 - IgG4-related disease, 121–123
 - sarcoidosis, 123
 - Sjögren's syndrome, 119–121
 - surgical management
 - diagnostic biopsy, 123, 124
 - sialendoscopy, 124, 125
- Salivary malignancy, 7
- Salivary myoepithelial cells, 213
- Salivary stenosis/stricture, 100
- Salivary stones, 56–58, 109, 110, 127. *See* Parotid stones
- Salivary swelling, 245
- Salivary systems, anatomy, 234
- Salivary tumors, 16
- Salivary gland FNA, 27
- Salvage therapy, 83–84
- Sarcoidosis, 6, 111, 123, 170
 - diagnosis, 123
 - medical management, 123
- Schaitkin Salivary Duct Cannula, 250
- Schirmer's test, 5
- Schwannoma. *See* Meningioma
- Scintigraphy, 71
- Scopolamine, 188
- Secretomotor signals, 194
- Sedation, 237
- Seldinger technique, 62, 247
- Serologic assays, 128
- Sheath system, 246
- Short-form 8 (SF-8), 256
- Sialadenectomy, 89
- Sialadenitis, 25, 39, 109, 113, 114, 116, 221
 - acute, 22, 33, 109
 - chronic/recurrent, 111
 - imaging
 - CT, 113
 - MR and MR sialography, 114
 - sialography, 113
 - ultrasound, 113
 - obstructive diseases, 110, (*see also* Office-based sialendoscopy)
 - radioiodine (¹³¹I), 88
 - surgical management, 131–132
 - viral causes, 110
- Sialadenosis, 138, 140
 - alcoholism and alcoholic cirrhosis, 139
 - anatomy, 138
 - bulimia, 139
 - chronic swelling, 137
 - CT scan, patient, 140
 - diabetes, 139
 - evaluation, 139
 - painless disorder, 137
 - pathogenesis, 139
 - pathologic analysis, 141–142
 - pathophysiology, 138–139
 - radiology
 - sonography, 140
 - ultrasound of salivary glands, 140 (*see also* Sialosis)
 - surgical management, 142
 - treatment, 142
- Sialagogues, 245
- Sialectasis, 19
- Sialendoscopy, 24, 40, 43, 45, 58, 60, 69, 72, 76, 79, 84, 91, 95, 100, 116, 124, 221, 224, 226, 229, 230, 247, 251
 - indications, 124
 - outcomes, 124, 125
 - procedural approach, 133–134 (*see also* Salivary endoscopy)
 - technique and findings, 124
 - therapeutic procedure, 134
- Sialendoscopyis, 245
- Sialoadenectomy, 58
- Sialocele, 101, 105, 152
- Sialocele/fistula, 101
- Sialodochoplasty, 80, 233
- Sialodochotomy, 63
- Sialography, 19, 20, 24, 60, 113, 141
- Sialolithiasis, 11, 12, 16, 23, 24, 43, 58, 61, 67, 88, 110
 - defined, 57
 - submandibular gland tumors, 11
 - submandibular region, 7
- Sialolithotomy, 53, 235
- Sialoliths, 58
- Sialorrhea
 - bilateral submandibular duct relocation, 189–190
 - bilateral submandibular gland exclusion, B-PDR, 189
 - botulinum toxin, 188–189
 - epidemiology, 186
 - gravidarum, 186
 - involuntary flow, of saliva, 185
 - patient evaluation, 186–187
 - physiotherapy and neuromuscular reeducation, 187
 - radiation therapy, 191
 - surgical interventions, 189
 - systemic pharmacotherapy, 187
 - treatment, 187
- Sialosis, 137
- Simple Luer-lock syringes, 248
- Single gland pathology, 4
- Sjögren's antibody testing, 71
- Sjögren's disease, 71
 - AECG, 177
- Sjögren's International Collaborative Clinical Alliance (SICCA), 120
- Sjögren's syndrome, 5, 6, 13, 18, 20, 24, 34, 45, 46, 58, 83, 111, 119–124, 140, 251
 - diagnosis, 120
 - long-term outcome, 121
 - MALT lymphoma, 121
 - medical treatments, 120
 - pathophysiology, 120
- Small-sized stones, 64
- Sonography, 140
- Squamous cell carcinoma, 34

Staphylococcus aureus, 110, 128
 Stenosis, 67, 70, 71, 75, 111, 116
 Stenson's ducts, 12, 16, 19, 23, 42, 54, 70, 78–82, 93, 111, 138
 Stenson's papilla, 226, 227
 Sternocleidomastoid muscle (SCM), 150, 197
 Stimulated whole saliva (SWS), 178
 Stonebreaker system, 249
 Stonebreaker™, 249
 Storzhand-held drill, 250
 Streptococcus pneumoniae, 128
 Stricture, 70, 111. *see* Stenosis
 Sublingual gland ranula, 8
 Submandibular duct, 234
 Submandibular duct mucocoele, 8
 Submandibular gland diseases, 110, 127, 155, 224
 Submandibular gland tumors, 6, 9–11
 Submandibular hilar megalith, 229
 Submandibular scar, 77
 Submandibular stones, 60, 62–65
 clinical presentation, 58–59
 complications and management, 66
 imaging, 59–60
 operative planning issues, 61, 62
 physical examination, 59
 preoperative issues, 66
 preoperative preparation, 61
 salivary duct stenting, 66
 sialendoscopy
 contraindications, 60
 indications, 60
 surgical approach and techniques, 61, 62
 large hilar submandibular stones, 64, 65
 mouth stones, anterior floor, 63
 small- and intermediate-sized stones, 64
 submandibular papilla, 62
 Superficial parotidectomy (SP), 148
 Surgical biopsy *vs.* FNA, 30
 Sympathetic and parasympathetic nerves, 194
 Sympathetic innervation, parotid gland, 138
 Symptomatic relief, 198

T

T2-weighted MRI, 168
Taenia echinococcosis, 161
 Temporary facial nerve dysfunction, 151
 Temporomandibular joint (TMJ), 208
 Temporomandibular joint disorders (TMDs)
 arthroscopy, 209
 articular disc derangement, 208
 develops depression, in patients, 209
 evaluation, 209
 symptoms, 208
 TMJ, 208
 Temporoparietal flap, 197
 Thermography, 196
 Total parotidectomy (TP), 148
 Towel roll, protect endoscope, 236

Transoral duct, 83
 Transoral robotic surgery (TORS)
 PPS approach, 154
 prestyloid parapharyngeal space tumours, 153
 submandibular gland diseases, 155
 Trigeminal neuralgia
 autonomic symptoms and sensory abnormalities, 205
 chronic facial pain, 203
 cranial nerve distributions, 205
 diagnosis, 205
 herpes zoster, 205
 non-ablative approach, 206
 patients, with multiple sclerosis, 205
 surgical techniques, 206
 True cysts, 159

U

Ulcer, right parotid gland, 169
 Ultrasonography (US), 15–17, 40, 59, 65, 72, 113, 120, 121, 160, 188
 left parotid hemangioma, 166
 masseter RFA, 168
 moth-eaten parotid gland, 129
 parotid stones, 52
 pleomorphic adenoma, 20
 surgeon-performed, 29
 Ultrasound-guided FNA (USGFNA), 29
 Unstimulated whole saliva (UWS), 178
 Uveoparotid fever, 123

V

Vascular malformations, 164–165
 Venous malformation (VM)
 percutaneous sclerotherapy, 167
 phleboliths and thrombus formation, 167
 vascular malformations, 166
 Viral parotitis, 127, 128
 Viral sialadenitis, 116
 acute inflammation, 22
 Visual analog scale (VAS), 253

W

Walvekar Salivary Stent, 66, 250
 Warthin's tumor, 20, 35, 148, 246
 Wharton's ducts, 11, 16, 19, 23, 42, 47, 59, 62, 63, 65, 67, 70, 78, 79, 93, 94, 101, 110, 111, 238
 Wharton's papilla, dilation of, 238
 White avascular, ductal layer, 132

X

Xerostomia, 5, 9, 13, 71, 89, 139, 176, 177, 179–181
 diagnosis, history, 178
 diagnostic tests, 178–179
 endoscopic appearance, 180
 epidemiology, 176

- etiology
 - infection, 177
 - systemic disease, 177
 - treatment side effects, 176
- medical conditions, 176
- physical exam, 178
- subjective sensation, of dry mouth, 175
- treatment
 - interventions, 180–181
 - saliva stimulants, 179
 - salivary substitutes, 179
- Xerostomia questionnaire (XQ), 178